

Therapeutic Efficacy of Chrysoeriol on Doxorubicin-induced Liver Damage by Improving Biochemical and Histological Profile in Rats

Muhammad Umar Ijaz^{1*}, Tahreem Fatima¹, Moazama Batool², Rabia Azmat¹, Ambreen Sadaf¹, Namra Ghafoor¹, Mehrab Khalil¹

¹Department of Zoology, Wildlife and Fisheries, University of Agriculture, Faisalabad, Pakistan

²Department of Zoology, Govt. College Women University, Sialkot, Pakistan

*Corresponding author: umar.ijaz@uaf.edu.pk

Received November 21, 2022; Revised January 02, 2023; Accepted January 10, 2023

Abstract Doxorubicin (DOX) is a commonly prescribed, potent anti-cancer drug, however, its clinical administration is restricted due to its serious organotoxic potential especially hepatotoxicity. Chrysoeriol (CSR) is a natural flavonoid, which exhibits putative antioxidant and free-radical scavenging activities. This research was planned to assess the hepatoprotective potential of CSR against DOX-prompted hepatic damage in male albino rats. 48 rats were segregated into four groups viz. Control, DOX-treated group (3 mgkg⁻¹), DOX + CSR-treated group (3 mgkg⁻¹ + 20 mgkg⁻¹) and CSR-treated group (20 mgkg⁻¹). DOX treatment induced liver toxicity as indicated by the significant elevation in the serum levels of alanine aminotransferase (ALT) alkaline phosphatase (ALP), and aspartate aminotransferase (AST). Additionally, DOX exposure disrupted the biochemical profile by decreasing the activities of antioxidant enzymes i.e., catalase (CAT), superoxide dismutase (SOD), glutathione peroxidase (GPx), glutathione (GSH), glutathione reductase (GSR) and glutathione S-transferase (GST), while raised the levels of ROS and MDA. Furthermore, inflammatory markers level such as nuclear factor kappa B (NF-κB), tumor necrosis factor alpha (TNF-α), interleukin-1 beta (IL-1β), interleukin-6 (IL-6) as well as Cyclooxygenase-2 (COX-2) activity were also increased. Besides the level of pro-apoptotic markers i.e., Bax, Caspase-3 and Caspase-9 were raised, while the level of anti-apoptotic protein, Bcl-2 was reduced following the DOX intoxication. In DOX-treated rats, Histopathological observation indicated substantial hepatic tissue damage. However co-treatment with chrysoeriol remarkably reversed all the aforementioned hepatic damages. CSR demonstrated promising hepatoprotective potential through exerting antioxidant, anti-inflammatory and anti-apoptotic properties.

Keywords: doxorubicin, chrysoeriol, liver toxicity, inflammation, antioxidants

Cite This Article: Muhammad Umar Ijaz, Tahreem Fatima, Moazama Batool, Rabia Azmat, Ambreen Sadaf, Namra Ghafoor, and Mehrab Khalil, "Therapeutic Efficacy of Chrysoeriol on Doxorubicin-induced Liver Damage by Improving Biochemical and Histological Profile in Rats." *Journal of Food and Nutrition Research*, vol. 11, no. 1 (2023): 57-62. doi: 10.12691/jfnr-11-1-6.

1. Introduction

Cancer is considered one of the worst ailments, with an inexorable death rate among the global population [1]. Doxorubicin (DOX) is considered one of the most effective, commonly used chemotherapeutic agents which are used to treat broad range of cancer malignancies [2] for instance, hematological, lymphocytic/non-lymphocytic leukemia, Wilm tumor, neuroblastoma, and sarcomas. Despite its broad clinical use, doxorubicin adverse effects are of serious concern. However, its prolonged clinical administration is limited owing to its various systemic side effects including hepatotoxicity [3], pulmototoxicity [4] and nephrotoxicity [5]. One of the major adverse effects of DOX is liver damage, which is commonly observed in patients using this chemotherapy drug [6]. A key

metabolic organ, the liver has been studied to be the most susceptible organ to DOX-induced oxidative stress and damage. In cancer patients, DOX therapy can result in varying degrees of liver impairment [7].

It is not possible to reverse some toxicities prompted by DOX, such as hepatotoxicity. Hepatotoxicity has been reported in about 40% of DOX-treated patients [8]. DOX is converted by cytoplasmic reductases and liver microsomal enzymes into doxorubicinol and other hepatotoxic aglycone metabolites, resulting in the buildup of toxic and immunogenic intermediates that have been linked to liver damage [9]. High level of ROS and free radical formation may cause hepatotoxicity. The lipids of liver epithelial cell membrane are susceptible to DOX generated free radical damage that results in lipid peroxidation [3] leading structural and functional alterations in hepatic tissues [11]. Several DOX-prompted histopathological damages have also been observed in

liver tissues such as cellular edema, focal necrosis, parenchymal necrosis, bile duct hyperplasia, lymphocyte infiltration, and vacuolation of hepatocytes [12]. Therefore, development of reliable chemo-protective drugs against adverse effects of DOX is of utmost importance.

In recent years, plant-derived phyto-constituents are gaining popularity owing to their possible therapeutic effects against various diseases [10,11]. Therefore, research is being conducted on natural or synthetic antioxidant compounds to mitigate the possible ailments [12,13]. Chrysoeriol (CSR), 5,7-dihydroxy-2-(4-hydroxy-3-methoxyphenyl)-4H chromen-4-one, is a flavonoid, which is present in the aerial parts of *Artemisia copa*, and leaves of *Digitalis purpurea* [14]. Chrysoeriol exhibits diverse pharmacological properties including, anti-inflammatory [15], cardioprotective [16], antiapoptotic [17] and antioxidant properties [18]. However, there are no reports regarding the hepatoprotective effect of CSR. Based on the considerable bioactive properties of CSR, the aim of this study was to determine the potential ameliorative effects of CSR against DOX-provoked liver impairment.

2. Materials and Methods

2.1. Chemicals

Doxorubicin and chrysoeriol were procured from Sigma-Aldrich (St. Louis, MO).

2.2. Animals

To conduct the experiment, 48 male albino rats (180-220g), approximately 8-10 weeks old, were maintained in the Animal House at the University of Agriculture, Faisalabad (UAF). Optimal conditions of $24\pm 1^{\circ}\text{C}$ temperature, $45\pm 5\%$ humidity, and a 12-hour light-dark cycle were sustained. Ad libitum water and standard food were provided. Prior to experiment rats were acclimatized for 1 week with laboratory environment. The UAF Department Ethical Board approved study protocols (CEE Council 86/609) for this experiment.

2.3. Experimental Design

In the experiment, 48 albino rats were randomly split into four groups ($n=12/\text{group}$) as control, DOX, DOX+CSR, and CSR. The 1st group was considered as control group and was only treated with tap water and animal feed, the 2nd group was intoxicated with DOX ($3\text{ mgkg}^{-1}\text{ BW}$), the 3rd group was co-treated with DOX (3 mgkg^{-1}) and chrysoeriol (20 mgkg^{-1}) and the 4th group was treated with CSR (20 mgkg^{-1}) via oral gavage. After 30 days trial, rats were anaesthetized with ketamine, heparinized syringes were used to collect blood and the liver was extracted for structural and biochemical analysis. The blood was centrifuged at 3000 rpm for 20 minutes and kept at -30°C for further analysis.

2.4. Assessment of Liver Function Markers

The liver function markers (AST, ALT, and ALP) were measured using ELISA kits (Abcam, MA, USA). All the

protocols were carried out as per the manufacturer's guidelines.

2.5. Assessment of Antioxidant Enzymes and Oxidative Stress Markers

An evaluation of CAT activity was conducted using a technique described by Aebi [19]. A method for analyzing SOD activity was developed by Kakkar et al. [20]. The Rotruck et al., procedure was followed to measure the GPx activity [21]. Using a technique previously developed by Jollow et al. [22], the GSH content was determined. GSR activity was evaluated as per the procedure described by Carlberg and Mannervik [23], and GST activity was estimated using Habig et al. [24] method. The MDA level was estimated with the Ohkawa et al. [25] method. The ROS concentration was assessed using the procedure stated by Hayashi et al. [26].

2.6. Assessment of Inflammatory Markers

The levels of NF-Kb, TNF- α , IL-1 β , IL-6, along with COX-2 activity were analyzed employing ELISA (Cusabio Technology Llc, Houston, TX, USA) kits as per the manufacturer's guidelines.

2.7. Assessment of Apoptotic Markers

The levels of Bax, Bcl-2, caspase-3 and caspase-9 were measured using ELISA kits (Cusabio Technology Llc, Houston, TX, USA) following the instructor's directions.

2.8. Histopathological Analysis

After fixation in 10% formaldehyde solution for 12 hours, liver tissues were dehydrated in ascending concentrations of alcohol (80%, 90%, and 100%) before being embedded in paraffin. Using a rotator microtome, specimens were finely cut into $4\mu\text{m}$ thick slices and histopathological alterations were determined using hematoxylin-eosin staining. Motic TM 5.0 megapixel camera was used to capture photographs while the slides were being viewed under a microscope (Leica DM4000B; Leica Microsystems GmbH).

2.9. Statistical Analysis

Obtained data was expressed as mean \pm SE. For comparative estimation between groups, one-way analysis (ANOVA), followed by Tukey's test was applied. A significance level of $p < 0.05$ was set.

3. Results

3.1. DOX and CSR Effects on Hepatic Serum Enzymes

Hepatic serum markers were evaluated to check hepatotoxicity. DOX administration substantially ($p < 0.05$) elevated the serum levels of AST, ALT and ALP in contrast with control group. However, CSR administration substantially ($p < 0.05$) lowered the hepatic serum enzymes levels versus DOX group. Additionally, the only

CSR treated group showed no significant difference in hepatic serum enzyme level versus control group.

3.2. DOX and CSR Effects on Antioxidant Profile

DOX intoxication considerably ($p < 0.05$) decreased the antioxidant activities (CAT, SOD, GPx, GSR, GSH and GST), while exponentially escalating the MDA and ROS levels in DOX-treated group in contrast to control. However, CSR administration with DOX noticeably ($p < 0.05$) lowered the levels of ROS and MDA while substantially ($p < 0.05$) elevated the CAT, SOD, GST, GPx, GSH and GSR activities in contrast with DOX-treated group. The mean value of only CSR and control group was quite close to each other.

3.3. DOX and CSR Effects on Inflammatory Markers

DOX exposure considerably ($p < 0.05$) elevated the levels of inflammatory markers such as NF- κ B, TNF- α , IL-1 β , IL-6 and COX-2 activity in DOX group in comparison with control group. However, CSR co-treatment considerably ($p < 0.05$) lowered the inflammatory marker level in contrast with DOX-intoxicated group. Moreover, the only CSR group showed no discernible difference from the control group.

3.4. DOX and CSR Effects on Apoptotic Markers

DOX substantially ($p < 0.05$) increased the level of apoptotic markers (Bax, caspase-3 and caspase-9) while decreased the Bcl-2 level in DOX-treated group in contrast to control. Contrarily, CSR administration notably ($p < 0.05$) lowered the apoptotic marker levels (Bax, caspase-3 and caspase-9) while up-regulated the level of Bcl-2 in DOX+CSR group versus DOX-intoxicated group. However, only CSR-treated groups had similar means as control group.

3.5. DOX and CSR Effects on Hepatic Histopathology

DOX exposure substantially ($p < 0.05$) increased the central venule disruption, necrosis, sinusoids dilation and cell death in DOX-intoxicated group as compared to the control group. However, CSR and DOX co-administration mitigated the intensity of histopathological alterations such reduced sinusoid dilation with no central venule disruption necrotic cell and restored the hepatocyte structure compared to DOX treated group. However, structure of hepatic tissues of only CSR treated group was quite similar to control group.

Table 1. Effects of CSR and DOX on antioxidant enzymes in hepatic tissues of rats

Groups	CAT (U/mg protein)	SOD (U/mg protein)	GPx (U/mg protein)	GSH (μ M/g tissue)	GSR (nM NADPH oxidized/min/mg tissue)	GST (nM/min/mg protein)
Control	10.24 \pm 0.40 ^a	8.10 \pm 0.25 ^a	18.61 \pm 0.59 ^a	15.72 \pm 0.56 ^a	5.46 \pm 0.16 ^a	27.82 \pm 1.15 ^a
DOX	3.74 \pm 0.13 ^c	2.93 \pm 0.12 ^c	4.79 \pm 0.30 ^c	6.17 \pm 0.47 ^c	1.65 \pm 0.13 ^c	11.73 \pm 0.67 ^c
DOX+CSR	8.24 \pm 0.26 ^b	5.68 \pm 0.16 ^b	13.99 \pm 0.97 ^b	11.71 \pm 0.29 ^b	3.52 \pm 0.10 ^b	22.42 \pm 0.54 ^b
CSR	10.34 \pm 0.37 ^a	8.18 \pm 0.27 ^a	18.86 \pm 0.60 ^a	15.93 \pm 0.60 ^a	5.54 \pm 0.16 ^a	28.20 \pm 1.41 ^a

The readings of a column with distinct superscripts differ substantially ($p < 0.05$) from others.

Table 2. Effects of CSR and DOX on oxidative stress markers of rat's hepatic tissues

Groups	MDA (nmol g^{-1})	ROS (μ mol g^{-1})
Control	0.64 \pm 0.05 ^c	1.73 \pm 0.07 ^c
DOX	3.72 \pm 0.31 ^a	7.68 \pm 0.26 ^a
DOX+CSR	1.95 \pm 0.11 ^b	2.89 \pm 0.17 ^b
CSR	0.61 \pm 0.06 ^c	1.67 \pm 0.07 ^c

The readings of a column with distinct superscripts differ substantially ($p < 0.05$) from others.

Table 3. Effects of CSR and DOX on inflammatory markers in hepatic tissues of rats

Groups	NF- κ B (ng/g tissues)	TNF- α (ng/g tissues)	IL-1 β (ng/g tissues)	IL-6 (ng/g tissues)	COX-2 (ng/g tissue)
Control	11.53 \pm 0.04 ^c	4.84 \pm 0.19 ^c	20.03 \pm 1.25 ^c	8.58 \pm 0.12 ^c	19.28 \pm 0.27 ^c
DOX	69.75 \pm 1.52 ^a	18.64 \pm 0.19 ^a	90.88 \pm 1.71 ^a	35.57 \pm 1.08 ^a	77.50 \pm 0.08 ^a
DOX+CSR	25.06 \pm 0.90 ^b	8.75 \pm 0.02 ^b	36.18 \pm 1.47 ^b	18.21 \pm 0.47 ^b	28.89 \pm 1.32 ^b
CSR	11.43 \pm 0.10 ^c	4.80 \pm 0.19 ^c	19.63 \pm 1.22 ^c	8.52 \pm 0.11 ^c	19.17 \pm 0.32 ^c

The readings of a column with distinct superscripts differ substantially ($p < 0.05$) from others.

Table 4. Effects of CSR and DOX on apoptotic markers in hepatic tissues of rats

Groups	Bax (pg/mL)	Bcl-2 (ng/mL)	Caspase-9 (pg/mL)	Caspase-3 (pg/mL)
Control	3.18 \pm 0.27 ^c	17.07 \pm 0.48 ^a	3.94 \pm 0.11 ^c	1.77 \pm 0.04 ^c
DOX	9.49 \pm 0.39 ^a	3.91 \pm 0.15 ^c	15.00 \pm 0.45 ^a	8.57 \pm 0.29 ^a
DOX+CSR	4.76 \pm 0.25 ^b	13.67 \pm 0.57 ^b	5.92 \pm 0.51 ^b	4.06 \pm 0.17 ^b
CSR	3.14 \pm 0.27 ^c	17.87 \pm 0.54 ^a	3.89 \pm 0.11 ^c	1.73 \pm 0.05 ^c

The readings of a column with distinct superscripts differ substantially ($p < 0.05$) from others.

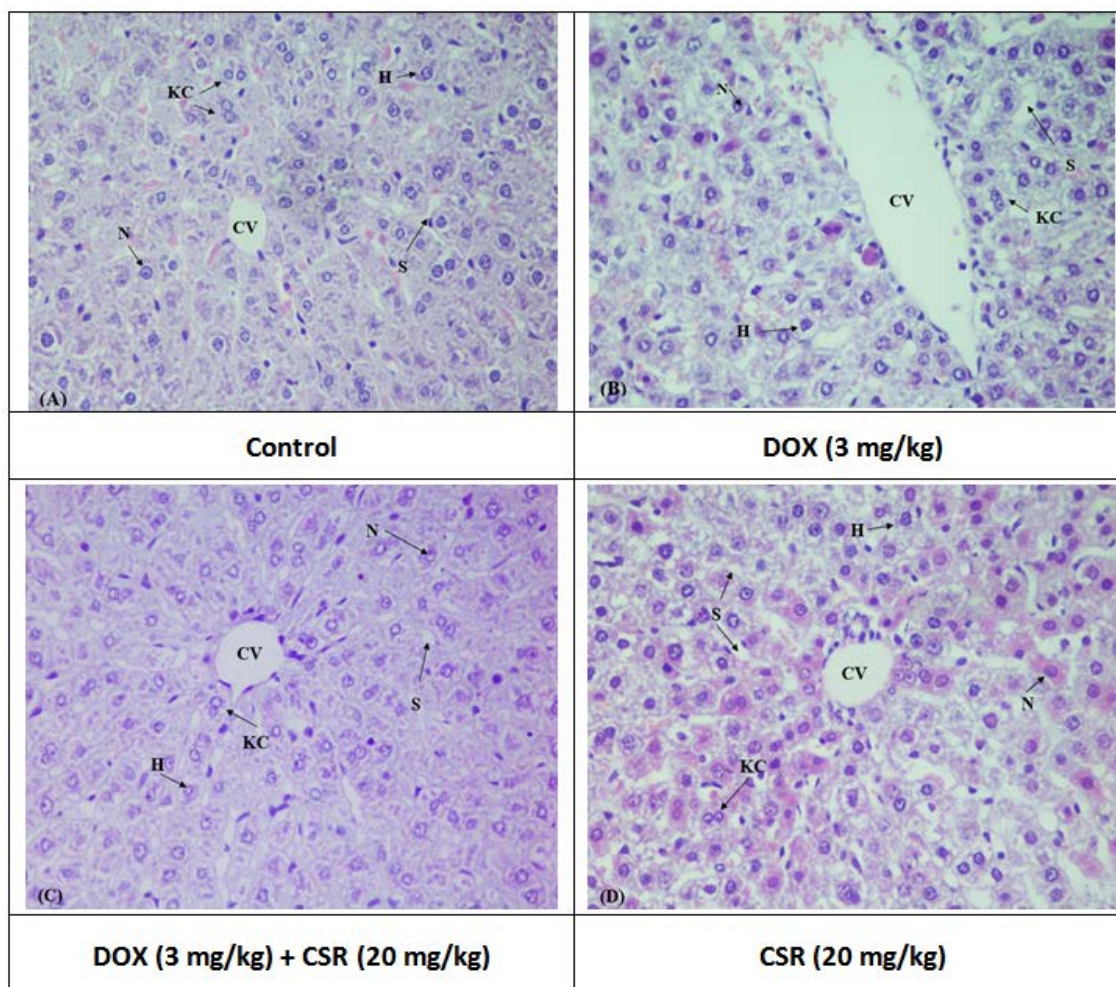


Figure 1. Hepatoprotective effects of CSR on DOX-induced alterations in liver histology. A) Control group B) DOX group (3 mg/kg BW) C) DOX (3 mg/kg BW) + CSR (20 mg/kg BW) group D) CSR group (20 mg/kg BW)

4. Discussion

DOX is the leading anticancer drug, that is being used to treat multiple neoplasms, but its clinical administration is limited due to its exacerbated risk of hepatotoxicity [2]. Several studies have reported that DOX exposure instigates oxidative stress and induce cardio-toxicity [16,27]. The mechanism by which DOX causes hepatotoxicity has not been fully understood. In the current investigation we determined DOX-induced hepatotoxicity by assessing biochemical profile, inflammatory marker level, expression of apoptotic enzymes along with histopathological examination of liver tissues. CSR is a phytochemical flavonoid that exhibit promising pharmacological properties. Therefore, this research was designed for the evaluation of ameliorative effect of CSR against DOX-induced liver toxicity.

DOX intoxication adversely affects the liver as indicated by elevated level of AST, ALT, and ALP. High level of these biomarkers is associated with increased damage of hepatocyte membrane permeability and cellular leakage [2], suggesting that DOX may impair the integrity of plasma membrane. Nagai et al., also reported that DOX intoxication increased serum AST, ALT, and ALP levels contributing to liver toxicity [28]. However, CSR supplementation showed potential therapeutic effects against DOX-induced histopathological changes by lowering the AST, ALT, and

ALP level. The results of this research suggested that CSR showed protective effect against DOX-prompted liver damage.

Our results indicate that DOX exposure may potentially disrupt the anti-oxidative defense system by reducing antioxidant enzymes activities (CAT, SOD, GPx, GST, GSH and GSR), whereas a substantial upsurge in the levels of MDA level and ROS were observed. SOD enzyme catalyzes the superoxide anion (O_2^-) and produce hydrogen peroxide (H_2O_2), preventing the toxic hydroxyl ion generation. Another essential antioxidant enzyme CAT converts reactive H_2O_2 into H_2O [29]. GSH, which is a cofactor of GPx, protects the cell from OS by lowering the H_2O_2 level [30,31]. GSR transforms glutathione disulfide into GSH that protects cells against OS by lowering peroxide and hydrogen peroxide level [32]. The body's oxidant-antioxidant balance is disturbed by the excessive ROS generation caused by the antioxidant enzyme's reduced activity [33], which causes OS and lipid peroxidation as evidenced by an increased MDA level [34,35]. However, CSR supplementation showed a significant elevation in the antioxidant enzyme activities as well as reduction in ROS concentration and MDA level due to its antioxidant potential.

To determine the effects of DOX and CSR on the inflammatory indices in hepatic tissues, the levels of inflammatory markers were evaluated. DOX treatment elevated inflammatory marker level (NF- κ B, TNF- α , IL-

1 β , IL-6 and COX-2 activity) in liver tissues. NF- κ B activation induces inflammatory reactions after sensing any internal and external cellular stimulation via mediating pro-inflammatory biomarkers such as TNF- α , IL-1 β , and IL-6 that are all linked with acute inflammation [36,37]. COX-2, an inductive form of COX, is an inflammatory marker that plays an important part in the inflammatory mechanism [38,39]. Our results revealed that DOX exposure caused inflammation in hepatocytes by increasing the levels of inflammatory markers. However, CSR supplementation significantly lowered the level of inflammatory biomarkers compared to the DOX group owing to its anti-inflammatory property.

DOX administration along with therapeutic effects of CSR in hepatic tissues was assessed by evaluation of apoptotic markers levels. Pro-apoptotic protein, Bax and anti-apoptotic protein Bcl-2 induce intrinsic apoptotic pathway [40]. The activation of Bax and suppression of Bcl-2, initiates apoptosis through mitochondrial signaling that triggers the activation of cytochrome-c. Cytochrome-c, the apoptosis promoting factor released from mitochondrial intermembrane spaces into cytoplasm resulting in caspase-9 activation [40]. The caspase-9 triggers caspase-3 activation that ultimately results in apoptosis [41]. The results of our research demonstrated that DOX exposure elevated Bax, caspase-3 and caspase-9 levels along with reduction in Bcl-2 level. However, CSR administration mitigated the hepatic apoptosis by down-regulating the pro-apoptotic biomarkers i.e., Bax, caspase-3 and caspase-9 levels and elevating Bcl-2 level due to its anti-apoptotic potential.

DOX administration provoked various histopathological alterations in hepatic tissues. DOX-induced histological alteration in liver tissues by disrupting the oxidant-antioxidant balance and lipid peroxidation [42]. DOX exposure induced various histopathological alterations like swelling in connective and supporting tissues, infiltration and vacuolization of inflammatory cells, necrosis, and disruption in hepatic parenchyma. However, CSR administration mitigated the DOX-induced histopathological damages. Therefore, histoprotective effect of CSR might be due to its anti-oxidant, anti-inflammatory and anti-apoptotic properties.

5. Conclusion

Taken together, our findings suggest that CSR exhibits remarkable ameliorative potential against DOX-prompted hepatic damage. CSR administration considerably restored the level of hepatic serum markers, apoptotic markers, inflammatory biomarkers, antioxidant enzyme activities and histological abnormalities. This hepatoprotective potential of CSR might be ascribed to its anti-oxidant, anti-inflammatory and anti-apoptotic properties. Our findings indicated that CSR could be considered as a potential curative agent for clinical usage and prevention for DOX-induced hepatic injury.

References

- [1] Rivankar, S. (2014). An overview of doxorubicin formulations in cancer therapy. *Journal of cancer research and therapeutics*, 10: 853.
- [2] Sirwi, A., Shaik, R. A., Alamoudi, A. J., Eid, B. G., Kammoun, A. K., Ibrahim, S. R. M., Mohamed, G. A., Abdallah, H. M., & Abdel-Naim, A. B. (2021). Mokko Lactone Attenuates Doxorubicin-Induced Hepatotoxicity in Rats: Emphasis on Sirt1/FOXO1/NF- κ B Axis. *Nutrients* 13: 4142.
- [3] Barakat, B. M., Ahmed, H. I., Bahr, H. I., & Elbahaie, A. M. (2018). Protective effect of boswellic acids against doxorubicin-induced hepatotoxicity: impact on Nrf2/HO-1 defense pathway. *Oxidative Medicine and Cellular Longevity*, 2018.
- [4] Guzel, E. E., & Tektemur, N. K. (2021). Hesperetin may alleviate the development of doxorubicin-induced pulmonary toxicity by decreasing oxidative stress and apoptosis in male rats. *Tissue and Cell* 73: 101667.
- [5] Qi, W., Boliang, W., Xiaoxi, T., Guoqiang, F., Jianbo, X., & Gang, W. (2020). Cardamonin protects against doxorubicin-induced cardiotoxicity in mice by restraining oxidative stress and inflammation associated with Nrf2 signaling. *Biomedicine & Pharmacotherapy* 122: 109547.
- [6] Hozayen, W. G., Seif, H. S. A., & Amin, S. (2014). Protective effects of Ruitn and/or hesperidin against doxorubicin-induced hepatotoxicity. *International Journal of Clinical Nutrition*, 2: 11-17.
- [7] Mansouri, E.; Jangaran, A.; Ashtari, A. Protective effect of pravastatin on doxorubicin-induced hepatotoxicity. *Bratisl. Lek. Listy* 2017, 118, 273-277
- [8] Damodar, G., Smitha, T., Gopinath, S., Vijayakumar, S., & Rao, Y. A. (2014). An evaluation of hepatotoxicity in breast cancer patients receiving injection Doxorubicin. *Annals of Medical and Health Sciences Research* 4: 74-79.
- [9] Jacevic, V., Djordjevic, A., Srdjenovic, B., Milic-Tores, V., Segrt, Z., Dragojevic-Simic, V., & Kuca, K. (2017). Fullerol nanoparticles prevents doxorubicin-induced acute hepatotoxicity in rats. *Experimental and Molecular Pathology* 102: 360-369.
- [10] Mansouri, E., Jangaran, A., & Ashtari, A. (2017). Protective effect of pravastatin on doxorubicin-induced hepatotoxicity. *Bratislavské Lekárske Listy* 118: 273-277.
- [11] Song, S., Chu, L., Liang, H., Chen, J., Liang, J., Huang, Z., Zhang, B., & Chen, X. (2019). Protective effects of dioscin against doxorubicin-induced hepatotoxicity via regulation of Sirt1/FOXO1/NF- κ B signal. *Frontiers in Pharmacology* 10: 1030.
- [12] Butt, M. S., & Sultan, M. T. (2009). Green tea: nature's defense against malignancies. *Critical Reviews in Food Science and Nutrition* 49: 463-473.
- [13] Siró, I., Kápolna, E., Kápolna, B., & Lugasi, A. (2008). Functional food. Product development, marketing and consumer acceptance—A review. *Appetite* 51: 456-467.
- [14] Oh, S.-Y., & Hyun, C.-G. (2022). Chrysoeriol Enhances Melanogenesis in B16F10 Cells Through the Modulation of the MAPK, AKT, PKA, and Wnt/ β -Catenin Signaling Pathways. *Natural Product Communications* 17: 1934578X211069204.
- [15] Wu, J.-Y., Chen, Y.-J., Bai, L., Liu, Y.-X., Fu, X.-Q., Zhu, P.-L., Li, J.-K., Chou, J.-Y., Yin, C.-L., & Wang, Y.-P. (2020). Chrysoeriol ameliorates TPA-induced acute skin inflammation in mice and inhibits NF- κ B and STAT3 pathways. *Phytomedicine* 68: 153173.
- [16] Zhe, L., SONG, X., Ying, X., WANG, X., Hui, Y., BAI, Y., LIU, J., ZHANG, C., & HUI, R. (2009). Protective effect of chrysoeriol against doxorubicin-induced cardiotoxicity in vitro. *Chinese Medical Journal* 122: 2652-2656.
- [17] Limboonreung, T., Tuchinda, P., & Chongthammakun, S. (2020). Chrysoeriol mediates mitochondrial protection via PI3K/Akt pathway in MPP+ treated SH-SY5Y cells. *Neuroscience Letters* 714: 134545.
- [18] Kim, M. H., Kwon, S. Y., Woo, S.-Y., Seo, W. D., & Kim, D. Y. (2021). Antioxidative effects of chrysoeriol via activation of the Nrf2 signaling pathway and modulation of mitochondrial function. *Molecules* 26: 313.
- [19] Aebi, H. (1974). Catalase. In *Methods of enzymatic analysis*. Academic press 673-684.
- [20] Kakkar, P., Das, B., & Viswanathan, P. N. (1984). A modified spectrophotometric assay of superoxide dismutase.
- [21] Rotruck, J. T., Pope, A. L., Ganther, H. E., Swanson, A. B., Hafeman, D. G., & Hoekstra, W. (1973). Selenium: biochemical role as a component of glutathione peroxidase. *Science* 179: 588-590.
- [22] Jollow, D. J., Mitchell, J. R., Zampaglione, N., & Gillette, J. R. (1974). Bromobenzene-induced liver necrosis. Protective role of

- glutathione and evidence for 3, 4-bromobenzene oxide as the hepatotoxic metabolite. *Pharmacology* 11: 151-169.
- [23] Carlberg, I., & Mannervik, B. (1975). Purification of the flavoenzyme glutathione reductase from rat liver. *J Biol Chem* 250: 5475-5480.
- [24] Habig, W. H., Pabst, M. J., & Jakoby, W. B. (1974). Glutathione S-transferases: the first enzymatic step in mercapturic acid formation. *Journal of Biological Chemistry* 249: 7130-7139.
- [25] Ohkawa, H., Ohishi, N., & Yagi, K. (1979). Assay for lipid peroxides in animal tissues by thiobarbituric acid reaction. *Analytical Biochemistry* 95: 351-358.
- [26] Hayashi, I., Morishita, Y., Imai, K., Nakamura, M., Nakachi, K., & Hayashi, T., 2007. High-throughput spectrophotometric assay of reactive oxygen species in serum. *Mutation Research/Genetic Toxicology and Environmental Mutagenesis*, 631: 55-61.
- [27] Ijaz, M. U., Aziz, S., Faheem, M., Abbas, K., Nasir, S., Naz, H., & Imran, M. (2021). Orientin Attenuates Cisplatin-Induced Renal Toxicity by Reducing Oxidative Stress and Inflammation. *Pakistan Veterinary Journal* 41: 574-578.
- [28] Nagai, K., Fukuno, S., Oda, A., & Konishi, H. (2016). Protective effects of taurine on doxorubicin-induced acute hepatotoxicity through suppression of oxidative stress and apoptotic responses. *Anti-Cancer Drugs* 27: 17-23.
- [29] Deponte, M. (2013). Glutathione catalysis and the reaction mechanisms of glutathione-dependent enzymes. *Biochimica et Biophysica Acta (BBA)-General Subjects*, 1830(5), 3217-3266.
- [30] Wang, R., Wang, J., Song, F., Li, S., & Yuan, Y. (2018). Tanshinol ameliorates CCl₄-induced liver fibrosis in rats through the regulation of Nrf2/HO-1 and NF-κB/IκBα signaling pathway. *Drug Design, Development and Therapy* 12: 1281.
- [31] Ara, C., Arshad, A., Faheem, M., Khan, M., & Shakir, H. A. (2022). Protective Potential of Aqueous Extract of *Allium cepa* against Tartrazine Induced Reproductive Toxicity. *Pakistan Veterinary Journal* 42: 358-363.
- [32] Widowati, W., Prahastuti, S., Hidayat, M., Hasiana, S.T., Wahyudiningsih, R., Afifah, E., Kusuma, H.S.W., Rizal, R. and Subangkit, M., 2022. Protective Effect of Ethanolic Extract of Jati Belanda (*Guazuma ulmifolia L.*) by Inhibiting Oxidative Stress and Inflammatory Processes in Cisplatin-induced Nephrotoxicity in Rats. *Pakistan Veterinary Journal* 42: 376-382.
- [33] Elsayed, A., Elkomy, A., Alkafafy, M., Elkammar, R., Fadl, S.E., Abdelhieb, E.Y., Abdeen, A., Youssef, G., Shaheen, H., Soliman, A., & Aboubakr, M. 2021. Ameliorating Effect of Lycopene and N-Acetylcysteine against Cisplatin-Induced Cardiac Injury in Rats. *Pakistan Veterinary Journal* 42: 107-111.
- [34] Forman, H. J., & Zhang, H. (2021). Targeting oxidative stress in disease: Promise and limitations of antioxidant therapy. *Nature Reviews Drug Discovery* 20: 689-709.
- [35] Ishtiaq, A., Ijaz, M. U., Ehsan, N., Imran, M., Naz, H., Alvi, K., & Zhu, G. (2022). Therapeutic Effect of Oroxylin A Against Bisphenol A-induced Kidney Damage in Rats: a Histological and Biochemical Study. *Pakistan Veterinary Journal* 42: 511-516.
- [36] Vyas, D., Laput, G., & Vyas, A. K. (2014). Chemotherapy-enhanced inflammation may lead to the failure of therapy and metastasis. *OncoTargets and Therapy* 7: 1015.
- [37] Somade, O. T., Ajayi, B. O., Safiriyu, O. A., Oyabunmi, O. S., & Akamo, A. J. (2019). Renal and testicular up-regulation of pro-inflammatory chemokines (RANTES and CCL2) and cytokines (TNF-α, IL-1β, IL-6) following acute edible camphor administration is through activation of NF-κB in rats. *Toxicology Reports* 6: 759-767.
- [38] Abd El-Dayem, S. M., Fouda, F., Helal, M., & Zaaaza, A. (2010). The role of Catechin against doxorubicin-induced cardiotoxicity in Ehrlich ascites carcinoma cells (EAC) bearing mice. *American Journal of Science* 6: 146-152.
- [39] Ijaz, M. U., Ishtiaq, A., Ehsan, N., Imran, M., & Zhu, G. P. (2022). Hepatoprotective Potential of Genkwain Against Aflatoxin B₁-Induced Biochemical, Inflammatory and Histopathological Toxicity in Rats. *Pakistan Veterinary Journal* 42: 499-504.
- [40] Santana, T. (2018). Apoptosis and cell cycle aberrations in epithelial odontogenic lesions: evidence by the expression of p53, Bcl-2 and Bax. *Medicina Oral, Patología Oral y Cirugía Bucal*, 23: 1.
- [41] Végran, F., Boidot, R., Solary, E., & Lizard-Nacol, S. (2011). A short caspase-3 isoform inhibits chemotherapy-induced apoptosis by blocking apoptosome assembly. *PLoS One* 6: e29058.
- [42] Wali, A. F., Rashid, S., Rashid, S. M., Ansari, M. A., Khan, M. R., Haq, N., Alhareth, D. Y., Ahmad, A., & Rehman, M. U. (2020). Naringenin regulates doxorubicin-induced liver dysfunction: impact on oxidative stress and inflammation. *Plants* 9: 550.

