

Necrotizing Skin and Soft Tissue Infection due to Mycobacteria Wolinskyi Following Abdominoplasty

Eman EL-Sawalhy^{1*}, Wehbi Hnayni¹, Abir Tawil², Hanady Daas³

¹Department of Internal Medicine, Beaumont Hospital, Dearborn, MI

²Department of Pathology, Beaumont Hospital, Dearborn, MI

³Division of Infectious Disease, Department of Internal Medicine Beaumont Hospital, Dearborn, MI

*Corresponding author: Eman.elsawalhy@beaumont.org

Received January 03, 2021; Revised January 08, 2021; Accepted January 27, 2021

Abstract Mycobacteria Wolinskyi is a rapidly growing nontuberculous mycobacterium (RGM) that is associated with skin and soft tissue infection (SSTI) following cosmetic surgeries. The infections vary in severity and treatment requires a prolonged course of antibiotics as well as surgical intervention. Around 20 cases have been reported worldwide, only a handful in the United States. In this case report, we present a case of a 30-year-old woman with severe necrotizing infection due to *M. Wolinskyi* following abdominoplasty abroad.

Keywords: *M. Wolinskyi*, Cosmetic surgeries, necrotizing tissue infections

Cite This Article: Eman EL-Sawalhy, Wehbi Hnayni, Abir Tawil, and Hanady Daas, "Necrotizing Skin and Soft Tissue Infection due to Mycobacteria Wolinskyi Following Abdominoplasty." *American Journal of Medical Case Reports*, vol. 9, no. 4 (2021): 226-228. doi: 10.12691/ajmcr-9-4-5.

1. Introduction

Nontuberculous mycobacteria include more than 140 species that are highly distributed in the environment primarily on soil and water. *M. Wolinskyi* belongs to the *M. Smegmatis* group (*M. Smegmatis*, *M. Wolinskyi*, *M. Goodii*) which was primarily identified in 1999 using 16S rRNA gene sequencing [1-3]. *M. Wolinskyi* infection can happen weeks or months following surgeries or procedures. The majority of infections are reported following cosmetic surgeries. *M. Wolinskyi* appears to be an opportunistic infection that can affect both immunocompromised and immunocompetent patients as well [1]. These bacteria are capable of producing biofilms facilitating antibiotic resistance. Pathogenesis includes direct inoculation during contact with contaminated water supplies in an operating room or secondary to postoperative wound contamination. Risk factors include specific procedures and repetitive injections as with cosmetic surgeries [2,3,5]. *M. Wolinskyi* cases have been reported in Brazil, the USA, and Switzerland.

2. Case Presentation

A 30-year-old woman with recent abdominoplasty and liposuction procedure in Iraq presented to our Emergency Department (ED) in Michigan with a few days history of right flank pain. Computed Tomography (CT) scan of abdomen and pelvis showed bilateral rim-enhancing fluid collections in the subcutaneous fat along the flanks (Figure 1). The patient underwent drainage of the right

flank abscess and drain placement within 24 hours of her presentation.

She received empiric antimicrobial therapy with Vancomycin plus Cefepime. Aerobic and anaerobic bacterial cultures were negative. She improved mildly and was discharged home on oral Amoxicillin/Sulbactam 875-125 mg every 12 hours for eight days. Two days after discharge, the fluid culture grew an Acid-fast bacillus (AFB) that was later identified as *Mycobacteria Wolinskyi*. The patient was informed about the new results and was started on an empiric regimen for atypical mycobacterial infection (Clarithromycin 500 BID, Linezolid 600 BID, and Ciprofloxacin 500 BID) while sensitivity testing was pending.

The patient did not tolerate her oral antibiotics regimen and returned to the emergency department with persistent vomiting and decreased oral intake. CT scan of abdomen and pelvis showed soft tissue swelling and re-accumulation of fluid collection. She underwent imaging-guided drainage which yielded thick white purulent fluid from the right flank. AFB Culture grew again Acid-fast bacillus (AFB) that was identified as *M. Wolinskyi* RGM. Pathology slides reported noncaseating granulomas (Figure 2). The plastic surgery team performed surgical debridement of a large amount of necrotic tissue and placed a wound-Vac. Cultures were again positive for *M. Wolinskyi*. A repeated CT scan of the abdomen showed no residual collection. She was then discharged home on Amikacin (IM 1000 mg three times a week), Doxycycline (100 mg every 12 hours), and ciprofloxacin (500 mg every 12 hours) for a minimum of 10 weeks with close follow up visits.

The patient presented again to ED five days after her discharge. She was found to have extensive abdominal

wall abscesses. She underwent extensive surgical debridement for the second time by the Plastic surgery team. She was then discharged home three days following surgery on the same antibiotics regimen. Two days later, she presented to our emergency with right upper extremity (RUE) swelling and pain. Ultrasound of RUE did not reveal a deep vein thrombosis. During this hospitalization, antibiotics susceptibility results came back (Table 1). Minimal inhibitory concentrations (MIC) results showed susceptibility to Amikacin and Ciprofloxacin. However, the microorganism was resistant to clarithromycin. Repeated CT scan showed progressive soft tissue abscess fluid collections (Figure 3). The patient underwent a third surgical debridement of necrotizing tissues (Figure 4) as well as wound-Vac placement. She was then discharged to a long term acute care facility for wound care and intravenous antibiotics.

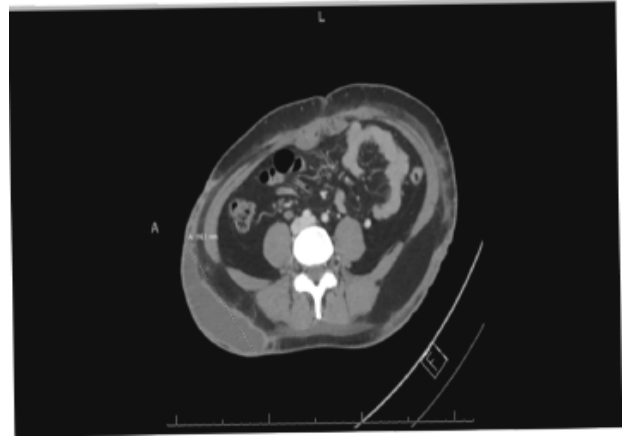


Figure 1. Right flank Abscess measuring up to 11.6 x 3.0 x 6.1 cm

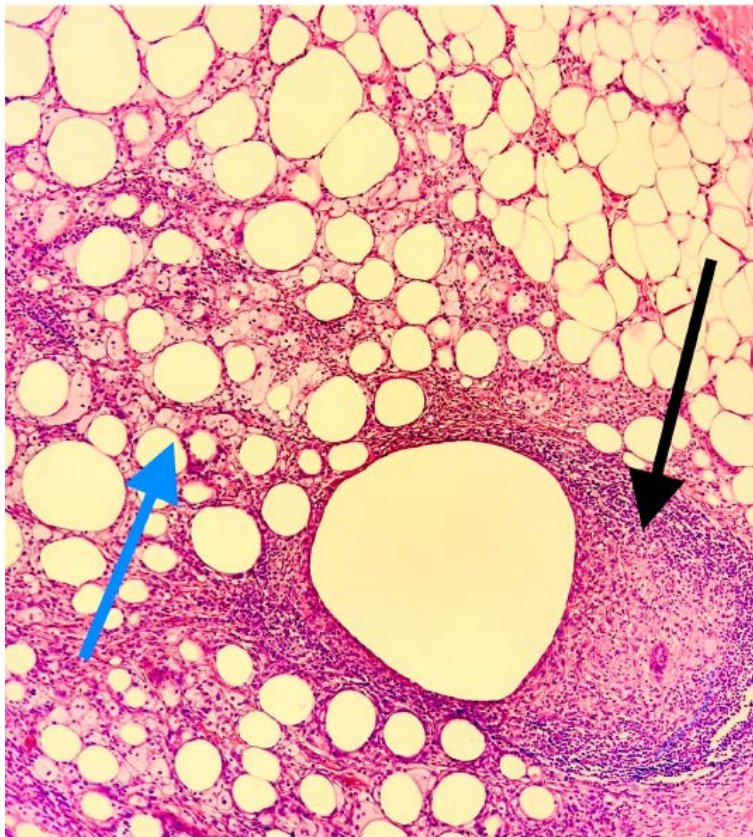


Figure 2. Black arrow granulomatous inflammation and blue arrow collections of xanthoma cells/foamy histiocytes

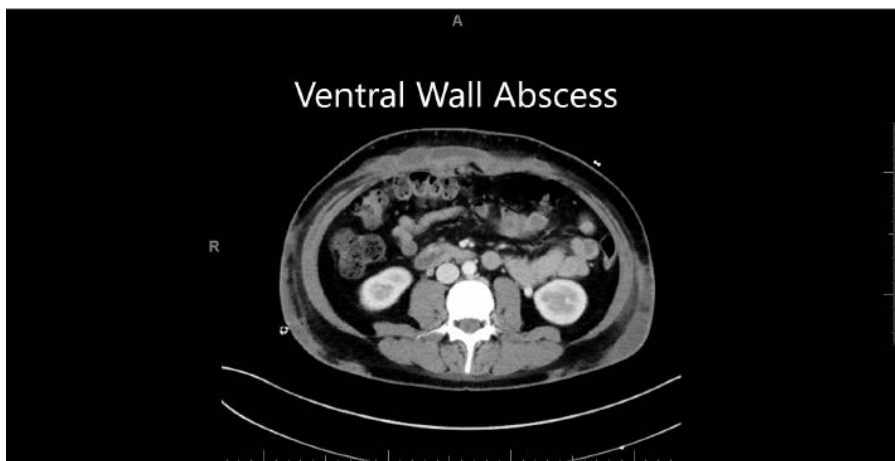
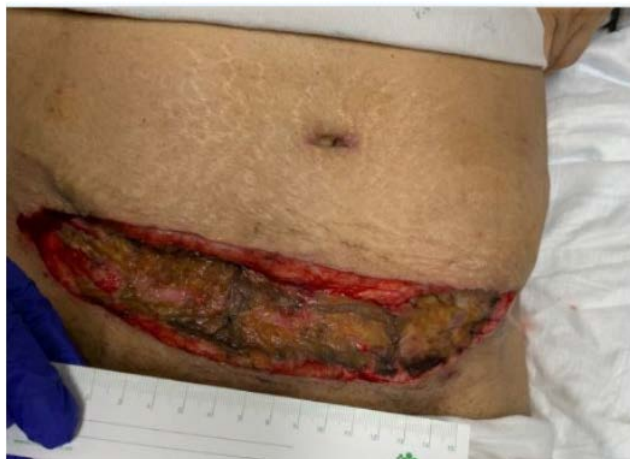

Figure 3. Ventral wall abscess measuring 2.2 Cm in greatest Anteroposterior diameter

Table 1. Suceptibility

Antibiotic	MIC (ug/ml)	Interpretation
Amikacin	2	Susceptible
Cefoxitin	64	Intermediate
Ciprofloxacin	0.5	Susceptible
Clarithromycin	>=32	Resistant

**Figure 4.** Anterior abdominal wall necrotizing fasciitis 4.8 x 26 x 2 cm

3. Discussion

M. Wolinskyi is a rapidly growing mycobacterium that rarely grows in cultures. It is mainly identified by sophisticated genetic probes [1,2]. In our case, the mycobacterial load was significant enough to result in growth on cultures within days of collection and on multiple specimens.

M. Wolinskyi is highly associated with skin and soft tissue infections following trauma or surgery, especially cosmetic procedures. *M. Wolinskyi* can appear weeks or months after the surgery and usually causes incisional wound infection with extensive suppuration. Most cases report abscess formation and soft tissue inflammation [1-5]. Typically, *M. Wolinskyi* causes post-operative infections in patients where a foreign body or metallic object is present to serve as a focus for biofilm formation.

Antimicrobial therapy of *M. Wolinskyi* infection depends on the sensitivity and the susceptibility of the mycobacterial species. There is no standard regimen or duration of therapy. The clinical and laboratory standards institute (CLSI) recommends broth microdilution MIC susceptibility testing to tailor antimicrobial regimens. *M. Wolinskyi* is frequently susceptible to amikacin, quinolones, trimethoprim-sulfamethoxazole, linezolid, and intermediately to cefoxitin and clarithromycin. It is usually resistant to tobramycin [1-3]. Its resistance to tobramycin is one of the features that can distinguish it from other members of the *M. Segmatis* group [5].

In this paper, we discussed a case of recurrent abscesses caused by *M. Wolinskyi* following abdominoplasty. It is unclear whether Mycobacterial inoculation occurred

during contact with contaminated water supplies in the operating room or secondary to postoperative wound contamination. Our patient had abdominoplasty in Iraq five weeks before her initial presentation. She is a thirty-year-old female with no significant past medical history. What distinguishes this case from prior reports of postoperative *M. Wolinskyi* infections is the relatively rapid onset of symptoms within a few weeks. Additionally, the patient did not have foreign bodies that are commonly associated with biofilm formation and infection progression. Lastly, the patient had severe necrotic soft tissue infection that involved deep muscle fascial layers which is uncommon in *M. Wolinskyi* infection reported so far.

4. Conclusion

M. Wolinskyi skin and soft tissue infection can develop at any time, in immune-competent hosts following cosmetic surgeries. It can be severe enough to cause necrotizing tissue infections. Adequate surgical debridement in addition to prolonged antimicrobial treatment are associated with better outcomes and decreased mortality.

Conflict of Interest

None of the authors have any conflicts of interest to declare.

Disclosure of Funding

None of the authors have any source of funding to declare.

References

- [1] Ariza-Heredia, E., Dababneh, A., Wilhelm, M., Wengenack, N., Razonable, R. and Wilson, J., *Mycobacterium wolinskyi: a case series and review of the literature*. Diagnostic Microbiology and Infectious Disease, 2011,71(4), pp.421-427.
- [2] Yoo, S., Lee, K., Jung, S., and Heo, S., *Facial skin and soft tissue infection caused by Mycobacterium wolinskyi associated with cosmetic procedures*. BMC Infectious Diseases, 2013, 13(1).
- [3] Bossart, S., Schnell, B., Kerl, K., and Urosevic-Maiwald, M., *Ulcers as a Sign of Skin Infection with Mycobacterium wolinskyi: Report of a Case and Review of the Literature*. Case Reports in Dermatology, 2016, 8(2), pp.151-156.
- [4] Nagpal, A., Wentink, J., Berbari, E., Aronhalt, K., Wright, A., Krageschmidt, D., Wengenack, N., Thompson, R., and Tosh, P. *A Cluster of mycobacterium wolinskyi Surgical Site Infections at an Academic Medical Center*. Infection Control & Hospital Epidemiology, 2016, 35(9), pp.1169-1175.
- [5] Lima, A., Neves, M., Gomes, K., Guarines, K., Luna, C., Duarte, R., Montenegro, L., and Schindler, H., *First case report of infection by Mycobacterium wolinskyi after mammoplasty in Brazil*. Infectious Disease Reports, 2013, 5(2), p.12.

