

Hearing Loss with Diffuse Meningeal Enhancement: A Rare Initial Presentation of Sarcoidosis

Sufyan Abdul Mujeeb^{1*}, Syed Hussain², Abdallah Hamdallah³

¹Department of Internal Medicine, Advocate Lutheran General Hospital, Park Ridge, USA

²Department of Internal Medicine, McLaren Greater Lansing Hospital, Lansing, USA

³Department of Neurology, Advocate Lutheran General Hospital, Park Ridge, USA

*Corresponding author: sufyan.abdulmujeeb@aah.org

Received November 19, 2020; Revised December 20, 2020; Accepted December 27, 2020

Abstract Background: Sarcoidosis is a systemic disease that can affect almost any organ system, with lungs being the most commonly involved. Other organ systems that may be affected include the skin, eyes, joints, heart, kidneys, or the gastrointestinal tract. Symptoms of sarcoidosis depend on the organ system involved. For instance, pulmonary involvement usually presents with cough and shortness of breath. Involvement of the joint usually presents with joint pain. Neurological manifestation, termed as neurosarcoidosis, is a relatively uncommon initial presentation of sarcoidosis. Patients with neurosarcoidosis can be asymptomatic or have multiple neurological findings such as numbness, paresthesias, hearing loss, vision changes, headaches etc. **Case Report:** We report a case of a young African American male who presented with hearing loss and bilateral lower extremity paresthesias. Subsequent imaging of his brain and spinal cord showed diffuse meningeal enhancement of the cerebrum, thoracolumbar spine, and cranial nerves (CN) V, VII, and VIII. Biopsy of calcified subcarinal lymph nodes seen on imaging showed non-caseating granulomas, consistent with the diagnosis of sarcoidosis. **Conclusion:** Neurosarcoidosis can present in many different ways, making it difficult to diagnose. There have been multiple studies that tried to find a pattern to this disease in order to make the diagnosis easier. However, no specific or sensitive findings to neurosarcoidosis could be concluded from those studies. To our knowledge, such a diffuse involvement of sarcoidosis in the nervous system has so far not been reported. Our case demonstrates yet another way neurosarcoidosis can present and the importance of keeping this diagnosis on the differential when dealing with patients presenting with similar symptoms.

Keywords: *sarcoidosis, neurosarcoidosis, meningeal enhancement, hearing loss*

Cite This Article: Sufyan Abdul Mujeeb, Syed Hussain, and Abdallah Hamdallah, "Hearing Loss with Diffuse Meningeal Enhancement: A Rare Initial Presentation of Sarcoidosis." *American Journal of Medical Case Reports*, vol. 9, no. 3 (2021): 140-143. doi: 10.12691/ajmcr-9-3-1.

1. Background

Sarcoidosis is a multisystemic disease process that is driven by T-cell-mediated formation of widespread noncaseating granulomas in various tissues and organs. Specific etiology of sarcoidosis currently remains under debate, however, both environmental and genetic factors may contribute towards the development of this disease. For instance, *Jordan et al.* found that working on the World Trade Center debris pile was associated with an increased risk of sarcoidosis, suggesting an association with environmental factors [1]. Incidence, as well as severity of the disease is higher in females of African heritage [2] as opposed to any other ethnicity, suggesting a genetic predisposition to this disease. Although these granulomas can involve any organ system, pulmonary manifestation is the most common with involvement of the mediastinal lymph nodes. Prominent mediastinal lymph nodes can be seen on imaging in up to 95% of cases. [3]

Neurosarcoidosis, a term used to describe the neurological manifestations of sarcoidosis, is a rare occurrence seen in about 5-15% of patients that carry the diagnosis of sarcoidosis [4]. Neurosarcoidosis is usually seen in patients with significant systemic involvement of the disease. Pure neurological findings, without any other systemic symptoms, are even more rare, occurring in less than 10% of cases [4].

2. Case Report

A 47-year-old African American male presented to the hospital with unilateral right-sided hearing loss that gradually progressed bilaterally. He was seen at an audiology clinic prior to presentation at our facility and was diagnosed with moderate sensorineural hearing loss. He also complained of intermittent headaches and paresthesias in the bilateral lower extremities. Vision changes identified as multicolored floaters along with intermittent facial and lip numbness have also been

reported. He had been experiencing these symptoms for six months to a year. His social history was significant for polysubstance use and incarceration for five years, approximately 10 years prior to presentation. He reported use of heroin, cocaine, alcohol, marijuana, and ecstasy in the past, but denied use of any substances for at least six months prior to presentation. His medical and surgical history was unremarkable and he did not report taking any home medications.

His physical exam was significant for mild dysmetria on finger-to-nose testing and mildly ataxic, wide-based gait. He was also found to have decreased sensation to vibration and impaired proprioception in the right lower extremity more than the left. His vitals and basic admission labs were unremarkable. Magnetic resonance imaging (MRI) of the brain (Figure 1 and Figure 2) showed diffuse meningeal enhancement of the supratentorial and infratentorial hemispheres, along with pathological enhancement of multiple cranial nerves most prominently involving CN V, VII, and VIII. Mild hydrocephalus was also noted. MRI of the spine (Figure 3) showed extensive meningeal enhancement throughout a significant portion of the thoracolumbar spine. Differential diagnosis of these findings includes meningeal carcinomatosis and granulomatous disease.

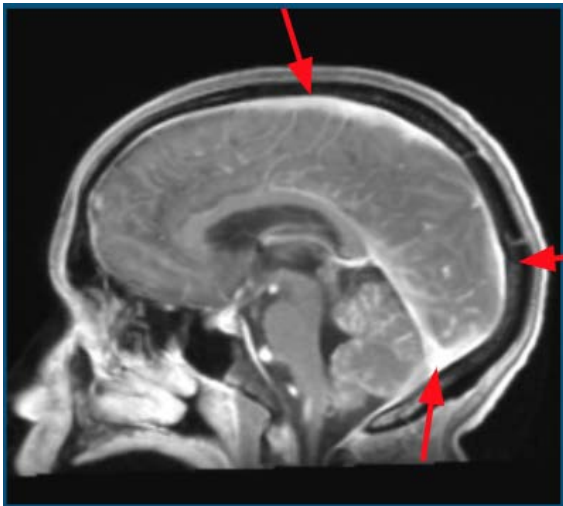


Figure 1.

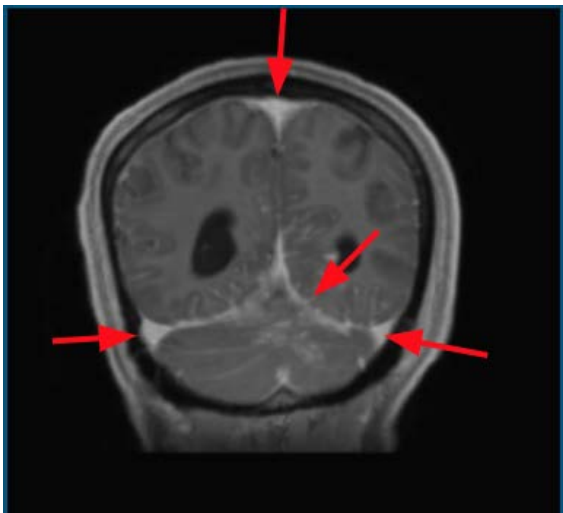

Figure 2.

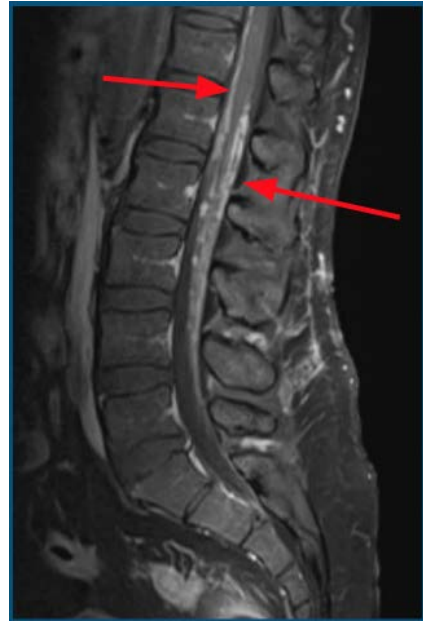

Figure 3.

Based on the above imaging findings and history of incarceration, tuberculous (TB) meningitis was on top of our differential. Infectious disease was consulted and he was immediately started on quadruple anti-tuberculous treatment with rifampin, isoniazid, pyrazinamide, and ethambutol. A chest x-ray was performed to rule out pulmonary TB. It resulted without any significant cardiopulmonary pathology. Quantiferon gold and TB interferon gamma release assay studies were negative. Cerebrospinal fluid (CSF) analysis revealed low glucose at 33, high protein at 243, high IgG levels at 37.7, and no oligoclonal bands. CSF cytology for malignant cells, mycobacterial, and fungal stains & cultures were negative. Serum angiotensin converting enzyme (ACE) and other autoimmune labs such as anti-neutrophil antibody (ANA), anti-neutrophil cytoplasmic antibody (ANCA), rheumatoid factor were also negative. CT, chest, abdomen, and pelvis was performed to rule out a primary malignant lesion. It revealed large, calcified subcarinal and bilateral hilar lymph nodes (Figure 4). Transbronchial biopsy of the lymph nodes revealed non-caseating granulomas consistent with the diagnosis of sarcoidosis. Additionally, tissue samples were negative for TB stain (Figure 5 and Figure 6).

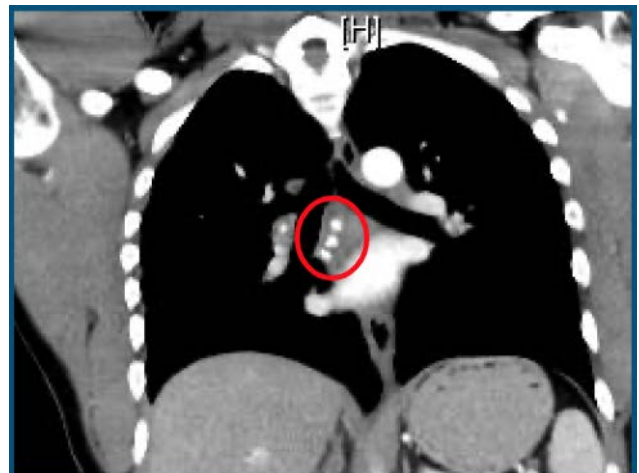


Figure 4.

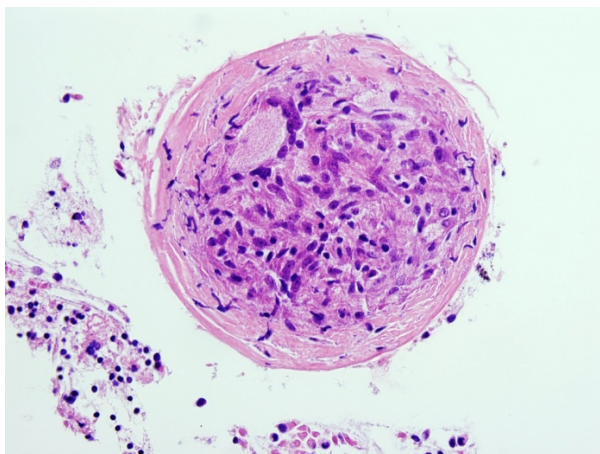


Figure 5.

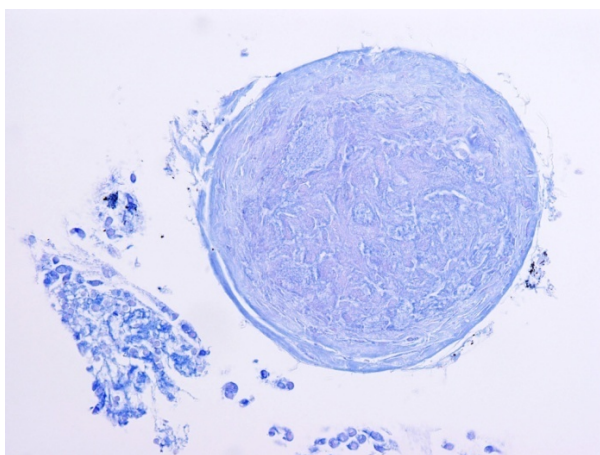


Figure 6.

Per the local department of public health, it was determined that he must empirically complete the anti-tuberculous treatment. He was then started on prednisone 60 mg daily for three months. After completing the antituberculous and steroid therapy, a repeat MRI brain and spine showed interval resolution of previously demonstrated meningeal enhancement. However, his hearing loss had no significant improvement.

3. Discussion

Pawate et al. conducted a retrospective study of 54 cases of neurosarcoidosis to find a specific pattern of disease presentation. However, they concluded that clinical findings and imaging studies are extremely variable from patient to patient, deeming the diagnosis of neurosarcoidosis difficult to make [5]. Out of the 54 cases, only five cases were reported to have hearing loss as the initial presentation. The study found primarily visual disturbances secondary to optic neuropathy and an abnormality of CN II on MRI to be the most common initial presentation of neurosarcoidosis. Meningeal enhancement of the brain was seen in ten cases and CN VIII enhancement was seen in only one case. Abnormal MRI of the spine was seen in 13 cases in this study. Besides CN II and CN VIII, no other CN involvement was reported in this study. However, *Ungprasert et al.* conducted a retrospective study on long-term prognosis of

neurosarcoidosis cases from 1976-2013 and found only 11 cases of neurosarcoidosis [6]. Among those cases, CN VII involvement was seen in three cases. Diffuse leptomeningeal enhancement was seen in one case, which had an initial presentation of headache. No involvement of the spinal cord on imaging was found in any of the 11 cases in this study. As evidenced by these studies, neurosarcoidosis can present, both clinically and on imaging, in many ways. Therefore, no single finding can be concluded as being highly specific or sensitive to neurosarcoidosis, making it very difficult to diagnose without biopsy.

In regard to treatment, corticosteroids remain the mainstay of therapy. *Ungprasert et al.* reported a good response to steroids in 9 out of 11 cases [6]. Infliximab has also shown promising results in patients who are refractory to steroid therapy [7]. TNF-alpha is found to play a significant role in the pathogenesis of sarcoidosis and inhibitors of TNF-alpha, such as thalidomide, are also being used frequently to treat refractory sarcoidosis. [8]

4. Conclusion

Neurological manifestation of sarcoidosis is very rare. Patients can present with a wide range of symptoms including, but not limited to, visual disturbances, hearing loss, balance abnormalities, and peripheral paresthesias. Imaging can also reveal a wide spectrum of findings. Although meningeal enhancement on MRI of the brain is a documented finding, to our knowledge, the involvement of multiple cranial nerves along with diffuse meningeal enhancement of both the brain and thoracolumbar spine has so far not been reported in an individual patient. In all case reports that have been reviewed, there have been either isolated cerebral findings, isolated cranial nerve findings, or isolated spinal cord findings reported. Our case demonstrates yet another way neurosarcoidosis can present on imaging. It also demonstrates the importance of keeping sarcoidosis on the differential when imaging is not consistent with any specific diagnosis. Treatment for neurosarcoidosis, however, remains the same as sarcoidosis involving any other organ system. Our patient demonstrated improvement on imaging after a course of steroids. He did not, however, show significant improvement in his hearing loss. He is currently continuing his steroid therapy with plans to potentially start a trial of infliximab.

Financial Source

No financial source was provided for this manuscript

Disclosure

There are no actual or potential conflict of interest in relation to this manuscript

References

- [1] Jordan, Hannah T. MD; Stellman, Steven D. PhD; Prezant, David MD; Teirstein, Alvin MD; Osahan, Sukhminder S. PhD; Cone,

- James E. MD Sarcoidosis Diagnosed After September 11, 2001, Among Adults Exposed to the World Trade Center Disaster, *Journal of Occupational and Environmental Medicine*: September 2011 - Volume 53 - Issue 9 - p 966-974.
- [2] Christopher E. Cox, Angela Davis-Allen, Marc A. Judson, Sarcoidosis, *Medical Clinics of North America*, Volume 89, Issue 4, 2005, Pages 817-828.
- [3] Lynch J, Ma Y, Koss M, White E. Pulmonary sarcoidosis. *Semin Respir Crit Care Med* 2007; 28:53-74.
- [4] "Neurosarcoidosis: Background, Pathophysiology, Etiology." Medscape, 12 May 2020, <https://emedicine.medscape.com/article/1147324-overview>.
- [5] S. Pawate, et al. "Presentations and Outcomes of Neurosarcoidosis: A Study of 54 Cases." *Advance Access Publication*, vol. 102, Apr. 2009, pp. 449-460.
- [6] Ungprasert, Patompong , et al. "Characteristics and Long-Term Outcome of Neurosarcoidosis: A Population-Based Study from 1976-2013 ." *Neuroepidemiology*, vol. 48, 2017, pp. 87-94.
- [7] Santos E, Shaunak S, Renowden S, et al Treatment of refractory neurosarcoidosis with Infliximab *Journal of Neurology, Neurosurgery & Psychiatry* 2010; 81: 241-246.
- [8] Hammond, E., Kaplin, A. & Kerr, D. Thalidomide for acute treatment of neurosarcoidosis. *Spinal Cord* 45, 802-803 (2007).



© The Author(s) 2021. This article is an open access article distributed under the terms and conditions of the Creative Commons Attribution (CC BY) license (<http://creativecommons.org/licenses/by/4.0/>).