

Fluoroquinolone-Induced Rotator Cuff Tendinopathy: A Case Report

Hussam Alkaissi¹, Srinivas Kolla², Cameron Page¹, Latif Salam¹,
Moro O. Salifu¹, Isabel M. McFarlane^{1,*}

¹Department of Internal Medicine, State University of New York, Downstate Health Sciences University, Brooklyn, NY 11203, USA

²Department of Radiology, State University of New York, Downstate Health Sciences University, Brooklyn, NY 11203, USA

*Corresponding author: Isabel.McFarlane@downstate.edu

Received November 10, 2020; Revised December 11, 2020; Accepted December 18, 2020

Abstract Fluoroquinolones are antimicrobial agents that inhibit bacterial DNA synthesis by binding to DNA gyrase and DNA topoisomerase IV. Fluoroquinolones have also been associated with the development of tendinopathy, tendon rupture, and arthropathy. The postulated mechanisms for quinolone-associated tendinopathy are alteration of the tendon extracellular matrix, impairment of tenocyte proliferation, and enhanced apoptosis due to the quinolone cation chelation properties. We present a case of a man who developed multiple tears of the rotator cuff after exposure to levofloxacin. Although marketed quinolones are well tolerated, adverse events involving gastrointestinal, cardiovascular, neurological, and tendinopathy and at-risk patient populations should be kept in mind by clinicians.

Keywords: fluoroquinolone, tendinopathy, rotator cuff

Cite This Article: Hussam Alkaissi, Srinivas Kolla, Cameron Page, Latif Salam, Moro O. Salifu, and Isabel M. McFarlane, "Fluoroquinolone-Induced Rotator Cuff Tendinopathy: A Case Report." *American Journal of Medical Case Reports*, vol. 9, no. 2 (2021): 122-124. doi: 10.12691/ajmcr-9-2-6.

1. Introduction

Fluoroquinolones were introduced in 1962. Since then, several modifications to the basic bi-cyclic structure have allowed subsequent generations to be used in several bacterial infections, including respiratory, genitourinary, skin and soft tissues, sexually transmitted infections, and gastroenteritis. Some of the common adverse reactions to fluoroquinolones include gastrointestinal upset, headache, and photosensitivity [1]. Fluoroquinolone-induced tendinopathy was first reported in 1983, and soon after, it was recognized as a class-related adverse reaction [2]. Achilles tendon is most commonly involved, but tendinopathy of other tendons have been reported in the literature, including one report of rotator cuff tendons involvement [3,4]. In this case, we describe a case of rotator cuff tendons involvement around the shoulder joint following levofloxacin use.

2. Clinical Case

A 78-year-old male presented to the emergency department with a history of acute left shoulder pain for 6 hours. The pain started suddenly and woke the patient up from his sleep. It was diffuse throughout the left shoulder, stabbing in character and radiating down to the mid-arm. No prior heavy weight lifting or trauma. He had mild

epigastric discomfort that was relieved by passing gas. The patient reported no fever, chills, or sweating. His medical history was notable for diabetes, hypertension, chronic kidney disease not requiring dialysis, alcoholic cirrhosis, and sarcoidosis. Medications included glimepiride, olmesartan, furosemide, and sodium bicarbonate. The patient was a retired worker whose earlier job included heavy weight lifting during his youth. The patient reported a history of smoking and alcohol intake in the past, but had quit about three years earlier to his presentation. Two weeks before this presentation, he had been admitted for an episode of infectious colitis, for which he was prescribed levofloxacin 750 mg daily for five days.

The patient was afebrile and vitally stable but appeared in acute pain and holding his left arm with his other arm, avoiding any motion. Examination of the shoulder joint showed marked tenderness on palpation, moderate swelling compared to the contralateral side, and limitation of range of motion due to pain. The pain was elicited on both passive and active movement of the left upper limb in any direction—no deformity, erythema, or warmth. The examination of the rest of the left upper extremity was unremarkable. Scleral icterus was noticed on eye examination. Examination of the abdomen and chest were normal as well.

Blood levels of inflammatory markers were significantly elevated with an erythrocyte sedimentation rate (ESR) level of 33 mm/hr (reference range < 10 mm/hr), C-reactive protein (CRP) level of 103 mg/l (reference range < 8 mg/l) with normal white cell count. The rest of the labs were

unchanged from baseline, with an elevated total bilirubin of 5.1 mg/dl (reference range 0.3-1 mg/dl), creatinine of 1.5 mg/dl (reference range 0.7-1.3 mg/dl), chronically low magnesium of 1.4 mg/dl (reference range 1.9-2.7 mg/dl), platelets count of 64,000/ul, and macrocytic anemia with hemoglobin of 13.8 g/dl and mean corpuscular volume of 105 fl (mg/dl 80-95 fl). Elevated ACE levels of 106 U/l were also noticed (reference range 9-67 U/l). Shoulder X-rays showed bilateral severe acromioclavicular osteoarthritis. Left shoulder MRI showed a complete tear of the supraspinatus tendon, subscapularis tendon, biceps-labral complex, glenohumeral effusion extending to the subdeltoid, and subacromial bursa due to the full thickness tear of the supraspinatus tendon (Figure 1).

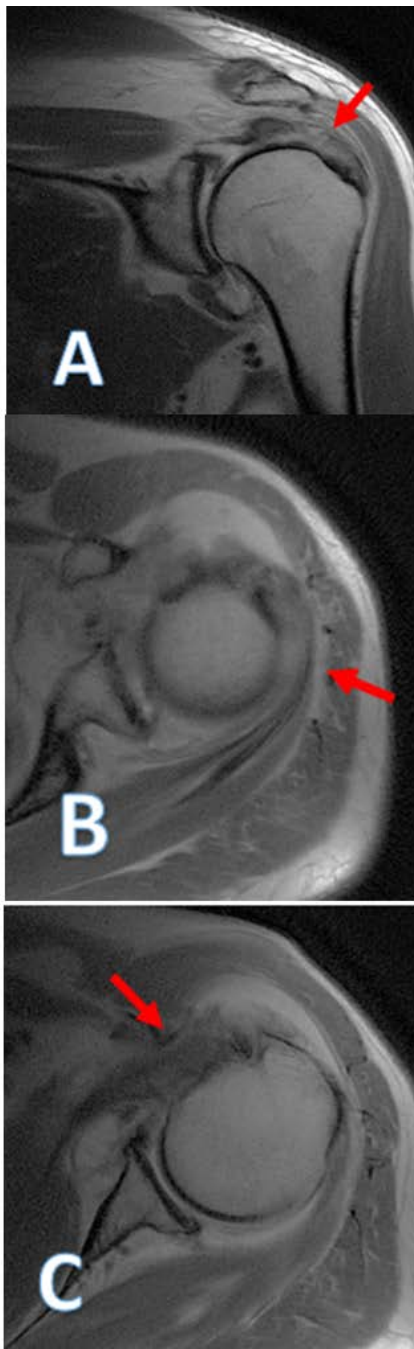


Figure 1. Proton density MR images of the left shoulder joint demonstrating extensive tendinosis and tearing (arrows) of the rotator cuff, involving the supraspinatus tendon on coronal imaging (A), infraspinatus (B), and subscapularis tendons on axial imaging (C)

Multiple attempts to aspirate the glenohumeral fluid for analysis were unsuccessful. The patient was treated with analgesia and rest. The pain improved gradually over two weeks.

3. Discussion

Fluoroquinolone-induced tendinopathy is a rare encounter. It includes both tendonitis and tendon rupture. The first case of fluoroquinolone tendonitis was reported in 1983. The incidence of fluoroquinolone induced tendinopathy was about 3.2 patients per 1000 prescription. Risk factors include age above 60, chronic lung diseases, steroids use, diabetes, hypomagnesemia, and trauma. Tendinopathy usually develops after an average period of 13 days following the use of fluoroquinolone. The basic structure of fluoroquinolones can explain part of the tendon toxicity. A proposed mechanism for fluoroquinolone induced tendinopathy might involve tendon ischemia, reduced proliferation and activity of tenocytes, or reduction of type 1 collagen, a significant constituent of tendons extracellular matrix [5]. Studies have shown increased matrix metalloproteinase expression in fibroblasts treated with fluoroquinolone, a culprit enzyme of matrix degradation [6,7]. Achilles tendon is most commonly involved - about 90% of all fluoroquinolone-induced tendinopathy, 50% of which is bilateral [8].

Here we report a case of acute left shoulder pain two weeks after treatment with levofloxacin in a patient with sarcoidosis. The main differential diagnoses were septic arthritis, sarcoidosis-related musculoskeletal manifestations, and adverse reaction to fluoroquinolones. MRI showed tears in multiple rotator cuff tendons and glenohumeral effusion. Despite our patient's history of pulmonary sarcoidosis and current elevation of ACE, sarcoid would not explain the multiple tendons' tears. Musculoskeletal manifestations of sarcoidosis usually involve arthropathy - usually around in the ankle joint [9]. Hand tenosynovitis is another manifestation, yet no reports of tendon rupture to our knowledge [10]. Reports of patients with shoulder pain in sarcoidosis showed humeral head involvement with lytic lesions on imaging [11]. The other differential diagnosis was septic arthritis. Multiple attempts to aspirate the glenohumeral effusion failed as the volume was too small and resolved over time. The patient was afebrile, had no leukocytosis, and blood cultures were negative. Significant involvement of rotator cuff tendons rather than joint disease made the diagnosis of septic arthritis less likely. A Naranjo adverse drug reaction score was 7, labeling this report a "probable" reaction to fluoroquinolone [12]. The standard method to prove causality is a challenge test, but that is rarely done intentionally when the index of suspicion is high, as in this case. Rotator-cuff induced tendinopathy following fluoroquinolone has been reported once before. The patient also used levofloxacin, had similar effusion in the glenohumeral joint, and elevated inflammatory markers (ESR and CRP) [4]. Our patient had bilateral acromioclavicular osteoarthritis, a condition that can contribute to the supraspinatus tear, but not other rotator cuff tendinopathy.

Thus in our patient, levofloxacin might have been the "second hit" to a chronically impinged supraspinatus, resulting

in such dramatic involvement of supraspinatus tendon with milder involvement in other tendons. The patient's renal impairment (estimated GFR of 58 mL/min/1.73 m²) puts him at risk for this reaction, as more than 80% of levofloxacin is renally cleared [13]. Fluoroquinolones are known chelators of divalent and trivalent cations. Hypomagnesemia is another risk factor in our patient (Mg⁺² levels were 1.4 mg/dl), as it compounds the fluoroquinolone magnesium chelation effect. Magnesium is essential in integrin signaling, a protein that plays a role in maintaining the extracellular matrix's integrity in tendons. Thus, by chelating magnesium from tendons, fluoroquinolones can lower integrin levels, leading to reduced MAPK signaling, reduced proliferation of tenocytes, and increased caspase-3, an effector of apoptosis [14]. Animal studies of fluoroquinolone exposure in hypomagnesemic rats and dogs showed a more profound toxic effect on joints and tendons [15]. Other proposed mechanisms for fluoroquinolone induced tendinopathy include tendon ischemia, tenocyte injury, or increase expression of matrix metalloproteinase that lead to degradation of the tendon matrix [5]. The glenohumeral effusion can also be explained as an adverse reaction to fluoroquinolone. Effusions in several joints have been reported, including the glenohumeral joint [4,16]. One possible mechanism is fluoroquinolone chondrotoxic effects through magnesium chelation as well. Accumulation of reactive oxygen species and fluoride are other possible mechanisms. Fluoroquinolones can also cause a spectrum of muscle injury ranging from myalgia to rhabdomyolysis [16]. Luckily, our patient did not complain of any muscle pain and had normal levels of creatinine kinase.

Although marketed quinolones are well tolerated, adverse events involving gastrointestinal, cardiovascular, neurological, and tendinopathy are known to occur. Clinicians should keep in mind at-risk patient populations for the development of untoward events related to these drugs.

4. Acknowledgements

This work is supported, in part, by the efforts of Dr. Moro O. Salifu M.D., M.P.H., M.B.A., M.A.C.P., Professor and Chairman of Medicine through NIH Grant number S21MD012474.

References

- [1] Oliphant CM, Green GM. Quinolones: a comprehensive review. *Am Fam Physician*. 2002 Feb 1; 65(3): 455-64. PMID: 11858629.
- [2] Bailey RR, Kirk JA, Peddie BA. Norfloxacin-induced rheumatic disease. *N Z Med J*. 1983 Jul 27; 96(736): 590. PMID: 6223241.
- [3] Khaliq Y, Zhanel GG. Fluoroquinolone-associated tendinopathy: a critical review of the literature. *Clin Infect Dis*. 2003 Jun 1; 36(11): 1404-10. Epub 2003 May 20. PMID: 12766835.
- [4] Araujo Eyer-Silva, Walter de, Henrique de Barros Pinto Netto, Jorge Francisco da Cunha Pinto, Fernando Raphael de Almeida Ferry, and Rogério Neves-Motta. "Severe Shoulder Tendinopathy Associated with Levofloxacin." *The Brazilian Journal of Infectious Diseases* 16, no. 4 (July 1, 2012): 393-95.
- [5] Childs, Sharon G. Pathogenesis of Tendon Rupture Secondary to Fluoroquinolone Therapy, *Orthopaedic Nursing: May-June 2007 - Volume 26 - Issue 3 - p 175-182*.
- [6] Lewis T, Cook J. Fluoroquinolones and tendinopathy: a guide for athletes and sports clinicians and a systematic review of the literature. *J Athl Train*. 2014; 49(3): 422-427.
- [7] Wilton LV, Pearce GL, Mann RD. A comparison of ciprofloxacin, norfloxacin, ofloxacin, azithromycin and cefixime examined by observational cohort studies. *Br J Clin Pharmacol*. 1996 Apr; 41(4): 277-84.
- [8] van der Linden PD, Sturkenboom MC, Herings RM, Leufkens HG, Stricker BH. Fluoroquinolones and risk of Achilles tendon disorders: case-control study. *BMJ*. 2002; 324(7349): 1306-1307.
- [9] Nessrine A, Zahra AF, Taoufik H. Musculoskeletal involvement in sarcoidosis. *J Bras Pneumol*. 2014; 40(2): 175-182.
- [10] Katie Bechman, Dimitrios Christidis, Sarah Walsh, Surinder S Birring, James Galloway. A review of the musculoskeletal manifestations of sarcoidosis, *Rheumatology*, Volume 57, Issue 5, May 2018, Pages 777-783.
- [11] Henrie TR, Skedros JG. Sarcoid of the Upper Humerus Found Incidentally on MR Images Obtained for Work-Up of Rotator Cuff Tear Where Compromised Tissue Quality Was a Concern for Surgical Success. *Case Rep Radiol*. 2018; 2018: 3579527. Published 2018 Jun 10.
- [12] Busto U, Naranjo CA, Sellers EM. Comparison of two recently published algorithms for assessing the probability of adverse drug reactions. *Br J Clin Pharmacol*. 1982; 13: 223-7.
- [13] Fish, D. N., and A. T. Chow. "The Clinical Pharmacokinetics of Levofloxacin." *Clinical Pharmacokinetics* 32, no. 2 (February 1997): 101-19.
- [14] Hall, Mederic M., Jonathan T. Finnoff, and Jay Smith. "Musculoskeletal Complications of Fluoroquinolones: Guidelines and Precautions for Usage in the Athletic Population." *PM&R* 3, no. 2 (February 2011): 132-42.
- [15] Lozo, Edith, Kai Riecke, Rudolf Schwabe, Jürgen Vormann, and Ralf Stahlmann. "Synergistic Effect of Ofloxacin and Magnesium Deficiency on Joint Cartilage in Immature Rats." *Antimicrobial Agents and Chemotherapy* 46, no. 6 (June 1, 2002): 1755-59. 2002.
- [16] Golomb BA, Koslik HJ, Redd AJ. Fluoroquinolone-induced serious, persistent, multisymptom adverse effects. *BMJ Case Rep*. 2015; 2015: bcr2015209821. Published 2015 Oct 5.

