

Thrombus in Transit and Impending Pulmonary Embolism Detected on POCUS in a Patient with COVID-19 Pneumonia

Pramod Theetha Kariyanna¹, Naseem A. Hossain¹, Apoorva Jayarangaiah², Nimrah A. Hossain³, Vaibhavi Uppin¹, Sudhanva Hegde¹, Violeta Capric¹, Moro O. Salifu¹, Samy I. McFarlane^{1*}

¹Department of Internal Medicine, State University of New York, Downstate-Health Science University, Brooklyn, New York, USA, 11203

²Division of Hematology and Oncology, Department of Internal Medicine, Jacobi Medical Center, Albert Einstein School of Medicine, New York, USA- 10461

³Department of Internal Medicine, New York Presbyterian- Brooklyn Methodist Hospital, Brooklyn, New York, USA- 11215

*Corresponding author: smcfarlane@downstate.edu

Received April 04, 2020; Revised April 26, 2020; Accepted May 05, 2020

Abstract Coronavirus disease 2019 (COVID-19) is a pandemic that started in China in December 2019 and carries a high risk of morbidity and mortality. To-date (4-22-2020) it affected over 2.6 million people and resulted in nearly 200,000 death worldwide mainly due to severe acute respiratory syndrome coronavirus 2 (SARS-Cov-2). Among the major underlying pathophysiologic mechanisms in COVID 19 is hypercoagulability, leading to increased risk for deep vein thrombosis and pulmonary embolism that contribute to increased morbidity and mortality. In this report, we present the case of a 55-year-old man who presented with COVID-19 pneumonia, and was found to have a thrombus in transit by routine point of care ultrasound (POCUS). While computer tomography (CT) angiography is the test of choice, the utilization of point of care ultrasound (POCUS) has gained traction as an adjunctive means of surveillance for the development of VTE in patients with COVID-19. In this report, we discuss the clinical utility of POCUS in diagnosing thrombus in transit in COVID 19 populations.

Keywords: COVID 19, SARS-Cov-2, Pneumonia, deep vein thrombosis, pulmonary embolism, POCUS

Cite This Article: Pramod Theetha Kariyanna, Naseem A. Hossain, Apoorva Jayarangaiah, Nimrah A. Hossain, Vaibhavi Uppin, Sudhanva Hegde, Violeta Capric, Moro O. Salifu, and Samy I. McFarlane, "Thrombus in Transit and Impending Pulmonary Embolism Detected on POCUS in a Patient with COVID-19 Pneumonia." *American Journal of Medical Case Reports*, vol. 8, no. 8 (2020): 225-228. doi: 10.12691/ajmcr-8-8-2.

1. Introduction

Coronavirus disease 2019 (COVID-19) is a global pandemic associated with significant pulmonary and systemic manifestations [1]. Current literature shows a large cohort of patients with COVID-19 pneumonia developing venous thromboembolism, including pulmonary embolism [1]. We present the case of a 55-year-old man who presented with COVID-19 pneumonia, who was found to have a thrombus in transit by routine point of care ultrasound (POCUS).

2. Case Presentation

A 55-year-old male was brought in by emergency medical services for altered mental status (AMS). At presentation, the patient complained of fever and chills. Meaningful history could not be obtained because of the altered mental status. He was noted to have a fever of

102.3-degree Fahrenheit, heart rate of 136 beats per minute, blood pressure was 153/74 mm Hg, respiratory rate was 32 cycles per minute, and he was saturating 92% on room air. Physical examination was significant for coarse bilateral breath sounds. Laboratory investigations are tabulated and revealed acute kidney injury (Table 1). Three blood samples were negative for bacterial infection. Chest X ray revealed hazy bibasilar opacities consistent with multifocal pneumonia (Figure 1). Electrocardiogram (EKG) (Figure 2) revealed sinus tachycardia and inferior infarct. Computer tomography (CT) of the head did not reveal any intracranial pathology. Patient was diagnosed to have COVID-19 pneumonia and was started on azithromycin and hydroxychloroquine. The patient's mentation progressively worsened and was intubated on day 4 of hospitalization. A point of care ultrasound (Figure 3 - Figure 4) on day 7 of hospitalization revealed thrombus in transit in the inferior vena cava and right atrium suggesting impending pulmonary embolism hence the patient was started on thrombolytic therapy and full dose anticoagulation with heparin drip. Subsequently, the patient went into an asystole, likely related to massive

pulmonary embolism. Cardiopulmonary resuscitation was initiated according to the advanced cardiac life support (ACLS) protocol without success and the patient expired.

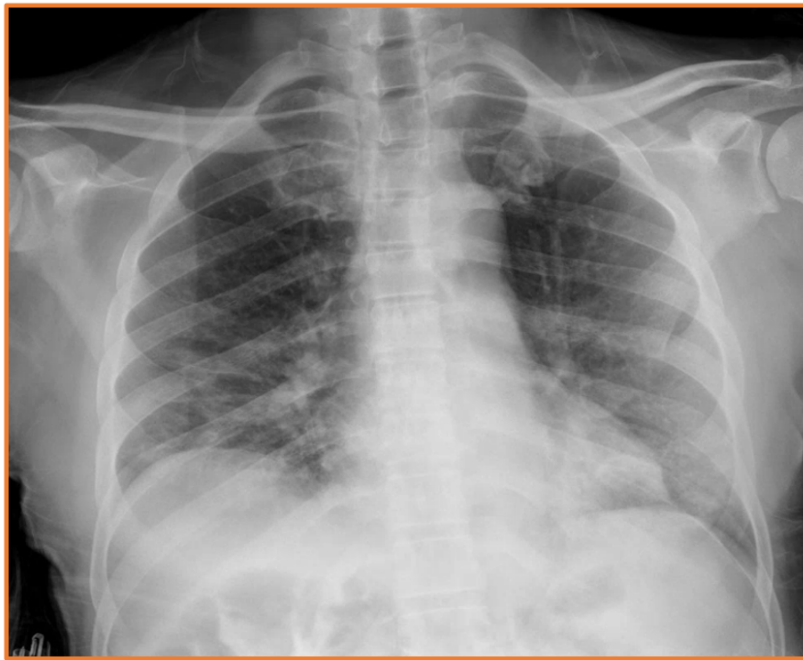


Figure 1. Chest X-ray showing hazy bibasilar opacities consistent with multifocal pneumonia

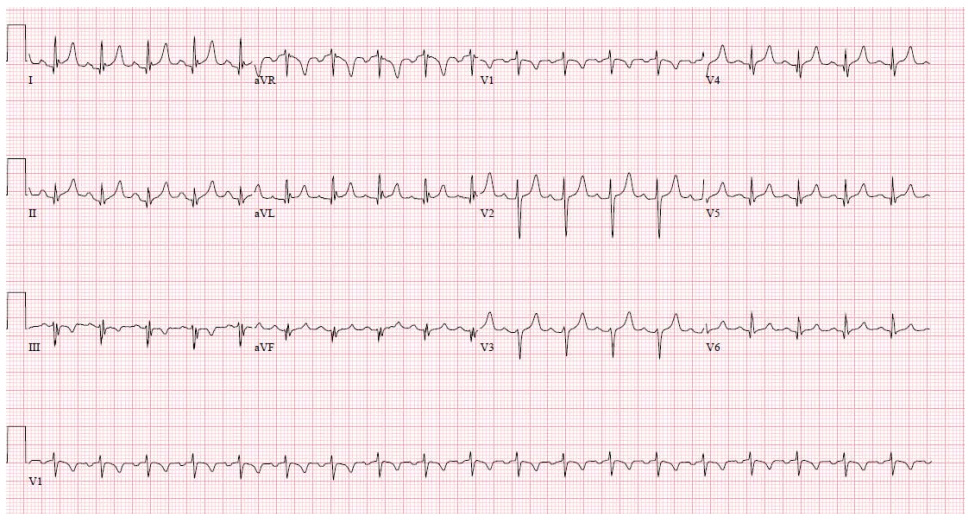


Figure 2. EKG showing sinus tachycardia and inferior infarct

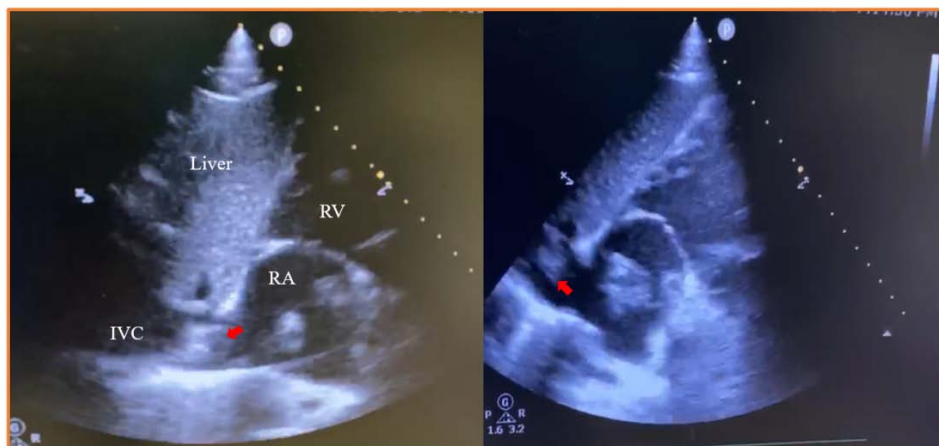


Figure 3. POCU showing thrombus in transit in the inferior vena cava (red arrow). (RA = right atrium, RV = right ventricle, IVC = inferior venacava)

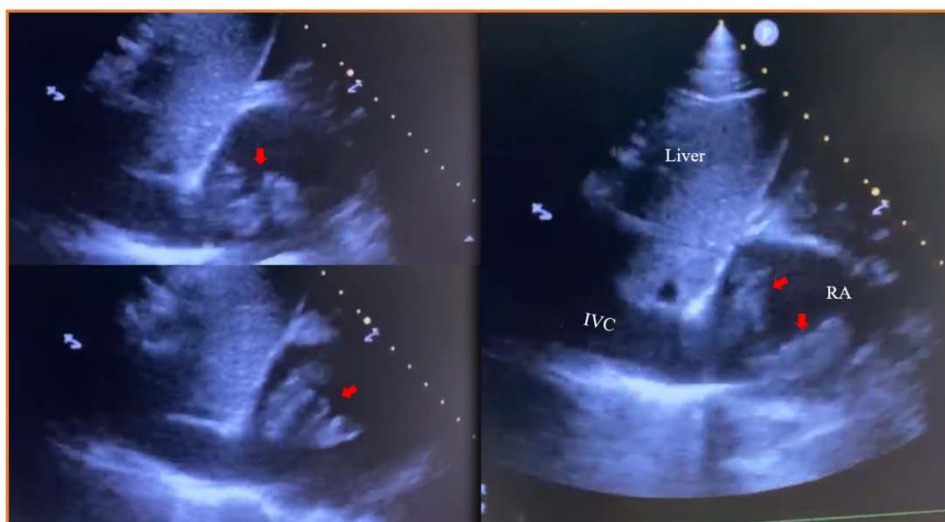


Figure 4. POCUS showing thrombus in transit in the right atrium (red arrow). (RA = right atrium, RV = right ventricle, IVC = inferior venacava)

Table 1. Arterial blood gas at the time of presentation

Variable	Value at presentation	Reference range
pH	7.25	7.31-7.41
PO2	56	30-50 mm Hg
PCO2	28	40-52 mm Hg
HCO3	19.2	23-28 mmol/L
Lactic acid	2.6	24-29 mmol/L
VSO2	85	>74%

Table 2. Complete blood count at the time of presentation

Variable	Value at presentation	Reference range
WBC	12.53	3.5-10.80 K/uL
Hemoglobin	16.2	14-18 g/dL
Platelets	420	130-400 K/uL
Neutrophils	84	40-74%
Lymphocytes	9.7	19-48%
Monocyte	3.4	0.0-9.0%
Procalcitonin	5.59	0.00-0.10 ng/ml

Table 3. Comprehensive metabolic panel at the time of presentation

Variable	Value at presentation	Reference range
Sodium	136-145 mmol/L	156
Potassium	3.5-5.1 mmol/L	5.4
Chlorine	98-107 mmol/L	120
CO2	21-31 mmol/L	18
Glucose	70-99 mg/dL	153
BUN	153 mg/dL	103
Creatinine	0.7-1.3 mg/dL	6.9
Total protein	6.0-8.3 g/dL	7.7
Albumin	3.5-5.7 g/dL	3.64
Alkaline Phosphatase	34-104 U/L	57
AST	13-39U/L	119
ALT	7-52U/L	54
Calcium	>60	8.8
Magnesium	1.9-2.7 mg/DL	3.9
Bilirubin	0.3-1.0 U/L	1.1
Lactate	140-271 U/L	1047
CK	30-223 u/L	8376 to 1957
C reactive protein	0-8 mg/L	142
Ferritin	16-294 ng/ml	2769.6
Lactic acid	0.5-1.6 mmol/L	2.6
Lactate dehydrogenase	140-271	1047
Troponin	<0.15	0.02-0.02-0.8

3. Discussion

Coronavirus disease 2019 (COVID-19), caused by SARS-CoV-2 virus presents with predominantly pulmonary manifestations however various systemic manifestations characterized by thromboembolism have been reported and can be potentially fatal. [1] The pathophysiology of pulmonary disease in COVID-19 is an entity distinct from ARDS, characterized by an initial viral pneumonitis, profound hypoxia in the absence of hypercapnia, symmetric alveolar infiltrates, and a remarkable responsiveness to prone positioning. Sustained inflammatory response from the host is suspected to be responsible for disease complications and its high rate of mortality. [2] The so-called cytokine storm resulting from this dysregulated inflammatory response can have devastating downstream effects, including multiple organ failure and coagulation dysfunction. An autopsy case series by Fox SE, et al. [3] showed the presence of small firm thrombi in the peripheral parenchyma of the lungs.

The presence of thrombi and endothelial injury has been widely observed in various reports and studies regarding COVID-19 infection. [4,5,6] Thromboembolic events have been reported in SARS as well, suggesting similar mechanistic properties to COVID 19. [7,8,9] A prospective study done in Wuhan, China showed the incidence of VTE in patients with severe coronavirus pneumonia to be 25% (20/81). [10] Another study of COVID 19 pneumonia patients admitted to intensive care units showed the incidence of VTE to be 31%, with pulmonary embolism accounting for a significant majority of those VTE cases. 5 Several case reports also corroborate the presence of pulmonary embolism in the setting of COVID-19 pneumonia. [11-14] These observations have led to the adoption of routine anticoagulation for critically ill patients with COVID-19 infection, mostly with low molecular weight heparin. [15,16]

To date, there are no clinical guidelines regarding the management of a thrombus in transit. [17,18] It is associated with poor prognosis and mortality, as it manifests itself in the critically ill. [19] Both percutaneous and surgical approaches may be consider for extraction of such thrombus in transit [20]. However, our patient was

too unstable for any of these considerations. The utilization of point of care ultrasound (POCUS) has gained traction as an adjunctive means of surveillance for the development of VTE in patients with COVID-19. [21] Despite CT angiography being the standard of care for pulmonary embolism, it poses the question of safely implementing the exam. At the very least, droplet precautions must be observed, and CT scan rooms must be thoroughly disinfected after each exam with a COVID positive patient as to minimize the risk of transmission. [22]

4. Conclusion

COVID-19 has significant pulmonary and systemic manifestations, including the development of venous thromboembolic events. We present a case of a thrombus in transit in a critically ill patient with COVID-19 pneumonia, where the initial diagnosis was made with POCUS. As obtaining CT exams has been logistically difficult due the infectivity and transmissibility of COVID-19, we contend that POCUS may have a role in the detection of venous thromboembolic events.

Acknowledgements

This work is supported, in part, by the efforts of Dr. Moro O. Salifu M.D., M.P.H., M.B.A., M.A.C.P., Professor and Chairman of Medicine through NIH Grant number S21MD012474.

References

- [1] Rothan HA, Byrareddy SN. The epidemiology and pathogenesis of coronavirus disease (COVID-19) outbreak. *J Autoimmun.* 2020; 109: 102433.
- [2] Guo YR, Cao QD, Hong ZS, et al. The origin, transmission and clinical therapies on coronavirus disease 2019 (COVID-19) outbreak - an update on the status. *Mil Med Res.* 2020; 7(1): 11.
- [3] Fox SE, Akmatbekov A, Harbert JL, Li G, Brown JQ, Vander Heide RS. Pulmonary and Cardiac Pathology in Covid-19: The First Autopsy Series from New Orleans. *medRxiv.* 2020: 2020.2004.2006.20050575.
- [4] Ciceri F, Beretta L, Scandroglio AM, et al. Microvascular COVID-19 lung vessels obstructive thromboinflammatory syndrome (MicroCLOTS): an atypical acute respiratory distress syndrome working hypothesis. *Crit Care Resusc.* 2020.
- [5] Klok FA, Kruip M, van der Meer NJM, et al. Incidence of thrombotic complications in critically ill ICU patients with COVID-19. *Thromb Res.* 2020.
- [6] Porfidi A, Pola R. Venous thromboembolism in COVID-19 patients. *J Thromb Haemost.* 2020.
- [7] Ng KHL, Wu AKL, Cheng VCC, et al. Pulmonary artery thrombosis in a patient with severe acute respiratory syndrome. *Postgrad Med J.* 2005; 81(956): e3-e3.
- [8] Tsang KW, Ooi GC, Ho PL. Diagnosis and pharmacotherapy of severe acute respiratory syndrome: what have we learnt? *European Respiratory Journal.* 2004; 24(6): 1025.
- [9] Xiang-hua Y, Le-min W, Ai-bin L, et al. Severe Acute Respiratory Syndrome and Venous Thromboembolism in Multiple Organs. *American Journal of Respiratory and Critical Care Medicine.* 2010; 182(3): 436-437.
- [10] Cui S, Chen S, Li X, Liu S, Wang F. Prevalence of venous thromboembolism in patients with severe novel coronavirus pneumonia. *Journal of Thrombosis and Haemostasis.* 2020; n/a(n/a).
- [11] Danzi GB, Loffi M, Galeazzi G, Gherbesi E. Acute pulmonary embolism and COVID-19 pneumonia: a random association? *Eur Heart J.* 2020.
- [12] Marongiu F, Grandone E, Barcellona D. Pulmonary thrombosis in 2019-nCoV pneumonia? *J Thromb Haemost.* 2020.
- [13] Casey K, Itean A, Nicolini R, Auten J. COVID-19 pneumonia with hemoptysis: Acute segmental pulmonary emboli associated with novel coronavirus infection. *Am J Emerg Med.* 2020.
- [14] Xie Y, Wang X, Yang P, Zhang S. COVID-19 Complicated by Acute Pulmonary Embolism. *Radiology: Cardiothoracic Imaging.* 2020; 2(2): e200067.
- [15] Tang N, Bai H, Chen X, Gong J, Li D, Sun Z. Anticoagulant treatment is associated with decreased mortality in severe coronavirus disease 2019 patients with coagulopathy. *J Thromb Haemost.* 2020.
- [16] Ranucci M, Ballotta A, Di Dedda U, et al. The procoagulant pattern of patients with COVID-19 acute respiratory distress syndrome. *J Thromb Haemost.* 2020.
- [17] Agarwal V, Nalluri N, Shariff MA, et al. Large embolus in transit - an unresolved therapeutic dilemma (case report and review of literature). *Heart Lung.* 2014; 43(2): 152-154.
- [18] Kahl N, Gabriel C, Lahham S, Thompson M, Hoonpongsimanont W. Point-of-care Ultrasound Diagnosis of Pulmonary Embolism with Thrombus in Transit. *Clin Pract Cases Emerg Med.* 2019; 3(1): 11-12.
- [19] Kariyanna PT, Celenza-Salvatore J, Jayarangaiah A, Punnakudiyil GJ, McFarlane IM. A Case of Thrombus in Transit: Role of POCUS in Early Diagnosis of Pulmonary Thromboembolism. *Am J Med Case Rep.* 2020; 8(2): 67-69.
- [20] Sabbagh E, Elzanaty AM, Alhourani O, Sheikh M. "Clot in Transit": Percutaneous or Surgical Approach?.
- [21] Sikachi R, Agrawal A. Whole body point of care ultrasound for COVID-19: a multi-system approach to a multi-system disease. *Anaesthesia.* 2020.
- [22] Hope MD, Raptis CA, Henry TS. Chest Computed Tomography for Detection of Coronavirus Disease 2019 (COVID-19): Don't Rush the Science. *Annals of Internal Medicine.* 2020.

