

Dyshidrotic Eczema Associated with Contraceptive Tubal Occlusion Device

Amandeep S Kataria^{1*}, Hemadhanvi Chagarlamudi¹, Hanna Lateef², Benjamin J Farley¹,
Aazim Arif¹, Tien-Anh N. Tran³, Farooq Lateef^{1,2}

¹Florida State University College of Medicine, Tallahassee, FL, U.S.A.

²Orlando Dermatology, Orlando, FL, U.S.A.

³AdventHealth Orlando, Department of Pathology, Orlando, FL, U.S.A.

*Corresponding author: amanskataria@gmail.com

Received March 02, 2020; Revised April 11, 2020; Accepted April 19, 2020

Abstract Nickel-related hypersensitivity reactions associated with the Essure micro-insert (Contraceptive Tubal Occlusion Device and Delivery System) are extremely rare, with only four reports in the current literature. We present a case of a 37-year-old woman who presented to our clinic for initial dermatologic evaluation of dermatitis localized to both hands three years after device placement. A diagnosis of dyshidrotic eczema, classically associated with systemic nickel exposure, was made after careful clinical and histopathologic evaluation. The micro-insert contraceptive device was suspected as the cause given our patient's self-reported history of nickel allergy, which was further supported by positive patch test results. Currently, our patient has seen significant improvement in her condition with topical steroids and occasional intralesional steroid injections. This case represents a diagnostic challenge given the presentation of a seemingly localized dermatitis secondary to systemic nickel exposure from a distant source. In addition, the delayed development of our patient's rash posed a clinical challenge in drawing a causal relationship between device placement and her allergic reaction. Practitioners should be cognizant of eliciting a history of implanted devices (plates, screws, implants, endovascular prostheses etc.) for all patients, even if the allergic reaction is seemingly localized such as dyshidrotic eczema.

Keywords: eczema, dermatitis, contraceptive device, contraception, tubal occlusion device

Cite This Article: Amandeep S Kataria, Hemadhanvi Chagarlamudi, Hanna Lateef, Benjamin J Farley, Aazim Arif, Tien-Anh N. Tran, and Farooq Lateef, "Dyshidrotic Eczema Associated with Contraceptive Tubal Occlusion Device." *American Journal of Medical Case Reports*, vol. 8, no. 7 (2020): 189-191. doi: 10.12691/ajmcr-8-7-8.

1. Introduction

The Contraceptive Tubal Occlusion Device and Delivery System micro-insert device, is a hysteroscopically inserted sterilization device placed in the proximal portion of each fallopian tube. It consists of an inner coil of polyethylene terephthalate (PET) fibers, which induce a fibrotic response resulting in irreversible tubal occlusion, and an anchoring outer coil of nitinol. Nitinol is a metal alloy composed of nickel (56%) and titanium (44%) [1]. Uncommonly, systemic exposure to nickel, via oral ingestion or implantable devices, may cause dyshidrotic dermatitis. Dyshidrotic dermatitis is a cutaneous manifestation of systemic contact dermatitis (SCD) or systemically reactivated allergic contact dermatitis (ACD) [2].

Episodes of acute dyshidrotic dermatitis often start with pruritus followed by a sudden eruption of intensely pruritic, deep-seated vesicles or bullae on the palms, lateral and dorsal aspects of the fingers or soles. Chronic exposure may result in lichenification, scaling patches or plaques with fissures [3]. Systemic re-exposure to nickel

in individuals previously sensitized through skin contact is a known predisposing factor.

Nickel-related hypersensitivity reactions to the Contraceptive Tubal Occlusion Device and Delivery System micro-insert are extremely rare, with a reported incidence of 0.004%, according to the manufacturer [4]. The possibility of nickel-related hypersensitivity reaction secondary to the nickel component has been suggested in only four previous case reports worldwide [Table 1] [4,5,6,7]. We present the first case of nickel-induced dyshidrotic eczema in a patient with the Contraceptive Tubal Occlusion Device and Delivery System micro-insert.

2. Case Presentation

A 38-year-old woman, gravida 4, para 4, who underwent uncomplicated bilateral Contraceptive Tubal Occlusion Device and Delivery System placement three years prior. She reported spontaneously development of pruritic vesicles and blisters on the index and middle finger of her right hand and both palms. Contact dermatitis was diagnosed clinically, and she was treated empirically

with oral steroids. While oral steroids offered temporary symptomatic relief and mild improvement of the rash, she returned to the clinic several months later with a more

widespread eruption [Figure 1 & Figure 2]. At this time, she was referred to a dermatology clinic for further evaluation.

Table 1. Cases reported in the literature of nickel-related hypersensitivity reaction after Contraceptive Tubal Occlusion Device and Delivery System micro-insert placement.

| Case | Age | Patch test confirmed nickel allergy? | Clinical manifestations | Time elapsed from device insertion to clinical manifestations | Technique of device removal | Symptom resolution? |
|-------------------|-----|--------------------------------------|--|---|---|---------------------|
| Lane et al [4] | 27 | Yes | Intermittent pleomorphic, pruritic, urticarial, maculopapular rash over the pelvis, neck, axilla, and facial edema. | 2 weeks | Laparoscopic salpingectomy | Yes |
| Bibas et al [5] | 40 | Yes | Severe anogenital pruritus, generalized erythematous maculopapular eruption in genital and flexural areas. | 3 weeks | Laparoscopic salpingectomy | Yes |
| Al-Safi et al [6] | 27 | No | Generalized pruritus with no visible rash and intermittent nausea. | 3 days | Hysteroscopic device removal | Yes |
| Baltuset al [7] | 38 | Yes | Pruritic, urticarial, maculopapular rash mainly in flexural regions, face, and abdomen; angioedema on the face, neck and axilla, to the extent that her usual undergarments did not fit. | 4 years | Laparoscopic salpingectomy | No* |
| Kataria et al | 35 | Yes | Vesicles and blisters localized to both hands | 3 years | No device removal Only steroid treatment | Partial |

*Patient underwent subsequent total laparoscopic hysterectomy followed by complete symptom resolution several months after her initial procedure which failed to relieve her symptoms.

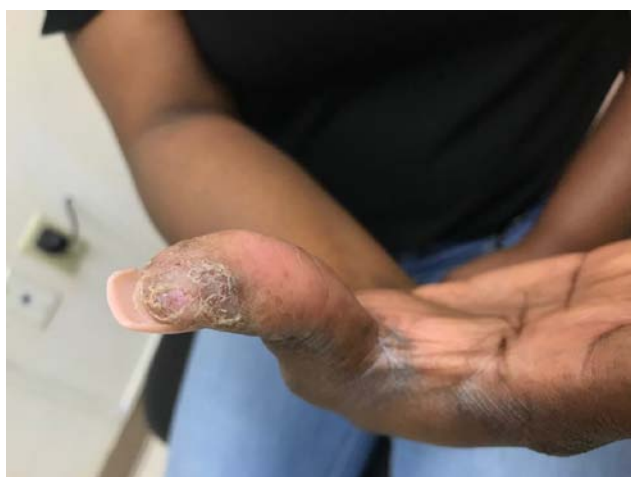

Figure 1. Patient’s right thumb showing subacute and chronic changes representing ruptured bullae, desquamation, and thickened superficial crusts in a characteristic distribution of dyshidrotic dermatitis

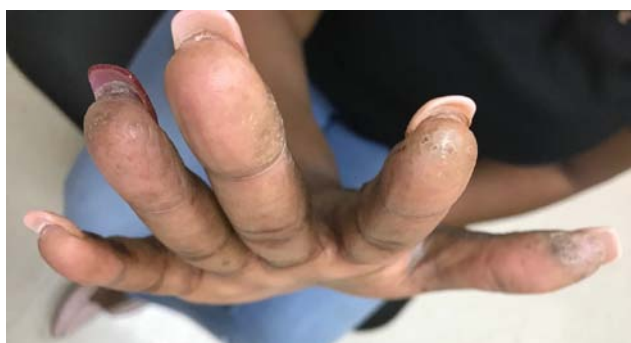

Figure 2. Patient’s right hand showing chronic changes along lateral aspects of fingers, and fingertips

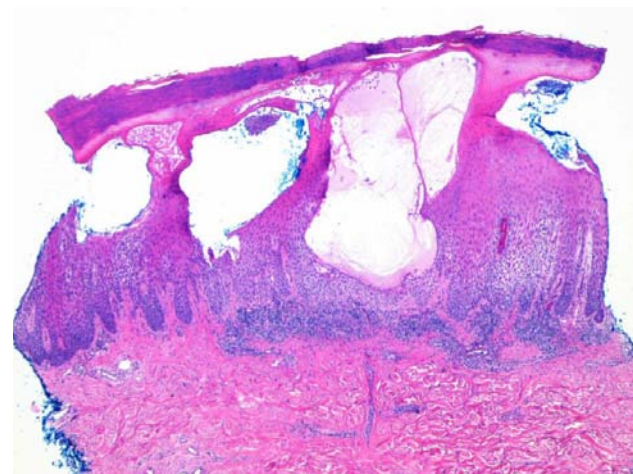


Figure 3. Right thumb biopsy sample, high power. Intraepidermal spongiotic vesicles, intercellular edema, marked lymphocytic and eosinophilic dermal infiltrates, hyperkeratosis, and parakeratosis consistent with subacute spongiotic dermatitis

Allergen patch test results revealed a marked positive reaction to nickel (2-3+). On further questioning, she reported a long-standing clinical history of nickel allergy, particularly to jewelry. However, she denied any recent contact with such items. Skin biopsy of the right thumb [Figure 3] showed histopathological changes consistent with subacute spongiotic dermatitis, confirming the diagnosis of dyshidrotic dermatitis. Since then, she has followed a chronic-relapsing clinical course. While super-high potency topical steroids are the mainstay of treatment for our patient, she occasionally receives intralesional steroid injections to abate moderate to severe acute flare-ups.

Unfortunately, no relationship was drawn between her clinical condition and the Contraceptive Tubal Occlusion Device and Delivery System at initial presentation, which delayed diagnosis. It was not until her dermatologic evaluation in our clinic that a relationship was drawn between her lesions and the intrauterine implant.

3. Discussion

To date, only 4 reports of nickel-related hypersensitivity reactions associated with the Contraceptive Tubal Occlusion Device and Delivery System micro-insert system have been described, which represents a diagnostic challenge since clinical manifestations and time course are highly variable between individuals. Clinical manifestations ranging from generalized pruritus with no visible rash to generalized urticaria and angioedema have been reported in the literature [4,5,6,7]. Interestingly, while the patients in all previously reported cases presented with either generalized pruritus without a definitive rash [6] or widespread rash [4,6,7], we document the first case of a seemingly localized rash as an allergic reaction to the Contraceptive Tubal Occlusion Device and Delivery System device. This is significantly more clinically challenging to diagnose as one would suspect direct allergen contact as the cause of our patient's localized dermatitis rather than systemic exposure from a distant source. In previously reported cases, the majority of patients presented within the first three weeks after device placement [4,5,6]. Our case is unique given the presentation of a localized rash secondary to systemic nickel exposure from an Contraceptive Tubal Occlusion Device and Delivery System device and the delayed onset of clinical manifestations of three years.

In recent years, the Contraceptive Tubal Occlusion Device and Delivery System was removed from the market due to increasing reports of adverse events [8]. Studies have not successfully demonstrated a causal

relationship between nickel sensitization and device placement. In light of unconvincing evidence, a known history of nickel allergy was removed from the original list of contraindications for device insertion [9]. Although device removal in asymptomatic patients with well-functioning devices is not indicated, current guidelines suggest a risk-stratified approach for patients with self-reported histories of dermatologic reactions to metal [10].

References

- [1] Zurawin RK, Zurawin JL. Adverse events due to suspected nickel hypersensitivity in patients with Essure micro-inserts. *J Minim Invasive Gynecol.* 2011 Jul-Aug; 18(4): 475-82.
- [2] Nishizawa A. Dyshidrotic Dermatitis and Its Relationship to Metal Allergy. *Curr Probl Dermatol.* 2016; 51: 80-5.
- [3] Wollina U. Pompholyx: a review of clinical features, differential diagnosis, and management. *Am J Clin Dermatol.* 2010; 11(5): 305-14.
- [4] Lane A, Tyson A, Thurston E. Providing Re-Essurance to the Nickel-Allergic Patient Considering Hysteroscopic Sterilization. *J Minim Invasive Gynecol.* 2016 Jan; 23(1): 126-9.
- [5] Bibas N, Lassere J, Paul C, Aquilina C, Giordano-Labadie F. Nickel-induced systemic contact dermatitis and intratubal implants: the baboon syndrome revisited. *Dermatitis.* 2013 Jan-Feb; 24(1): 35-6.
- [6] Al-Safi Z, Shavell VI, Katz LE, Berman JM. Nickel hypersensitivity associated with an intratubal microinsert system. *Obstet Gynecol.* 2011 Feb; 117 (2 Pt 2): 461-2.
- [7] Baltus T, Brown J, Mahmoud I. Delayed systemic allergic dermatitis following Essure insert: A case report. *Case Rep Womens Health.* 2018 Oct; 20: e00075.
- [8] U.S. Food and Drug Administration, FDA Activities: Essure, <https://www.fda.gov/medical-devices/Essure-permanent-birth-control/fda-activities-Essure>
- [9] Lessard CR, Hopkins MR. Efficacy, safety, and patient acceptability of the Essure procedure. *Patient Prefer Adherence.* 2011; 5: 207-212. Published 2011 Apr 28.
- [10] Markel K, Brod B, Jacob SE. Letter to the Editor: Metal hypersensitivity reactions in the context of Essure™. *Case Rep Womens Health.* 2018 Oct; 20: e00087.

