

# Perinephric Abscess Superimposed on a Spontaneous Perinephric Hematoma

Antoine Egbe<sup>1\*</sup>, Chris Agyingi<sup>2</sup>, Hussein Gaith<sup>1</sup>, Khurram Arshad<sup>1</sup>,  
Ahmed Subahi<sup>1</sup>, Shahana Ishfaque<sup>3</sup>, Ahmed Abdelrahim<sup>1</sup>

<sup>1</sup>Internal Medicine, Corewell Health, Dearborn, United States

<sup>2</sup>Internal Medicine, Woodhull Medical Center, Brooklyn, New York

<sup>3</sup>Internal Medicine, Faisalabad Medical University, Faisalabad, Pakistan

\*Corresponding author: Antoine Egbe, [egbe205@yahoo.com](mailto:egbe205@yahoo.com)

Received July 01, 2023; Revised August 02, 2023; Accepted August 09, 2023

**Abstract** A spontaneous perinephric hematoma is a rare entity that frequently presents with flank pain. We present the case of a 44-year-old female who presented to the emergency department with severe left flank pain, and hypotension. Her initial investigations were remarkable for the presence of a left perinephric hematoma measuring up to 10.1 cm (about 3.98 in). Renal arteriography did not show any signs of active bleeding, hence a conservative approach of not intervening was the initial decision. The hemoglobin on arrival was 10.2 and it remained stable during her hospital stay. She was discharged home with a follow-up visit in 2 months for a repeat computed tomography scan of the abdomen. About 4 weeks after leaving the hospital, she presented again with excruciating flank pain which was managed with analgesics. The repeat CT scan of the abdomen/pelvis showed a stable hematoma of the same size, so once again no intervention was done. Unfortunately, she presented about 4 weeks later with a fever of 101 F, altered mental status, and severe respiratory distress. She had a significant leukocytosis of 37,000 and lactic acid was 15.5 mg/dl. A CT scan of the abdomen showed a left retroperitoneal fluid collection, measuring 16.3 x 19.5 x 25.8 cm which was a perinephric abscess. The fluid collection was drained percutaneously, and surgical cultures grew *E. coli*. Her blood culture was also positive for *E. coli*. She received antibiotic therapy for about a month. The patient's hospital stay lasted about a month with about 2 weeks of that stay being in the intensive care unit. The main takeaway point of this case report is the answer to whether conservative management is always the best treatment for a stable perinephric hematoma.

**Keywords:** *Perinephric abscess, Spontaneous perinephric hematoma, Wunderlich syndrome*

**Cite This Article:** Antoine Egbe, Chris Agyingi, Hussein Gaith, Khurram Arshad, Ahmed Subahi, Shahana Ishfaque, and Ahmed Abdelrahim, "Perinephric Abscess Superimposed on a Spontaneous Perinephric Hematoma." American Journal of Medical Case Reports, vol. 11, no. 8 (2023): 138-141. doi: 10.12691/ajmcr-11-8-2.

## 1. Introduction

Spontaneous renal hematomas are a rarity. They were first described by Carl Reinhold Wunderlich in 1856. Patients who experience this misfortune usually present with Lenk's triad which consists of acute flank or abdominal pain, a palpable flank mass, and hypovolemia [1].

The usual causes of renal hematoma include neoplasm in more than 61% of the patients with angiomyolipoma being the most likely neoplasm, closely followed by renal cell carcinoma. Other common causes include vasculitis like polyarteritis nodosa and kidney infections. We will now delve into the case presentation of a 44-year-old with spontaneous perinephric hematoma which was treated conservatively but later presented with a superinfection of the hematoma.

## 2. Case Presentation

A 44-year-old transgender female with a history of HIV, a Last CD4 count of 684, and viral load of < 20 copies/ml, hypertension, artery disease, and diastolic CHF presents to the office with complaints of left-sided flank pain. The pain was moderately severe sudden onset with radiation to the left lower quadrant of the abdomen. The patient denied any fever or chills or dysuria or hematuria. CT of the abdomen in the emergency department revealed the left kidney was severely abnormal with the presence of a left perinephric hematoma measuring up to 10.1 cm. (Figure 1)

Interventional radiology was consulted for possible angioembolization. However, since the patient remained hemodynamically stable, serum hemoglobin levels remained stable over the ensuing three days (10.2 --> 11.1 ---> 10.9). Moreover, the computed tomography angiography (CTA) of the abdomen/pelvis did not show any signs of active arterial extravasation, hence a decision was made to watch the patient closely. The patient was follow-up outpatient for a repeat CTA abdomen/pelvis in a couple of months.

The evolution of her clinical course was marked by a presentation to the ED a month later with complaints of worsening left lower quadrant pain (LLQ). She was hemodynamically stable, and the CTA abdomen showed a large left subcapsular renal hematoma (Figure 2) without any evidence of active arterial extravasation. She was

treated conservatively with analgesics because the hematoma looked stable and serum hemoglobin remained stable. Urology was consulted and they cleared the patient for discharge with no further treatment apart from pain management.

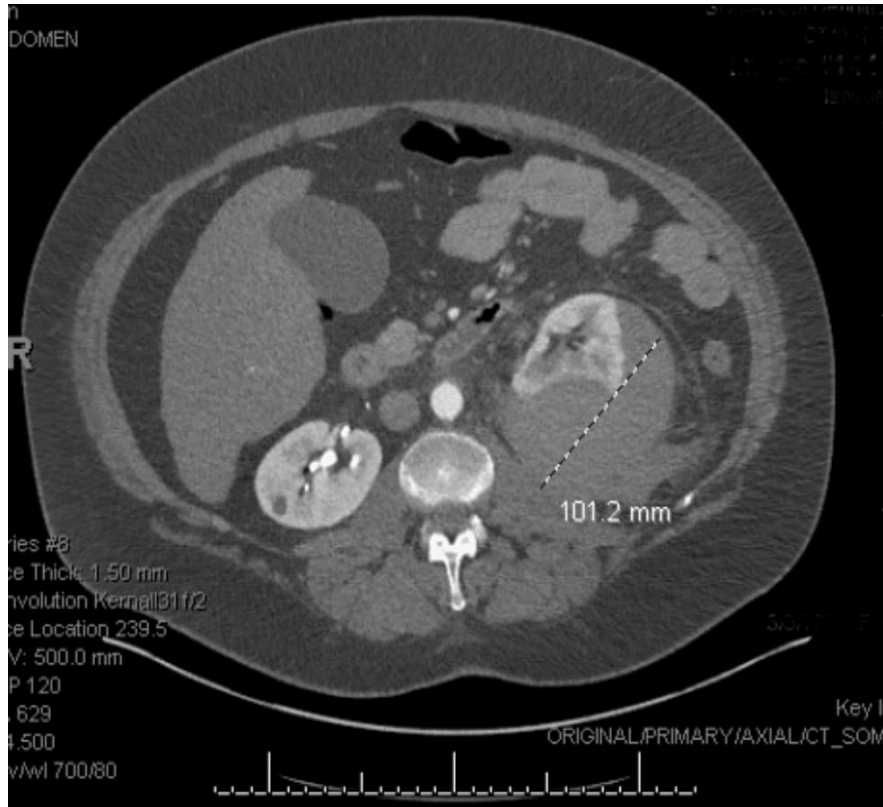
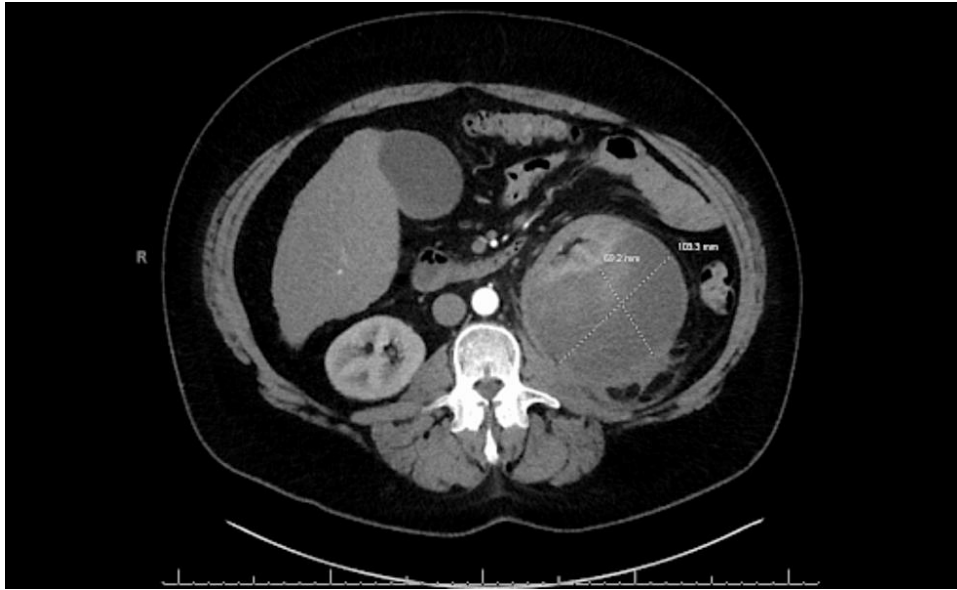


Figure 1. Left Perinephric Hematoma measuring up to 10.1 cm (about 3.98 in)

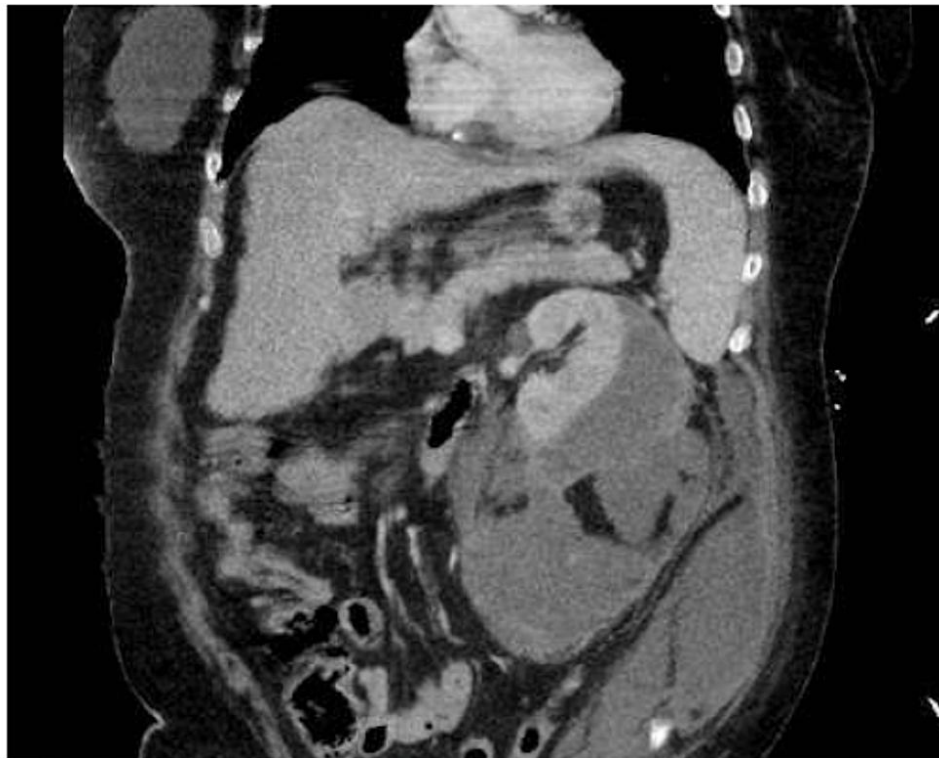
Initial labs revealed:

Table 1. Composite of significant laboratory findings on patient’s admission to the hospital

Hemoglobin	10.2	Sodium	134	Albumin	3.6 g/dL	Total Bilirubin	1.4 mg/dl
Glucose	205	Potassium	4.0	Globulin	5.5g/dl	Lactic acid	2.1
BUN	10	Chloride	99				
Creatinine	1.33	HCO <sub>3</sub> <sup>-</sup>	22	Alkaline phosphatase	92U/L		
eGFR	51 ml/min	Anion Gap	13	Aspartate Aminotransferase (AST)	26 U/L		
Calcium	9.6	Total Protein	9.1	Alanine Aminotransferase (ALT)	13U/L		



**Figure 2.** Stable left perinephric hematoma measuring up to 10.3 cm (about 4.06 in) x 6.9cm (about 2.72 in)



**Figure 3.** CT Abdomen/ pelvis showing a large left retroperitoneal fluid collection, measuring 16.3 x 19.5 x 25.8 cm

Interestingly, she presented again a month later to the emergency room with altered mentation and respiratory distress. Upon arrival, she was hypoxic, hyperthermic (temperature of 101F), white blood cell count was 37000, and lactic acid was 15.5. Supplemental oxygen was provided, and a sepsis workup was initiated. Due to severe metabolic acidosis and increased work of breathing, the patient was later intubated.

Other pertinent positive workups include; the CT abdomen and pelvis which showed a marked increase in the size of the left retroperitoneal fluid collection (Figure 3). It measured 16.3 x 19.5 x 25.8 cm (about 10.16 in), and it looked like an abscess. Her blood culture was positive for *E. coli*.

Management composed of CT-guided percutaneous drainage of the purulent retroperitoneal fluid collection and antibiotic therapy. The surgical cultures of the fluid collection grew *E. coli*. The percutaneous drainage catheters were left in place.

By Day 4 of hospitalization, she was able to support a spontaneous breathing trial and she was eventually extubated on Day 5 of hospitalization.

On Day 23 post-admission when blood cultures had remained consistently negative and multiple repeat CT scans of the abdomen and pelvis had shown resolution of the perinephric abscesses, only then was she discharged to a rehabilitation facility with plans for additional follow-up radiologic imaging in the outpatient setting.

### 3. Discussion

Wunderlich syndrome also known as a spontaneous perinephric hematoma was first described in 1856. However, thousands of years since its first description there is no clear consensus in the medical world regarding the management of spontaneous perinephric hematomas [2].

Spontaneous perinephric hematoma (SPH) is a rare complication that can occur in patients without any history of trauma or surgery. It may present with flank pain, hematuria, and a palpable mass. Conservative management with close monitoring of vital signs and serial imaging is the initial approach. However other methods of approach to the management of SPH have been proposed. Back in 1988, Kendall et al. [3], proposed that in patients with idiopathic spontaneous renal bleeding and a normal contralateral kidney, radical nephrectomy is recommended because of the high occurrence of undetectable tiny tumors in this patient population. Furthermore, Zhou Shen et al [4] 2014 published a case series of 20 patients with subcapsular hematomas which were managed with percutaneous drainage and subsequent urokinase injections. There are other case reports on the utilization of selective arterial embolization to manage spontaneous perinephric hematoma in a hemodynamically unstable patient.

The management of spontaneous perinephric hematomas remains a puzzling issue. In our case report, a conservatory approach to the management of the SPH led to the formation of a perinephric abscess. We strongly believe the decision to pursue conservative management should be made on a patient-patient basis. Maybe, in patients who have multiple comorbidities and are immunocompromised, it will be prudent to always drain the perinephric hematoma regardless of the hemodynamic status of the patient.

One of the feared complications of a spontaneous perinephric hematoma is the formation of a perinephric abscess. The most common causative agents for perinephric abscesses are E. Coli (44%), Klebsiella (28%), and Proteus species. In our case, E. coli was the causative bug, and it was managed with ceftriaxone and yielded excellent results. The treatment of perinephric abscess usually involves antibiotics and drainage of the abscess.

Empiric antibiotic therapy should be started as soon as possible, and the choice of antibiotics should be based on the suspected causative agent and the patient's clinical condition. Once the culture results become available, the antibiotic regimen can be adjusted accordingly. Drainage of the abscess can be performed percutaneously or surgically, depending on the size and location of the abscess.

### 4. Conclusions

Spontaneous perinephric hematomas are rare. They present with flank pain, nausea, vomiting, and hypovolemic shock. They can be confused for kidney stones and appendicitis. They are frequently caused by tumors like angiomyolipoma and vascular diseases like PAN. There is no consensus on management at this point. However, it is worth noting that conservative management can be complicated by superinfection of the perinephric hematoma leading to a perinephric abscess, which usually presents with a picture of septic shock. The most common bug found in perinephric abscesses is E. coli. We believe patients with immunocompromising conditions like HIV who present with SPH should not be managed conservatively.

### References

- [1] Antonescu O, Duhamel M, Di Giacinto B, Spain J. Spontaneous Renal Hemorrhage: A Case Report and Clinical Protocol. *Cureus*. 2021 Jun 9; 13(6): e15547.
- [2] Medda M, Picozzi SC, Bozzini G, Carmignani L. Wunderlich's syndrome and hemorrhagic shock. *J Emerg Trauma Shock*. 2009 Sep; 2(3): 203-5.
- [3] Kendall AR, Senay BA, Coll ME. Spontaneous subcapsular renal hematoma: diagnosis and management. *J Urol*. 1988 Feb; 139(2): 246-50.
- [4] Shen Z, He W, Liu D, Pan F, Li W, Han X, Li B. Novel technique for the treatment of large subcapsular renal hematoma: combined use of percutaneous drainage and urokinase injection. *Int Urol Nephrol*. 2014 Sep; 46(9): 1751-5.
- [5] Lee BE, Seol HY, Kim TK, Seong EY, Song SH, Lee DW, Lee SB, Kwak IS. Recent clinical overview of renal and perirenal abscesses in 56 consecutive cases. *Korean J Intern Med*. 2008 Sep; 23(3): 140-8.

