

# Left Anterior Mediastinal Lipoma - A Case Report

Prince Adu Amoako<sup>1,\*</sup>, Eugene V Vivitsky<sup>2</sup>

<sup>1</sup>Department of General Surgery, Trumbull Regional Medical Center, Warren OH

<sup>2</sup>Department of Thoracic Surgery, Trumbull Regional medical Center, Warren OH

\*Corresponding author: Princeam@auamed.net

Received April 11, 2022; Revised May 16, 2022; Accepted May 27, 2022

**Abstract Background:** Anterior Mediastinal tumors include but not limited to thymomas, terrible lymphomas, thyroid tumors, malignant germ cell tumors and teratomas. Anterior mediastinal lipomas remain exceedingly rare benign tumors and account for less than 2-5% of all lung tumor cases. These tumors can mimic malignant lung tumors and can present with but not limited to chest pain upon coughing, chronic shortness of breath, fever, night sweats and hoarseness, while some patients do not get any symptoms at all. **Case Presentation:** We present a 54-year-old Caucasian female who came in with concerns of an anterior mediastinal mass that was found on a routine lung cancer screening imaging that was ordered due to her long-standing history of tobacco smoking. CT (Computed Tomography) imaging done during that time confirmed the anterior mediastinal mass. The mass was also visualized and appreciated on a follow up PET (Positron Emission Tomography) scan and showed no signs of metastasis. Upon presentation months later, a left video assisted thoracoscopic surgery was done to visualize the mass and to retrieve a sample of the mass for biopsy. The specimen demonstrated segments of benign adipose tissue with patchy stromal hemorrhage and small portions of incorporated brown fat was seen, confirming the diagnosis of a left anterior mediastinal lipoma. **Conclusion:** Anterior mediastinal lipomas are exceedingly rare and only a few cases have been reported in the United States according to the American Cancer Society. The etiology of this rare condition remains unclear. These masses can resemble malignant lung neoplasms in presentation and on imaging. A minimally invasive video assisted thoracoscopic surgery can be done to retrieve a sample of the mass for biopsy to confirm the diagnosis. Surgical interventions like resection can be curative. Small size lipomas do not usually require surgical interventions until the mass size becomes appreciable.

**Keywords:** anterior mediastinal mass, benign lung tumors, Video-assisted thoracic surgery (VATS), thoracic lipomas

**Cite This Article:** Prince Adu Amoako, and Eugene V Vivitsky, "Left Anterior Mediastinal Lipoma - A Case Report." *American Journal of Medical Case Reports*, vol. 10, no. 5 (2022): 163-166. doi: 10.12691/ajmcr-10-5-11.

## 1. Case Presentation

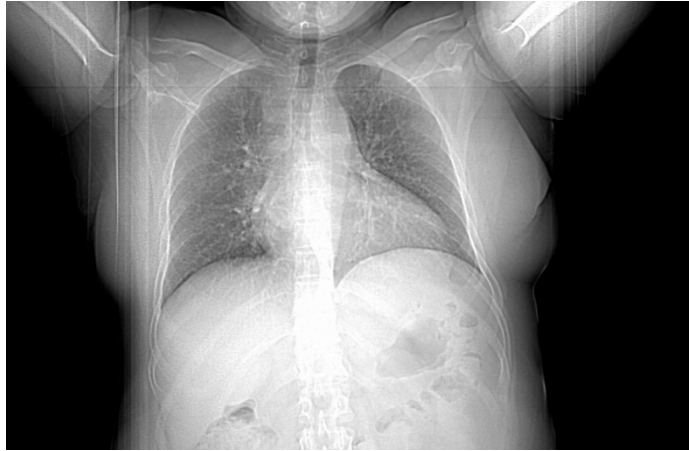A 54-year-old Caucasian female with a past medical history of Irritable bowel syndrome, bilateral oophorectomy, hysterectomy and uvulectomy presents with concerns of an anterior mediastinal mass discovered on routine chest imaging at her outpatient clinic. The Patient has had no symptoms during this time. She had a routine chest x-ray imaging done for a lung cancer screening due to her 22-pack year of tobacco smoking and found a mass in the anterior mediastinum which was followed by a chest CT and a PET scan. The mass was visualized and appreciated on CT scan. Her family history is significant for medullary and follicular thyroid cancer in her mother and esophageal cancer in her maternal grandmother. She denied any weight loss, shortness of breath, chest pain, hemoptysis, fevers, or night sweat. CBC, electrolytes, serum calcium and alkaline phosphatase at that time were all within normal limits.

A low dose CT scan of the chest showed a normal-sized heart and a normal aortic caliber. A lobulated mass in the anterior aspect of the mediastinum at and above the level of the aortic arch was found and it measured 26.1 x 21.1mm (about 0.83 in). No pleural fluid was present. CT also showed small dependent atelectasis in the lower lobes. A left video assisted thoracoscopic surgery was done. The gross specimen of a yellowish pink soft tissue with an aggregate weight of 0.6g was submitted for a histologic examination. A direct cytologic smear was prepared and showed fat tissue with no lymphocytes identified, therefore no tissue was submitted for flow cytometry study. The microscopic sections demonstrated segments of benign adipose tissue with patchy stromal hemorrhage. Small portions of incorporated brown fats were seen. A small portion of unremarkable skeletal muscle was also noted. Portions of thymic or lymphoid tissues were not seen and there was no evidence of malignancy. Thus, the diagnosis of anterior mediastinal lipoma was confirmed based on the histopathology. The patient does not present with any current concerning symptoms. No further

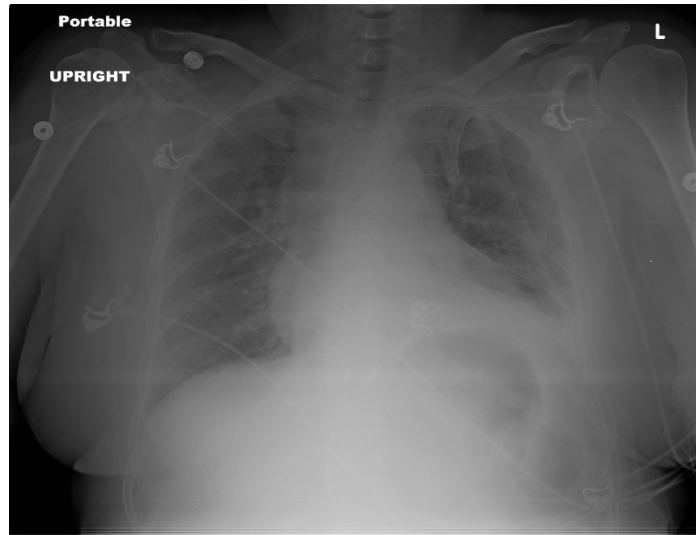
surgical intervention was done at this time. Patient was advised to schedule a follow up for close monitoring of

the mass in 6 months and 1 year and to report any worrisome symptoms that may arise.

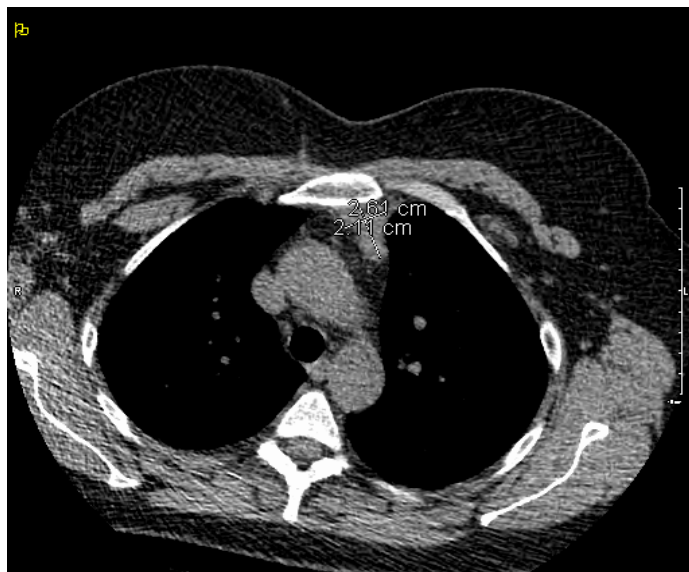## 2. Imaging



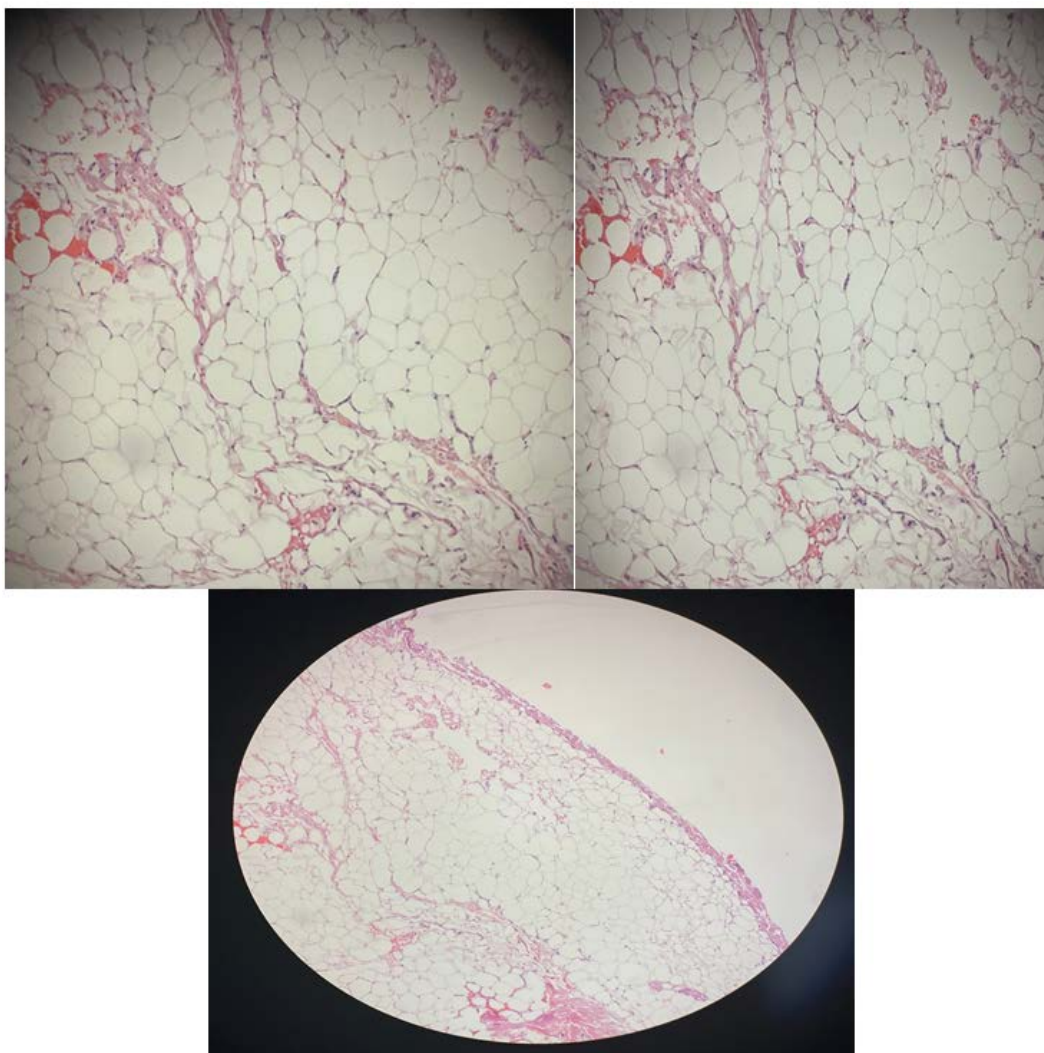
**Figure 1.** XR chest IV portable show a left anterior mediastinal nodule



**Figure 2.** Portable Chest Xray showing the nodule



**Figure 3.** Shows Low Dose Lung CT reveals 2.61 by 2.14 cm (about 0.84 in) anterior mediastinal mass



**Figure 4.** Histopathological slides of gross specimen take from the anterior mediastinal mass showing microscopic sections demonstrated segments of benign adipose tissue with patchy stromal hemorrhage using a 20x lens

### 3. Discussion

The mediastinum is the section of the thoracic cavity that lies between the pleural sacs of the lungs. It is divided into 4 major compartments: the superior, anterior, posterior and the middle compartments. The anterior compartment contains the thymus, veins and lymphatics and nerves from which neoplasms can arise. Most Cancers that arise from the anterior mediastinum are malignant neoplasms and can include thymomas, teratomas, terrible lymphomas and thyroid tumors [3]. Soft tissue neoplasms such as lipomas rarely occur in the anterior mediastinum and only a few cases have been reported so far. These benign adipose tissue neoplasms sometimes present weight loss, fever, shortness of breath, cough, and chest pain. CT imaging is highly specific in identifying anterior mediastinal masses [3].

Often, imaging studies alone is not enough to distinguish between benign and malignant anterior mediastinal masses. Further imaging and biopsy are required to distinguish between benign and malignant anterior mediastinal neoplasms. Video assisted thoracic surgery is a well-tolerated minimally invasive procedure that can be used to further visualize and remove parts of the mass for biopsy [4]. Small incisions are made within the ribs and a small

tube called a thoracoscope is inserted through. The tip of the scope has a camera that helps visualize the mediastinal mass and another tube is inserted to remove part of the mass. A portion of the tissue is then sent for histologic examination. Anterior mediastinal lipomas on histology would show no sign of lymphocytic cell activity and further flow cytometry is usually not required after that. Biopsy will show the presence of adipose tissues and no evidence of malignancy which will confirm the diagnosis.

In this case report, the patient's pathological reports of the gross specimen from her anterior mediastinal mass showed fat tissues with no lymphocytes identified, therefore no tissue was submitted for flow cytometry study. The microscopic sections demonstrated segments of benign adipose tissue with patchy stromal hemorrhage. Small portions of incorporated brown fats were also seen. A small portion of unremarkable skeletal muscle was also noted.

It is always important to follow up with an abnormal chest finding on imaging due to the mortality rate of lung cancer in the US whether symptoms are present or not. Lung cancer kills more patients than breast cancer, colon cancer, rectal cancer and prostate cancer combined. In 2011, 221000 new cases were reported and 157000 deaths in the same year [5].

## 4. Conclusion

Lipomas are very common benign tumors usually found within the subcutaneous parts of the body. Lipomas are rarely found in the thoracic cavity. Anterior mediastinal Lipomas are relatively rare and can be mistaken as a malignant lung tumor. Thoracic cavity lipomas and lung malignancies can have overlapping presenting symptoms. The etiology of anterior mediastinal lipomas is still unclear. Video assisted thoracic surgery biopsy is a minimally invasive procedure that can be used to visualize the mass and retrieve a portion for biopsy to further evaluation. In cases where the lipoma is not big enough to cause a compression of surrounding structures or cause any worrisome symptoms, surgical intervention can be postponed, and the lipoma can be observed.

## Conflict of Interest and Funding

The authors of this case report have not received any funding, gifts, or benefits whatsoever from conducting this report.

## Consent

The patient has given full verbal consent to author this report if her identifiers are not disclosed in the report.

## References

- [1] Gupta A, Palkar A, Narwal P, Kataria A. Mediastinal lipoma as a cause of dyspnea. *Respir Med Case Rep.* 2019; 27:100828. Published 2019 Mar 25.
- [2] Madan K, Agarwal R, Bal A, Gupta D. Bronchoscopy management of a rare benign endobronchial tumor. *Rev Port Pneumol.* 2012 Sep-Oct; 18(5): 251-4. Epub 2012 Mar 30. PMID: 22463875.
- [3] Society of Thoracic Surgeons. Mediastinal Tumors. (<https://ctsurgeypatients.org/lung-esophageal-and-other-chest-diseases/mediastinal-tumors>) Accessed 4/9/2019
- [4] omiyama N, Honda O, Tsubamoto M, Inoue A, Sumikawa H, Kuriyama K, Kusumoto M, Johkoh T, Nakamura H. Anterior mediastinal tumors: diagnostic accuracy of CT and MRI. *Eur J Radiol.* 2009 Feb; 69(2): 280-8. Epub 2007 Nov 26. PMID: 18023547.
- [5] Quadri S (author); Snow N (peer reviewer); Yu J (additional information). Lung Cancer. In Hopkins MA, Lynch TG (eds): Wise-MD. <http://wise-md.med.nyu.edu>, 2012.



© The Author(s) 2022. This article is an open access article distributed under the terms and conditions of the Creative Commons Attribution (CC BY) license (<http://creativecommons.org/licenses/by/4.0/>).