

A Case of Pediatric Myocarditis that was Initially Misdiagnosed as Cerebral Concussion

Soichiro Ota¹, Youichi Yanagawa^{1*}, Jun Yoshimoto², Tatsuya Kawasaki³

¹Department of Acute Critical Care Medicine, Juntendo Shizuoka Hospital, Izunokuni, Japan

²Department of Pediatric Cardiology, Shizuoka Children's Hospital, Shizuoka City, Shizuoka, Japan

³Department of Pediatric Critical Care, Shizuoka Children's Hospital, Shizuoka City, Shizuoka, Japan

*Corresponding author: yyanaga@juntendo.ac.jp

Received February 05, 2022; Revised March 07, 2022; Accepted March 15, 2022

Abstract A seven-year-old girl suddenly fell and became unconscious in her house. Her mother, who witnessed the fall called an ambulance. While waiting for the ambulance, she experienced generalized convulsions. The emergency medical technicians reported to the hospital that the patient had experienced cerebral concussion and immediate post-traumatic seizure. During transportation, she experienced generalized convulsions again. Electrocardiography (ECG) showed complete atrioventricular block without QRS complex during the generalized convulsions. On arrival, she regained consciousness. ECG revealed sinus tachycardia with left axis deviation and negative T wave at the I, aVL, V1-V3 leads. Cardiac echo showed good wall motion with a highly echoic epicardium. Head computed tomography revealed no specific findings. The main blood test results were increased cardiac enzyme and inflammatory reaction. The diagnosis was myocarditis and fatal arrhythmia followed by generalized convulsions and/or syncope, not cerebral concussion. She was transported to a children's hospital for advanced medical care. Her post-admission course was uneventful. Adenovirus was the causative virus of myocarditis. The present case suggests that the heart should be evaluated in addition to the brain when children experience a prolonged period of unconsciousness after a fall.

Keywords: cerebral concussion, myocarditis, fatal arrhythmia

Cite This Article: Soichiro Ota, Youichi Yanagawa, Jun Yoshimoto, and Tatsuya Kawasaki, "A Case of Pediatric Myocarditis that was Initially Misdiagnosed as Cerebral Concussion." *American Journal of Medical Case Reports*, vol. 10, no. 3 (2022): 64-67. doi: 10.12691/ajmcr-10-3-6.

1. Introduction

Children with myocarditis may present with various symptoms, ranging from mild flu-like symptoms to overt heart failure and shock, whereas children with pericarditis typically present with chest pain and fever [1,2,3]. The cornerstone of therapy for myocarditis includes aggressive supportive management of heart failure, as well as the administration of inotropes and antidysrhythmic medications, as indicated [1,2,3]. Children often require intensive care. We herein report a case of pediatric myocarditis in a patient who was initially misdiagnosed with cerebral concussion

2. Case Report

The patient was a seven-year-old girl who suddenly fell and became unconscious in her house. Her head contacted

the floor. Her mother, who witnessed the fall, called an ambulance. Her past history included febrile convulsion and her brother and sister had Kawasaki disease. While waiting for the ambulance, she experienced generalized convulsions for approximately 30 seconds. When the emergency medical technicians (EMTs) checked her, she was in drowsy state. When the EMTs requested accommodation at Juntendo Shizuoka Hospital, they reported she had consciousness disturbance due to cerebral concussion and immediate post-traumatic seizure. During transportation, she experienced generalized convulsions again. Electrocardiography (ECG) showed complete atrioventricular block without QRS complex (cardiac arrest) for over 10 seconds during the convulsions (Figure 1). When sinus rhythm with QRS complex returned spontaneously, the convulsions also stopped. On arrival, she regained consciousness. Her vital signs were as follows: Glasgow Coma Scale, E3V4M6; heart rate, 105 beats per minute; blood pressure, 92/61 mmHg; percutaneous oxygen saturation under room air, 100%.

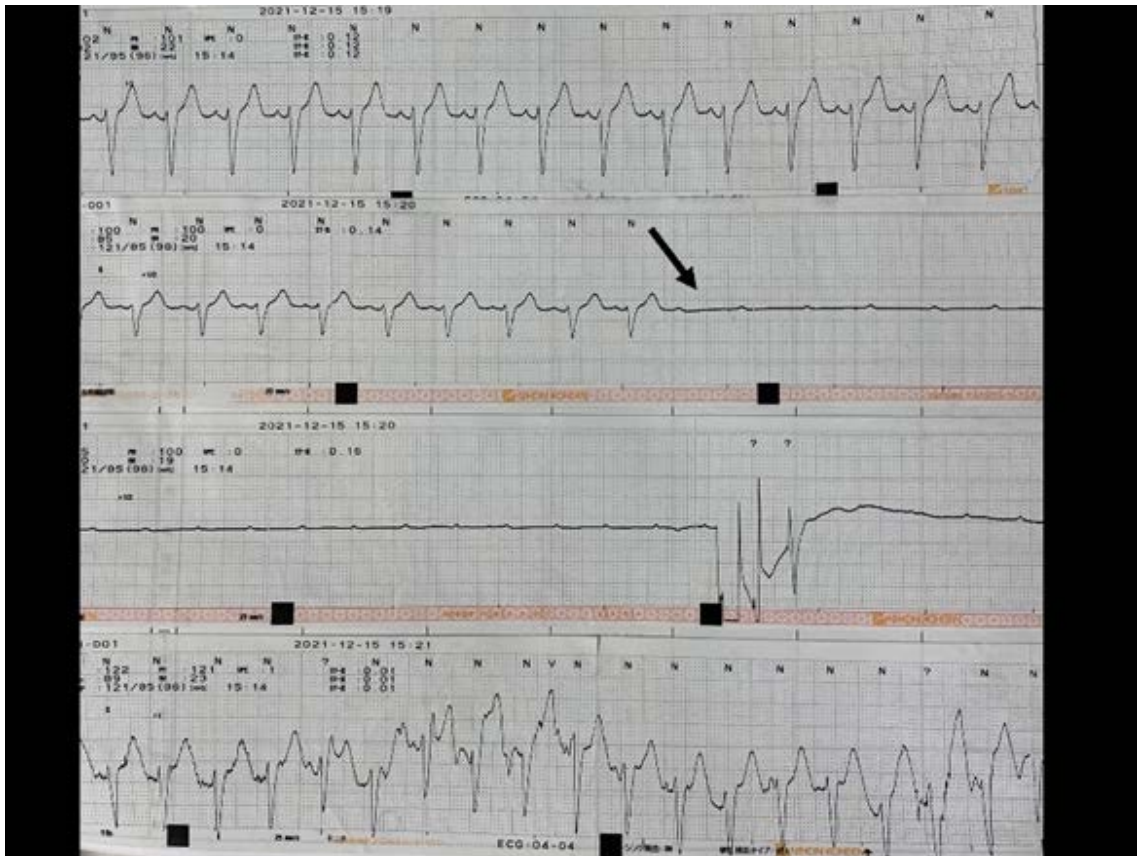


Figure 1. Electrocardiogram during transportation by ambulance

The electrocardiogram showed disappearance of the QRS complex after the p wave in lead II. During this fatal arrhythmia, the patient experienced generalized convulsions.

A physical examination revealed no specific findings. ECG revealed sinus tachycardia with left axis deviation and negative T wave at the I, aVL, V1-V3 leads ([Figure 2](#)).

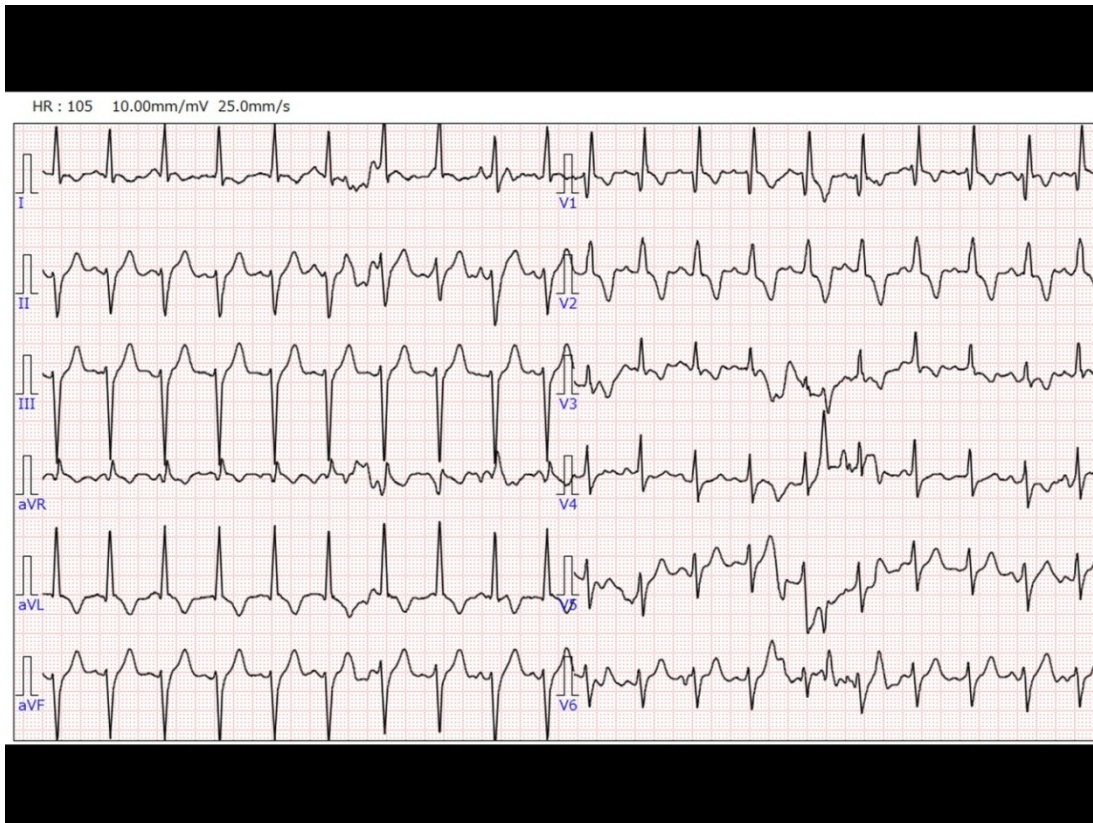


Figure 2. Electrocardiogram (ECG) on arrival

The electrocardiogram showed sinus tachycardia with ST depression on lead I, aVL, and V1-V3.

A venous gas analysis revealed the following: pH, 7.348; PCO₂, 48.7 mmHg; HCO₃⁻, 26.1 mmol/L; base excess, 0.5 mmol/L; lactate, 2.1 mmol/L. Cardiac echo showed good wall motion with a highly echoic epicardium (Figure 3).

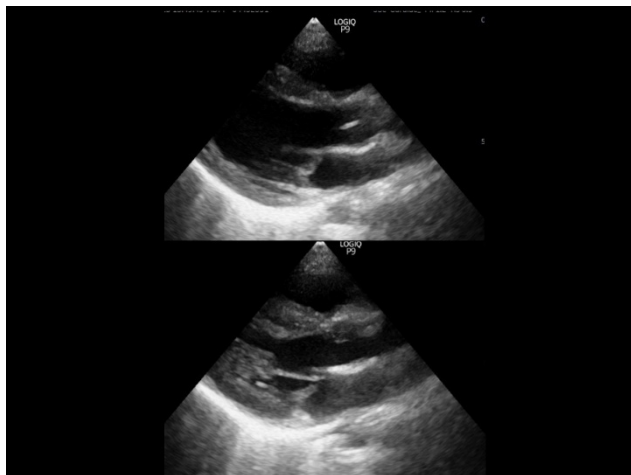


Figure 3. Cardiac echo on arrival (upper, diastolic; lower, systolic phase)

Cardiac echo showed good wall motion with a highly echoic epicardium.

Head computed tomography revealed no specific findings. The results of biochemical analyses of the blood on arrival are shown in Table 1. The main results were an increased cardiac enzyme level and an inflammatory reaction.

Table 1.

White blood cells	9500 / μ L
Hemoglobin	12.0 g/dL
Platelet	37.2 \times 10 ⁴ / μ L
Total protein	7.3 g/dL
Albumin	4.2 g /dL
Total bilirubin	0.6 mg/dL
Aspartate aminotransferase	47 IU/L
Alanine aminotransferase	8 IU/L
γ - glutamyltransferase	14 IU/L
Amylase	94 IU/L
Blood urea nitrogen	18.3 mg/dL
Creatinine	0.43 mg/dL
Creatine kinase	284 IU/L
Glucose	120 mg/dL
Sodium	140 mEq/L
potassium	3.9 mEq/L
Chloride	103 mEq/L
C-reactive protein	1.55 mg/dL
Prothrombin time	13.9 (11.9) seconds
Activated partial thromboplastin time	30.1 (27.1) seconds
Fibrinogen	431 mg/dL
Fibrinogen degradation products	1.6 μ g/mL

Based on the results of the examinations, she was diagnosed with myocarditis with fatal arrhythmia followed by generalized convulsions and/or syncope, rather than cerebral concussion with immediate post-traumatic seizure nor convulsion inducing fatal arrhythmia [4,5,6]. As it was considered that she might soon require percutaneous

cardiopulmonary support due to heart failure, she was transported to Shizuoka Children's Hospital [7]. After transportation, the results of cardiac magnetic resonance imaging were compatible with myocarditis. Until day 2, she showed a weakened cardiac systolic volume with bifascicular block on ECG. On day 3, her cardiac enzyme levels peaked without signs of heart failure. On day 5, bifascicular block improved to right bundle branch block. On day 11, she was discharged from the hospital on foot. Based on the results of the FilmArray Pneumonia Panel study (FAPP; bioMerieux, France), adenovirus was considered to be the causative virus of myocarditis in the present case [8].

3. Discussion

We presented a case of pediatric myocarditis that was initially misdiagnosed by EMTs as cerebral concussion with immediate post-traumatic seizure. A PubMed search was undertaken to identify articles using the key words "trauma", "myocarditis" and "child". However, we could not find any articles that demonstrated the induction of trauma by myocarditis or myocarditis initially misdiagnosed as head trauma. In adult cases, several studies have reported that preceding endogenous diseases resulted in the occurrence of trauma or accident [9-13]. Among children, the occurrence of sudden collapse induced by endogenous diseases was rare, except for convulsions or vasovagal syncope, which rarely induced head trauma [14,15]. In addition, traumatized children tend to only be evaluated for trauma, and not preceding endogenous diseases. This may explain why there have been no previous reports of trauma induced by myocarditis or myocarditis initially misdiagnosed as head trauma. Somers et al. reported the autopsy results of 22 pediatric drowning victims [16]. Among them, five cases had coexistent myocarditis. None of the patients had antecedent symptomatology suggestive of myocarditis. They concluded that the myocarditis was present in a significant proportion of drowning victims. The present case was not drowning, and head injuries due to falls are common in children [17]. At least, the present case suggests that the heart should be evaluated in addition to the brain when children experience a prolonged period of unconsciousness after a fall.

4. Conclusion

We presented a case of pediatric myocarditis that was initially misdiagnosed as cerebral concussion with immediate post-traumatic seizure. The heart should be evaluated in addition to the brain when children experience a prolonged period of unconsciousness after a fall.

Acknowledgements

This work was supported in part by a Grant-in-Aid for Special Research in Subsidies for ordinary expenses of

private schools from The Promotion and Mutual Aid Corporation for Private Schools of Japan.

References

- [1] Bergmann KR, Kharbanda A, Haveman L. Myocarditis And Pericarditis In The Pediatric Patient: Validated Management Strategies. *PediatrEmerg Med Pract.* 2015 Jul; 12(7): 1-22.
- [2] Dasgupta S, Iannucci G, Mao C, Clabby M, Oster ME. Myocarditis in the pediatric population: A review. *Congenit Heart Dis.* 2019 Sep; 14(5): 868-877.
- [3] Putschogel A, Auerbach S. Diagnosis, Evaluation, and Treatment of Myocarditis in Children. *Pediatr Clin North Am.* 2020 Oct; 67(5): 855-874.
- [4] Maqsood N, Laslett DB, Patil A, Basil A, Gannon MP, Whitman IR. The Longer the Block, the Harder You Fall: Extrinsic Idiopathic Atrioventricular Block Masquerading as Seizures. *JACC Case Rep.* 2021 Jun 9; 3(8): 1086-1090.
- [5] van der Lende M, Surges R, Sander JW, Thijs RD. Cardiac arrhythmias during or after epileptic seizures. *J Neurol Neurosurg Psychiatry.* 2016 Jan; 87(1): 69-74.
- [6] Rodrigues Tda R, Sternick EB, Moreira Mda C. Epilepsy or syncope? An analysis of 55 consecutive patients with loss of consciousness, convulsions, falls, and no EEG abnormalities. *Pacing Clin Electrophysiol.* 2010 Jul; 33(7): 804-13.
- [7] Inoue Y, Kaneko H, Yoshizawa Y, Morikawa A. Rescue of a child with fulminant myocarditis using percutaneous cardiopulmonary support. *PediatrCardiol.* 2000 Mar-Apr; 21(2): 158-60.
- [8] Babady NE. The FilmArray respiratory panel: an automated, broadly multiplexed molecular test for the rapid and accurate detection of respiratory pathogens. *Expert Rev Mol Diagn.* 2013 Nov; 13(8): 779-88.
- [9] Nagasawa H, Omori K, Takeuchi I, Jitsuiki K, Ohsaka H, Yanagawa Y. Clinical Significance of C-Reactive Protein in Patients with Trauma on Arrival. *Juntendo Medical Journal* 2019. 65 (5), 451-455.
- [10] Miao Q, Zhang YL, Miao QF, Yang XA, Zhang F, Yu YG, Li DR. Sudden Death from Ischemic Heart Disease While Driving: Cardiac Pathology, Clinical Characteristics, and Countermeasures. *Med Sci Monit.* 2021 Jan 26; 27: e929212.
- [11] Inamasu J, Nakatsukasa M, Tomiyasu K, Mayanagi K, Nishimoto M, Oshima T, Yoshii M, Miyatake S, Imai A. Stroke while driving: Frequency and association with automobile accidents. *Int J Stroke.* 2018 Apr; 13(3): 301-307.
- [12] Inamasu J, Hashizume K. Aortic dissection occurring while driving and road traffic accidents. *Am J Emerg Med.* 2019 Jul; 37(7):1374-1376.
- [13] Biffi WL, Ferkich A, Biffi SE, Dandan T. Syncope, "mechanical falls", and the trauma surgeon. *J Trauma Acute Care Surg.* 2020 Sep; 89(3): e64-e68.
- [14] Villafane J, Miller JR, Glickstein J, Johnson JN, Wagner J, Snyder CS, Filina T, Pomeroy SL, Sexson-Tejtel SK, Haxel C, Gottlieb J, Egthesady P, Chowdhury D. Loss of Consciousness in the Young Child. *Pediatr Cardiol.* 2021 Feb; 42(2): 234-254.
- [15] Eapen N, Kochar A, Lyttle MD, Phillips N, Cheek JA, Furyk J, Neutze J, Bressan S, Williams A, Hearps S, Oakley E, Dalziel SR, Borland ML, Babl FE; Paediatric Research in Emergency Departments International Collaborative (PREDICT). Seizure- and syncope-related head injuries in children: A prospective PREDICT cohort study. *Emerg Med Australas.* 2021 Aug; 33(4): 769-771.
- [16] Somers GR, Smith CR, Wilson GJ, Zielenska M, Tellier R, Taylor GP. Association of drowning and myocarditis in a pediatric population: an autopsy-based study. *Arch Pathol Lab Med.* 2005 Feb; 129(2): 205-9.
- [17] Yanagawa Y, Sakamoto T. Characteristics of pediatric trauma in an urban city in Japan. *Pediatr Emerg Care.* 2009 Sep; 25(9): 572-4.



© The Author(s) 2022. This article is an open access article distributed under the terms and conditions of the Creative Commons Attribution (CC BY) license (<http://creativecommons.org/licenses/by/4.0/>).