

Sarcoptic Mange Infestation in West Africa Dwarf Goat Herd in Ibadan, South West Nigeria

Falohun Olufarati Oludunsin^{1,*}, Sadiq Nurudeen Ayinde¹, Onyiche Emmanuel ThankGod¹,
Obebe Oluwasola Olaiya¹, Oke Philip Oladele²

¹Department of Veterinary Microbiology and Parasitology, University of Ibadan, Ibadan

²Department of Veterinary Parasitology and Entomology, College of Veterinary Medicine, University of Agriculture, Makurdi

*Corresponding author: farry4real2k@yahoo.com

Received January 27, 2015; Revised February 05, 2015; Accepted February 09, 2015

Abstract An adult, Female West Africa Dwarf goat, the only surviving from a local goat herd comprising 31 goats, all reported to be dead was presented to the Small ruminant ward of Veterinary Teaching Hospital, University of Ibadan, Ibadan, South West Nigeria. Clinical examination revealed generalized wrinkling and thickening of the skin with heavy crust formation on the abdomen, forehead, ear, the limbs, inter-digital spaces, mammary gland and inner thigh. Skin biopsy, skin scrapings, whole blood and serum samples were collected respectively for histopathology, ectoparasite identification, hematology and biochemistry. Histomorphometric studies were also conducted for tunnel measurement. Parasite sections, tunnels, orthokeratosis, exocytosis, folliculitis, scarring, hyperkeratosis, sero-cellular exudate, pustule and acanthosis were observed with histological studies while several *Sarcoptes scabiei* var *caprae* which have oval to round, dorsally convex tortoise-like body that is covered with spines and triangular scales with only the first two pairs of legs protruding beyond the body margin in both sexes were identified. There was severe anemia with very low PCV and erythrocyte count, leucocytosis, eosinophilia, hypoproteinemia, hypoalbuminemia and hypoglobulinaemia. Reduction in epidermal tunnel diameter ranges from 200 μm to 170 μm while tunnel height ranges from 220 μm to 180 μm . The goat died 15 days after presentation due to the fact that the goat was in the severe, advanced chronic stage of the disease which often terminate in mortality. It is very paramount to note that early diagnosis and treatment of Sarcoptic mange in goat should be made by a Veterinarian as a therapeutic efficacy of a combination of amitraz and ivermectin will provide an excellent result of complete recovery from generalized infestation of mange mite.

Keywords: *Sarcoptic mange, histomorphometrics, skin biopsy, haematology, Biochemistry, Nigeria*

Cite This Article: Falohun Olufarati Oludunsin, Sadiq Nurudeen Ayinde, Onyiche Emmanuel ThankGod, Obebe Oluwasola Olaiya, and Oke Philip Oladele, "Sarcoptic Mange Infestation in West Africa Dwarf Goat Herd in Ibadan, South West Nigeria." *World Journal of Agricultural Research*, vol. 3, no. 1 (2015): 24-27. doi: 10.12691/wjar-3-1-6.

1. Introduction

Sarcoptes scabiei is a highly contagious and the most notorious ectoparasite of goats and are responsible for great economic losses especially in humid area of West Africa [3,4]. These mites cause serious damage to the skin of the animal by burrowing and forming tunnels in the epidermis where they feed on tissue fluids and lay eggs which causes irritation and consequent scratching, leading to inflammation and exudation that forms crusts [2,13].

Clinical picture of Sarcoptic mange in goats includes intense pruritus, excoriation, papules, crust formation, hyperkeratosis, erythema, anemia, emaciation, cachexia, lethargy which usually leads to death in its chronic and final stage [1,10,15,22].

The disease has been reported to affect mainly the traditional goat herds, with the newly purchased animals known to serve as the main source of the contamination [4,11].

2. Case Report

A farmer presented an adult, female West Africa Dwarf goat to the Small ruminant ward of Veterinary Teaching Hospital, University of Ibadan, which was weak and emaciated with heavy crust formation and generalize hyperkeratosis on the body. He reported that he has a local goat herd located in Adaba village, Ido local government which comprised 31 goats, organized in a semi intensive system that was doing fine until a Doe suspected to be having skin problems was bought from a nearby village and introduced into the herd. He then observed about three weeks later that all 19 adult goats in the herd started showing strange signs of vigorous rubbing of body against pen wall and biting of skin while about a week later the remaining goats started showing similar signs. He observed complete loss of hair on some body parts of the goats and applied local treatment (Engine oil) which proved abortive before mortality set in about some weeks

later as all twelve young goats died the same day and the adults goats died in the space of two weeks after the goats have stopped feeding and lost weight drastically.

Deep skin scrapings from the edge of the lesion as described by Soulsby [23]. were collected from different lesion sites of the body (forehead, face, legs, abdomen, ear, inner aspect of thigh, inguinal region and tail) of the West African Dwarf goat and the scraped material was transferred to clean sample bottles. The sample was taken to the Veterinary Parasitology laboratory of the department of Veterinary Microbiology and Parasitology, University of Ibadan and parasitological identification of the mites was conducted as described by Soulsby [23]. 2.5-cm² skin scrapings were treated with 20 ml of 10% (KOH) solution for 5-10 min to disrupt the keratin Skin and digest necrotic tissues. This was then centrifuged at 1500 rpm for 5 min, and the supernatant was discarded and the sediment carefully mixed with saturated glucose solution. After 10 min the upper layer was then collected and examined under a stereoscopic microscope to determine the presence of mites. Identification of mites was carried out with the help of morphological characteristics as described by [24].

Deep Shaved Skin Biopsy was also performed as described by [17]. The skin biopsy was then put in 70% ethanol and taken to Veterinary Pathology laboratory for histopathology. The biopsies were processed, embedded in paraffin wax and sectioned at 5 µm prior to staining with haematoxylin and eosin stain and examined as indicated by [5].

Blood samples were collected from the jugular vein of the WAD goat into labeled sterile EDTA bottle for haematology as described by [21]. and also 5 mls was collected into plain vacutainer tube for serum biochemistry over a period of two weeks.

Histomorphometric studies were done using a light microscope (Bio-microscope, YJ-2005 series) connected to a laptop computer (hp, china) with TSview 1.0 and Amscope Toup View 3.2 software. These figures were automatically generated with the aid of the software

3. Result



Figure 1. Showing hyperkeratosis, heavy crust formation, alopecia, wrinkling of skin and mite lesions on the head, ear and leg region

On clinical examination there was generalized wrinkling and thickening of the skin with heavy crust formation on the abdomen, forehead, ear, the limbs, interdigital spaces, mammary gland and inner thigh. Alopecia and erythema were also observed on these parts on the goat's body. foul smelling odour was perceived from the goat, several mites lesion were seen on all the limbs and the goat was vigorously biting its skin and rubbing its body against the examination table. (Figure 1)

3.1. Parasitological Findings

Examination of the skin scraping under the stereoscope showed numerous different developmental stages of *Sarcoptes* mites as eggs, larvae, nymphs and adult mites were seen. The mites were identified as *Sarcoptes scabiei* which are oval to round in shape, with dorsally convex tortoise-like body that is covered with spines and triangular scales with only the first two pairs of legs protruding beyond the body margin. The female mite has some scattered short blunt spines on the dorsal surface, which aid her in maintaining her position within the tunnels of epidermis, they have short and thick legs, with only the first two pairs of leg projecting beyond the body margin in both sexes and the fourth pair in males end in specialized structures called suckers that help them grip and move on the skin surface. (Figure 2 a-b).

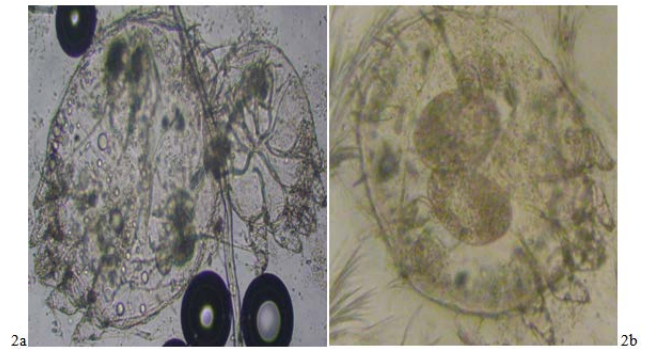


Figure 2. (a-b): Showing ovigerous female *sarcoptes scabiei var caprae* with oval to round, dorsally convex tortoise-like body that is covered with spines and triangular scales with only the first two pairs of legs protruding beyond the body margin

3.2. Histological Findings

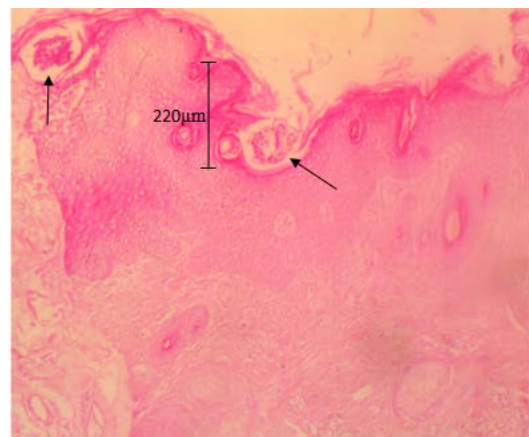


Figure 3. Biopsy section of the skin showing epidermal tunnels containing *Sarcoptes scabiei var caprae*, hyperkeratosis, spongiosis, serocellular exudates, pustules and acanthosis. (Haematoxylin and Eosin). Tunnel height: 220 µm

Microscopic examination of skin biopsy showed mites of *Sarcoptes species*, Severe hyperkeratosis, granulosis, epidermal hyperplasia, subcorneal acantholysis, epidermal acanthosis, Numerous cutaneous erosions, Hyperkeratosis (ortho & para), ballooning, degeneration of keratinocytes, spongiosis and numerous tunnels in the epidermis, while dermal lesions show Moderate neutrophilic exocytosis, increased granulation tissue, edema in superficial dermis with a few granulation tissues, Mild vasculitis & neutrophilic aggregates in deep dermis (Figure 3).

Morphometric studies of both the height and diameter of the tunnels created by the mites in the epidermis were done at weekly interval over a period of two weeks before the goat eventually died and tunnels were measured in micrometers.

Table 1. Measurement data of tunnel diameter and tunnel height created by *Sarcoptes scabiei* var *caprae* in the epidermis of the goat

	TUNNEL DIAMETER	TUNNEL HEIGHT
WEEK 1	200µm	220µm
WEEK 2	170µm	180µm

The number of adult mites and their eggs counted from the goat over a period of four weeks is presented in Table 2 while results from Haematological and biochemical studies over the same period is presented in Table 3.

Table 2. Adult mites and Egg count from the West Africa Dwarf Goat

	ADULT MITE COUNT	EGG COUNT
BEFORE TREATMENT	305	197
WEEK 1 POST TREATMENT	300	195
WEEK 2 POST TREATMENT	272	164

Table 3. Temperature, Haematological and Biochemical values

Parameter	Before Treatment	Week 1 of Treatment	Week 2 of Treatment	Reference values
RT(°C)	40	40.1	39.7	39.1±0.5
PCV(%)	12	15	14	22-38
Hb (g/dl)	5.6	5.9	5.2	8-12
RBC(X10 ⁹ /µl)	4.7	4.7	4.9	8-18
WBC(X10 ³ /µl)	14.2	13.9	14.5	4-13
Neutrophil(%)	51	49	49	30-48
Eosinophil(%)	7	7	6	1-8
Total Protein(g/dl)	3.9	4.1	4.5	6.1-7.5
Albumin(g/dl)	1.4	1.7	1.9	2.3-3.6
Globulin(g/dl)	2.5	2.4	2.6	2.7-4.4

For treatment of the case, Amitraz wash commenced immediately at 0.05% concentration which was carefully worked into the skin with a sponge at weekly interval before the death of the goat on the second week of presentation and 5% oxytetracycline was administered at dosage of 10 mg/kg to control secondary bacterial infection for 5 days while 1% ivermectin was given subcutaneously at 0.2 mg/kg weekly. Intense pruritus and biting of the skin reduced after 10 days of treatment but the goat died on day 15 of presentation.

4. Discussion

Sarcoptes scabiei var *caprae* infestation in goats is a debilitating and economical disease which is a major constraint in farming, which spreads rapidly within a herd by direct contact and cause severe damage to the skin by

creating burrows and tunnels within the epidermis leading to low productivity and death of animals [13,16,20].

The histological lesions of the epidermis and dermis of the skin of the mange infested goat observed in this present study is in agreement with the findings of [9]. who reported similar histological findings of hyperkeratosis, parakeratosis, lichenified stratum corneum, acanthosis and dermal conditions which were mostly inflammatory in the skin of mange infested sheep and goat.

The hematological studies in this case showed decrease in Packed cell volume, erythrocyte count and hemoglobin level which is indicative of anemia due to the fact that these mange mites feed on epidermal fluids and consume blood as reported by [21]. [10] also reported decrease in the Hemoglobin level and Packed cell volume which may be contributed by the decrease cellular content in the blood after infestation of mange mite.

The leucocytosis observed is likely due to excoriation of the skin of the animal which allows penetration of invading microorganisms which elicit the production of leucocytes as reported in goats with sarcoptic mange by [1]. and in dog with demodicosis by [8]. Eosinophilia exhibited by this goat is probably due to allergic reactions caused by the mites or activation of immune system. The decrease in serum protein, albumin and globulin level observed is probably due to the fact that *sarcoptes scabiei* var *caprae* continuously seep and suck fluid from mange infested animals.

The mortality seen in the goat herd which also occurred in the case presented in this study is believed to be caused by *Sarcoptes scabiei* var *caprae* in which the lesions observed on the affected goat were generalized diffused hyperkeratosis and heavy crust formation with several mite wounds which have persisted for a very long time as this agrees with the work of [14]. who reported that this pruritic skin disease leads progressively to high mortality and dramatic drop in milk yield of dairy goat herd.

It is therefore very paramount for goat herd farmers to note that diagnosis of goats with either mild, localized or generalized sarcoptic mange infestation should be carried out by a Veterinarian and appropriate treatment should commence immediately after proper diagnosis is done as [18]. noted that a therapeutic efficacy of a combination of amitraz and ivermectin has provided an excellent result of complete recovery from generalized infestation of mange mite with almost 6 treatments and as the life cycle of the mite extends over a period of 18-24 days [23]., considering that scrapings are performed on a limited area of the lesions, a single negative skin scraping should generally not be considered as an indication of complete recovery. Recovery should rather be determined based on two to three consecutive negative skin scrapings done at two weeks interval.

Reference

- [1] Adejinmi J.O, Alayande M.O, Sadiq N.A, Adejinmi O.O. Clinical syndrome, Haematological and Biochemical parameters of goats naturally infested with Mange (*Sarcoptes scabiei*). Tropical Animal Production Investment. 3: 29-34, 2000.
- [2] Aitken, I.D. Disease of Sheep, 4th edition. Black well Publishing, Edinburgh. pp: 326-330, 2007.
- [3] Akomas S.C., Obijuru O.C And Herbert U.: Hematologic And Serologic Changes Following Ivermectin Treatment In Mange

- Infested West African Dwarf Goats. *Advances in Environmental Biology*. 5 (9): 2557-2560, 2011.
- [4] Anderson, D.E., Rings, D.M., Pugh, D.G., Diseases of the integumentary system. In: Pugh DG, editor. *Sheep and Goat Medicine*. Philadelphia, Pa, USA: WB Saunders; pp. 197-222, 2002.
- [5] Bancroft, J.D., and Harry, C.C., *Manual of Histological Techniques and their Diagnostic Application*. 2nd Edn., Singapore. Longman Singapore Publisher, 1-4. 1994.
- [6] Bayou, K., Control of Sheep and Goat Skin Disease. In: By Ian, B.C. and Bayou, B. (Eds.) *Proceedings of control of sheep and goat skin diseases for improved quality of hide and skin*, FAO, Addis Ababa, pp: 13-20, 1998.
- [7] Curtis, C F. Current trends in the treatment of Sarcoptes, Cheyletiella and Otodectes mite infestation in dogs and cats. *Veterinary Dermatology*. 15 (2): 108-114, 2004.
- [8] Falohun O.O., Onyiche, E.T., Adejinmi, J.O., Omonuwa, O.A., Awoyomi, O.J., Ogundare, S.T., Suleiman, S. Death of a four-year-old German shepherd dog due to *Demodex canis* in Ibadan, Southwest Nigeria: a case report. *Research* 1: 887-889, 2014.
- [9] Gbolagade D. Gbolagunte, Joseph Olajide Hambolu and Stephen Owarioro Akpavie, Pathology and Leather Surface Appearance of Disease Afflicted Nigerian Small Ruminant Skins. *AU J.T.* Vol. (4), pp: 271-283, 2009.
- [10] Hafeez, U. A., Zia-Ud-Din S.Z., Abdul Jabbar and Zahida T. Prevalence of Sheep Mange in District Dera Ghazi Khan (Pakistan) and Associated Hematological/Biochemical Disturbances. *Int. J. Agri. Biol.* Vol. 9: No. 6, 2007.
- [11] Jackson P.G.G., Richards H.W., Lloyd S. Sarcoptic mange in goats. *Veterinary Record*; 112 (14): p. 330, 1983.
- [12] León-Vizcaíno L., Cubero M.J., González-Capitel E. Experimental ivermectin treatment of sarcoptic mange and establishment of a mange-free population of Spanish ibex. *Journal of Wildlife Diseases*. 37 (4): 775-785, 2001.
- [13] Morris D.O., and Dunstan R.W. A Histomorphological study of Sarcoptic acariasis in the dog: 19 cases. *Journal of American Animal Hospital Association*. Vol. 32 (2): pp 119-124, 1996.
- [14] Nektarios D. G., Rania F., Nikilaos P., Elias P., Harilaos K. and Alaxander F. K. Moxidectin Efficiency in a Goat Herd with Chronic and Generalized Sarcoptic Mange. *Vet Med int*. 2011.
- [15] Nwoha, R. I. O., A case report on scabies in a goat. *Clinical Reviews and Opinions*. Vol. 3 (5), pp. 51-54, 2011.
- [16] Oladeji, J.O. Socio-economic aspects of the management of mange disease by small ruminant farmers in Ido Local Government area of Oyo State, Nigeria. *Journal of Agriculture, Forestry and the Social Sciences*. Vol. 4 (1): 75-79, 2006.
- [17] Olbricht, (2003) Skin Biopsy Techniques and Basic Excisions. In: *Dermatology*, 1st edition, Bologna, JL, Rapini, RP, et al (Eds), Mosby, London. p. 2269.
- [18] Pentyala V.S., Chaitanya Y., Divakar M.S.A., Somaiah S., Rao M.C.. Management of Sarcoptic Mange with a Combination of Amitraz and Ivermectin in Ongole Calves. *Polivet, Indian Journal*, Vol. 10 (2), 275-277, 2009.
- [19] Radostits, O.M., Blood, D.C and Gay, C.C. *Veterinary Medicine: A text book of the diseases of cattle, sheep, goats, pigs and horses*, 8th Edn. London: Bailliere Tindall, 1304-1305, 1994.
- [20] Radostits, O.M., Gay, C.C., Hinchcliff, K.W., and Constable P.D. (*Veterinary Medicine: A text book of the diseases of cattle, sheep, goats, pigs and horses*, 10th Edn. London: Bailliere Tindall, 1608-1609, 2007.
- [21] Schalm, O.W. *Veterinary Haematology*. 4th Edn., Lea and Febiger, Philadelphia, USA. 1986.
- [22] Scott, D.W., Miller, W.H., Griffin, C.E.. *Dermatologic therapy*, In: Mueller and Kirk's small animal dermatology, Philadelphia, Pa: WB Saunders, 6th ed 207-273, 2001.
- [23] Soulsby, E.J. *Helminths, Arthropods and Protozoa of Domesticated Animals*. 7th Edn., Bailliere Tindall, London, pp. 476-479, 1982.
- [24] Wall, R. and Shearer, D. *Veterinary of Entomology. Arthropod Ectoparasites of Veterinary Importance*. Chapman and Hall, London pp. 1-420. (1997).