

Typical and Atypical Cogan's Syndrome: 7 Cases and Review of the Literature

Sara Belghmidi¹, Btissaam. Belhoucha^{2*}, Ibtissam Hajji¹, Youssef. Rochdi², Ennasiri wiam¹, Hassan. Nouri², Baha ali¹, lahcen. Aderdour², Abdelaziz. Raji², A Moutaouakil¹

¹Department of ophthalmology, CHU Mohammed VI, Marrakech, Maroc

²Department of ENT, CHU Med VI, Marrakech 2360, Morocco

*Corresponding author: btissambelhoucha@gmail.com

Received August 18, 2014; Revised September 13, 2014; Accepted September 16, 2014

Abstract Cogan's syndrome (CS) is a rare presumed autoimmune disorder characterized by nonsyphilitic interstitial keratitis and progressive audiovestibular symptoms similar to those of Meniere's syndrome. Material and methods: We reviewed the records of a prospective study carried in CHU Mohammed VI of Marrakech, from September 2012 to June 2014, including 7 patients with a Cogan's syndrome. Clinical data regarding age, sex, ethnic origin, presenting manifestations, ocular, audiovestibular and systemic manifestations, treatment and outcome were collected. Results: 7 patients were identified, 3 with typical Cogan's syndrome and the remaining 4 with atypical Cogan's syndrome. The age ranged from 12 to 65 years, with median age of 31 years, The presenting manifestations were ocular in four patients and audio vestibular in three. Examination revealed a bilateral interstitial keratitis (stromal scarring with ghost vessels) in six patients. Which was isolated in three cases and associated in 1 case with conjunctivitis, 1 with subconjunctival hemorrhage and one with corneal neovascularization. Audiovestibular manifestations in the two groups were typical, with vestibular symptoms, followed by progressive hearing loss of variable severity. Five of our patients presented systemic manifestations. All patients initially received local and systemic corticosteroids (CTC) given the ocular symptom but Clinical follow-up showed recurrence of audiovestibular symptoms after dose reduction of prednisone in 4 patients. In these cases, immunosuppressive therapy was able to improve hearing in 3 cases and visual function in 2 cases. Overall, 5 patients maintained good visual; 2 patients did not respond to medical treatment and thus were candidates for corneal transplant, 1 patient presented a total right deafness 3 years after the onset. The treatment strategies are not clearly defined; therefore, early assessment and treatment for systemic inflammation are needed to prevent life threatening complications.

Keywords: cogan's syndrome, interstitial keratitis, deafness

Cite This Article: Sara Belghmidi, Btissaam. Belhoucha, Ibtissam Hajji, Youssef. Rochdi, Ennasiri wiam, Hassan. Nouri, Baha ali, lahcen. Aderdour, Abdelaziz. Raji, and A Moutaouakil, "Typical and Atypical Cogan's Syndrome: 7 Cases and Review of the Literature." *Neuro-Ophthalmology & Visual Neuroscience*, vol. 1, no. 1 (2014): 8-12. doi: 10.12691/novn-1-1-2.

1. Introduction

Cogan's syndrome (CS) is a rare autoimmune vasculitis. Its pathogenesis is unknown. Infection, but primarily autoimmunity, may play contributing roles in the pathogenesis of this disease. Clinical hallmarks are bilateral interstitial keratitis and vestibuloauditory dysfunction. Corticosteroids are the first line of treatment, and multiple immunosuppressive drugs have been tried with variable degrees of success. We report a case of an atypical Cogan's syndrome, the workup of the diagnosis, and treatment results.

2. Material and Methods

We reviewed the records of a prospective study carried in CHU Mohammed VI of Marrakech, from September

2012 to June 2014, including seven patients with a Cogan's syndrome. Clinical data regarding age, sex, ethnic origin, presenting manifestations, ocular, audiovestibular and systemic manifestations, treatment and outcome were collected.

According to the criteria of Haynes et al. [6], Typical Cogan's syndrome was defined with the following three conditions:

1. ocular symptoms, typically an isolated non-syphilitic IK that could be associated with conjunctivitis, conjunctival or subconjunctival bleeding, or iritis.

2 audiovestibular symptoms similar to those of Meniere's syndrome, usually progressing to deafness in 1-3 months.

3 An interval between the onset of ocular and audiovestibular manifestations of less than 2 years.

Patients with any of the following symptoms are classified as having atypical Cogan's syndrome: (1) inflammatory ocular manifestations, with or without IK; (2) typical ocular manifestations associated with audiovestibular

symptoms different from Meniere-like episodes; or (3) a delay of more than 2 years between the onset of typical ocular and audiovestibular manifestations.

In our series, the median age was 31 years (28 yr for the typical Cogan's syndrome group and 34 yr for the atypical Cogan's syndrome group) and the mean delay between onset of symptoms and diagnosis was 37 months.

3. Results

7 patients were identified, 3 with typical Cogan's syndrome and the remaining 4 with atypical Cogan's syndrome. 4 of the patients of our series were women. The age ranged from 12 to 65 years, with median age of 31

years (28 yr for the typical Cogan's syndrome group and 34 yr for the atypical Cogan's syndrome group), and the mean delay between onset of symptoms and diagnosis was 37 months. (15 months for the typical Cogan's syndrome group and 22 months for the atypical Cogan's syndrome group).

The presenting manifestations were ocular in 4 patients and audio vestibular in 3. In the first group, ocular signs and symptoms were redness, photophobia and reduced vision. In the overall sample examination revealed a bilateral interstitial keratitis (stromal scarring with ghost vessels) in six patients which was isolated in three cases and associated in 1 case with conjunctivitis, 1 with subconjunctival hemorrhage and one with corneal neovascularization.

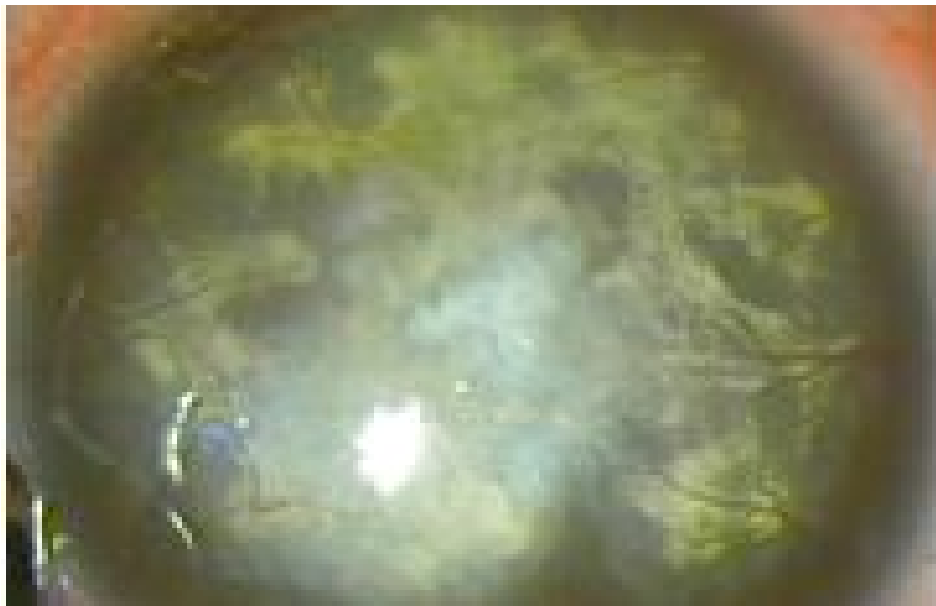


Figure 1. interstitial keratitis, with ghost vessels and ferritin deposits

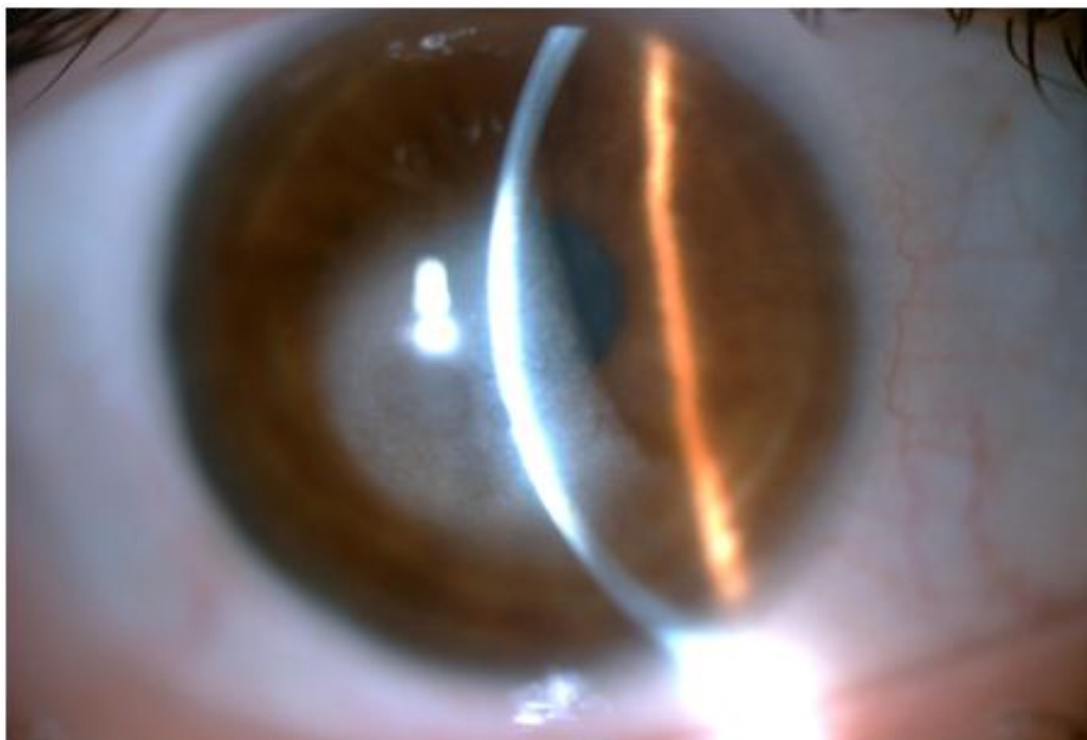


Figure 2. interstitial keratitis

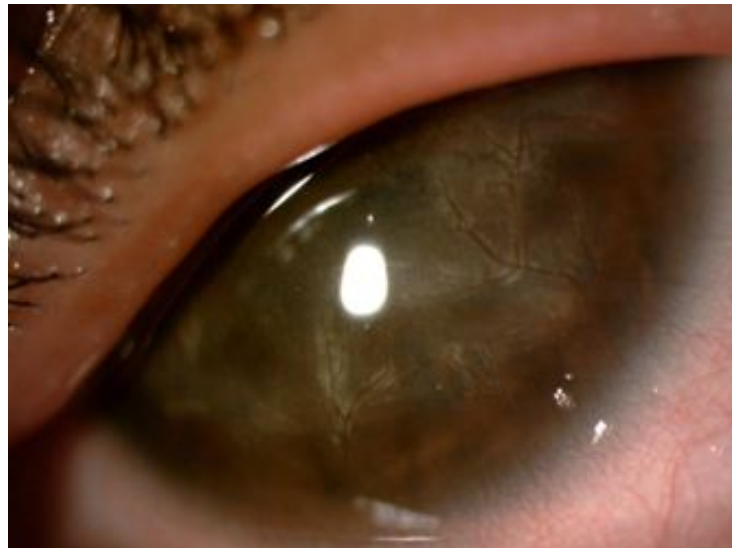

Figure 3. image showing a recurrence of interstitial keratitis,, after dose reduction of prednisone

Audiovestibular manifestations in the two groups were typical, similar to those of Meniere's syndrome with vestibular symptoms including vertigo and imbalance associated with nausea, vomiting, followed by progressive hearing loss of variable severity.

In the typical Cogan's syndrome group, the delay between the onset of ocular and audiovestibular manifestations was 4 months {1-13}.

In the atypical Cogan's syndrome group, the mean interval between ocular and audiovestibular manifestations was 28 months.

Five of our patients presented systemic manifestations (1 case of typical cogan's syndrome and 4 cases of the atypical cogan's syndrome group): 2 constitutional features including fever, diarrhoea and weight loss, 2 arthralgias, and one mitral insufficiency in a case of atypical cogan's syndrome. All patients were referred to a rheumatologist for additional autoimmune workup. Blood test results were negative for syphilis serology, antinuclear antibody, antinuclear cytoplasmic antibody, rheumatoid factor, rapid plasma reagin, and HLA-B27.

The chest computed tomography finding was negative for any lymphadenopathy or other lesions and the cerebral magnetic resonance imaging (MRI) was normal.

Based on audiovestibular, ocular findings and given the patients' s clinical history with negative laboratory and

imaging test results, which allows the exclusion of infectious, neoplastic, granulomatous, and autoimmune etiologies, the diagnosis of atypical Cogan's syndrome was established.

All patients initially received local and systemic corticosteroids (CTC). Patients were administered 1mg/kg per day of prednisone for the first week and then slowly tapered, depending on the therapeutic response and development of adverse effects. The average duration of treatment was 4 months. In addition, the patient with mitral insufficiency received a bolus of prednisolone.

Clinical follow-up showed a recurrence of audiovestibular symptom after dose reduction in 4 cases of prednisone (1 case of typical cogan's syndrome and 3 cases of the atypical cogan's syndrome group). These cases have required the introduction of methotrexate for 7 months. Such immunosuppressive therapy improved hearing in 3 cases and visual acuity in 2 cases.

Overall, 5 patients maintained good visual acuity (> 4/10); 2 patients (atypical cogan's syndrome) did not respond to medical treatment and thus were candidates for corneal transplant, 1 patient (atypical cogan's syndrome with mitral insufficiency) presented a total right deafness at 3 years after the onset of her symptoms and she underwent a surgical replacement of the mitral valve.

Table 1. Clinical characteristics of patients with Cogan's syndrome

	Num Of Patients	Mean age at onset	audiovestibular initial manifestations	Ocular initial manifestations	Mean delay between eye and audiovestibular Manifestations
Typical	3 cases	28 years	0 case	3 cases	15 months
Atypical	4 cases	34 years	3 cases	1 case	22 months
	Cases of systemic manifestations	Cases treated by CTC	Cases treated by immunotherapy + CTC	Cases of of deafness	Cases of candidates for corneal transplant
Typical	1case	2 cases	1 case	0 case	0 case
Atypical	4cases	1 case	3 cases	1 case	2 cases

4. Discussion

Cogan's syndrome is a rare autoimmune vasculitis which typically associates a non-syphilitic IK and audiovestibular

symptoms resembling Meniere's disease, with frequent systemic disease. It was first described in 1945 by an ophthalmologist, Dr David G. Cogan, who reported on a "syndrome of nonsyphilitic interstitial keratitis (IK) and vestibuloauditory symptoms" that resembled Meniere's disease [1,2]. Comparison of our series with the reported

cases in the literature reveal a moderate difference regarding the prevalence of these systemic manifestations in the atypical Cogan's syndrome.

Cogan's syndrome occurs equally in both sexes, in patients from 2 to 60 years of age. The average age of onset is 25 years of age and there is no gender-specific prevalence [1,4]. In our series, the median age was 31 years (28 yr for the typical Cogan's syndrome group and 34 yr for the atypical Cogan's syndrome group) and the mean delay between onset of symptoms and diagnosis was 37 months.

The variability of ocular and audiovestibular clinical manifestations complicates its diagnosis, which should be suspected whenever there is a close temporal association between ocular abnormalities and cochleovestibular symptoms. Signs of inner ear dysfunction include nausea, vomiting, tinnitus, vertigo, and bilateral hearing loss. Deafness generally progresses rapidly during a 1- to 3-month period. Because the early auditory symptoms of Cogan's syndrome vary, differential diagnosis can be difficult [1,2]. Typically, audiometry demonstrates a sensorineural hearing loss, preferentially involving the low and high range frequencies; poor speech discrimination is also observed.

In the review by Vollertsen et al. [3], which included 78 patients with typical Cogan's syndrome, bilateral deafness affected 43.5% of patients and occurred in average 3 months after the onset of the initial symptoms.

Ocular disease presents with redness, photophobia, watering, and reduced vision. Examination reveals ciliary injection with mild iritis and discrete fluffy opacities in the deep portion of the corneal stroma. Corneal ulceration does not occur and vascularisation is unusual. A histological study of the ocular lesions showed lymphocytic and plasma cell infiltration in the cornea with neovascularisation but no vasculitis [1,3,5]. Our series examination revealed a bilateral interstitial keratitis (stromal scarring with ghost vessels) in six patients which was isolated in three cases and associated in one case with conjunctivitis, in another case with subconjunctival hemorrhage and in a third patient with corneal neovascularization.

In addition to ocular and vestibuloauditory dysfunctions, approximately 70% of patients have underlying systemic disease for which vasculitis is considered the pathogenetic mechanism [1,2]. Patients with atypical Cogan's syndrome had systemic manifestations more commonly than those with typical Cogan's syndrome, similar to our series. The most common symptoms are cardiovascular, neurological and gastrointestinal, including diarrhoea, melena and abdominal pain, sometimes related to mesenteric arteritis [1,4,6].

The most characteristic cardiovascular manifestation of Cogan's syndrome is aortitis with aortic insufficiency [1,2,4]. In this paper we had one case of mitral insufficiency controlled by surgical replacement of the mitral valve.

Neurological manifestations may include hemiparesis or hemiplegia due to a cerebral vascular accident and aphasia due to a transient ischaemic event.

The clinical diagnosis is based on audiovestibular symptoms, ocular inflammation and non reactive serologic tests for syphilis in the presence of histologically proven vasculitis [1]. There are no specific biological tests for the

diagnosis, and the investigations are aimed at excluding other etiologies... [1,2].

Differential diagnoses to consider are Takayasu's arteritis, polyarteritis nodosa, Wegener's granulomatosis, giant cell arteritis and rheumatic arthritis. The diagnosis of atypical Cogan's syndrome requires caution, as this entity may share common manifestations with other systemic diseases.

Recent evidence strongly suggests that Cogan's syndrome is an autoimmune disease [1,11] but some studies suggest that its etiology includes infection and autoimmunity. Chlamydia psittaci has been isolated from a patient with Cogan's syndrome and serological evidence of a recent Chlamydia trachomatis infection was reported in 4 of 13 patients [6]. A decade ago, antibodies directed against a corneal antigen or constituents of the inner ear were detected by multiple groups [9,10]. Histopathological examination of corneal tissue and cochlea shows lymphocytic and plasma cell infiltration, suggesting a cell-mediated reaction. [1,6]. Vasculitis is considered the pathogenetic mechanism.

Such mechanisms appear to explain the audiovestibular dysfunction that has been reported in Cogan's syndrome, including bilateral fluctuating hearing loss, tinnitus, and severe vertigo [2,4]. Fischer and Hellstrom [13] reported primarily infiltration of the inner ear with lymphocytes, thickening of membranous tissues, endolymphatic hydrops, degeneration of the organ of Corti, and atrophy of eighth nerve in temporal bones from a 32-year-old man who was diagnosed with Cogan's syndrome four years prior to death [13].

Medical treatment of Cogan's syndrome depends on how extensive the disease is at the time of diagnosis. It includes the use of topical agents for limited ocular disease and immunosuppressive therapy for more extensive ocular disease, inner ear involvement, and/or systemic vasculitis. Systemic corticosteroids are always the most widely used and successful, and it is argued that they can aid in the recovery of hearing if given early in the disease course. This was the case in our series; early treatment allowed control of ocular and auditory involvement.

Immunosuppressive drugs, such as methotrexate, azathioprine, cyclosporine and cyclophosphamide, have all been used with variable degree of success. The best results seem to have been obtained with methotrexate, which led to an improvement in four published cases [16,35,36,68]. In our series methotrexate was used in four cases, which allowed to an auditory and ocular improvement in two cases.

However, in the absence of controlled trials, there are no definitive therapeutic recommendations [1,12]. Patients without systemic disease generally have a good prognosis and an average life expectancy. The corneal disease may resolve with or without therapy; the deafness is often irreversible, although systemic steroids initiated within 2 weeks from the onset of symptoms may limit progression. Patients who develop serious vasculitis, such as aortitis, have an increased risk of death due to complications. Therefore, early assessment and treatment for systemic inflammation are needed to prevent life threatening complications [1,2,6,12].

5. Conclusion

Cogan's Syndrome is a very rare clinical entity whose etiopathology is still unknown. In addition to the ocular and audiovestibular symptoms, various systemic manifestations, including aortitis and necrotizing vasculitis, have been reported in such patients.

The treatment strategies are not clearly defined. Corticosteroids are often effective in controlling the ocular, vascular or other visceral manifestations but have much less reliable effects on hearing. The best results seem to have been obtained with methotrexate. Therefore, early assessment and treatment for systemic inflammation are needed to prevent life threatening complication.

References

- [1] Greco A, et al, Cogan's syndrome: An autoimmune inner ear disease, *Autoimmun Rev* (2012).
- [2] Rarey et al. Intralabyrinthine osteogenesis in cogan's syndrome. *Am J Otolaryngol* 4'.387-390, 1986.
- [3] Cody DTR, Williams HL. Cogan's syndrome. *Laryngoscope* 1960; 70: 447-75.
- [4] Vollertsen RS, McDonald TJ, Younge BR, Banks PM, Stanson AW, Ilstrup DM. Cogan's syndrome: 18 cases and a review of the literature. *Mayo Clin Proc* 1986; 61: 344-61.
- [5] Ho AC, Roat MI, Venbrux A, Hellmann DB. Cogan's syndrome with refractory aortitis and mesenteric vasculitis. *J Rheumatol* 1999; 26: 1404-7.
- [6] Haynes BF, Kaiser-Kupfer MI, Mason P, Fauci AS. Cogan syndrome: studies in thirteen patients, long-term follow-up, and a review of the literature. *Medicine* 1980; 59: 426-41.
- [7] Gluth MB, Baratz KH, Matteson EL, Driscoll CL. Cogan syndrome: a retrospective review of 60 patients throughout a half century. *Mayo Clin Proc* 2006; 81: 483-8.
- [8] Casselman JW, Majoor MH, Albers FW. MR of the inner ear in patients with Cogan syndrome. *AJNR Am J Neuroradiol* 1994; 15: 131-8.
- [9] Majoor MHJM, Albers FWJ, Van Der Gaag R, Gmelig-Meyling F, Huizing EH. Corneal autoimmunity in Cogan's syndrome? Report of two cases. *Ann Otol Rhinol Laryngol* 1992; 101: 679-84.
- [10] Froehlich F, Fried M, Gonvers JJ, Saraga E, Thorens J, Pecoud A. Association of Crohn's disease and Cogan's syndrome. *Dig Dis Sci* 1994; 39: 1134-7.
- [11] Schuknecht HF. Ear pathology in autoimmune diseases. *Adv Otorhinolaryngol* 1991; 46: 50-70.
- [12] Van Doornum S, McColl G, Walter M, Jennens I, Bhathal P, Wicks IP. Prolonged prodrome, systemic vasculitis, and deafness in Cogan's syndrome. *Ann Rheum Dis* 2001; 60: 69-71
- [13] Fischer ER, Hellstrom HR: Cogan's syndrome and systemic systemic vascular disease: analysis of pathologic features with reference to its relationship to thromboangiitis obliterans (Buerger). *Arch Pathol* 72: 572-592, 1961 6.