

Richter Type of Incarcerated Obturator Hernia: Misery Still Continues

Kumar Jayant^{1,*}, Rajendra Agarwal², Swati Agrawal³

¹Department of Surgery, Sudha Hospital & Medical Research Centre, Talwandi, Kota, Rajasthan, India

²Head of Department of Surgery, Sudha Hospital & Medical Research Centre Kota, Rajasthan, India

³Sudha Hospital & Medical Research Centre Kota, Rajasthan, India

*Corresponding author: jayantsun@yahoo.co.in

Received November 06, 2013; Revised November 26, 2013; Accepted December 08, 2013

Abstract Obturator hernia is a very rare type of hernia. Constitutes approximately 0.1–1% of all intra-abdominal hernias. 0.5–1.5% of them may lead to small intestinal obstructions. It usually seen in frail, underweight, elderly female. It's early presentation is nonspecific, so these hernias are usually discovered only after they have become incarcerated. Incarcerated obturator hernias are commonly diagnosed on abdominal computed tomography scan or emergency laparotomy.

Keywords: richter obturator hernia, strangulated

Cite This Article: Kumar Jayant, Rajendra Agarwal, and Swati Agrawal, "Richter Type of Incarcerated Obturator Hernia: Misery Still Continues." *Global Journal of Surgery* 1, no. 4 (2013): 50-52. doi: 10.12691/js-1-4-3.

1. Introduction

Obturator hernia is very uncommon. [1] It was first reported by Arnaud de Ronsil in 1724 and successfully repaired by Henry Obre in 1851. It is of 0.1-1% of all hernias and causes 0.5-1.5 % of all small intestinal obstructions [2].

It is more commonly diagnosed only during emergency surgery for bowel obstruction due to incarceration. [3] It is mostly seen in elderly underweight women. This richter's type of obturator hernia commonly involves affected right side.

Richter type involves and causes partial obstruction of a bowel loop, which may lead to ischemia and perforation, with out obstruction, causing delay in diagnosis. Treatment of obturator hernia is surgical with or without mesh [4].

2. Case Report

A 65 year old female presented with a 3-day history of abdominal distension with mild intermittent abdominal pain, nausea and passing flatus only. She was a known case of hypothyroidism, taking Levo-thyroxine in inadequate dose. On examination she was frail and emaciated with normal vitals. Hernial orifices were clinically normal. Her initial abdominal X-ray was showing few air-fluid level with air in rectum. Patient was managed conservatively, next day she developed features of peritonitis, for which emergency laparotomy done. Her on admission T₃ 50ng/dl, T₄ 2mcg/dl and TSH 8.8mIU/l levels were indicating poorly controlled hypothyroidism.

Operative Findings

We found a loop of small intestine (4 feet from ileo caecal junction) that was fixed to the pelvic wall dorsal to the right femoral canal and appeared to be the site of obstruction. After mobilizing the small intestine, we established that it was partially incarcerated obturator hernia. The incarcerated part of small intestine was small necrotic 1.0 x 1.0 cm perforation, on antimesenteric side, which was resected, end to end anastomosis done and dilated obturator foramen was closed with interrupted sutures. Postoperative course was uneventful and patient was discharge on 5th postoperative day and was doing well on subsequent follow-ups.

3. Discussion

Richter's hernia is an abdominal hernia in which only a segment of bowel circumference is involved and strangulated in hernial orifice (Figure 1). This involved bowel is mostly terminal ileum. But can involve, any lumen from the stomach to the colon leading to incarceration. [5] In this case herniated loop was approx four feet proximal to ileocaecal junction.

As per Richter most important theory behind formation of this hernia, are size and consistency of the hernial orifice: it must be big enough to involve the bowel wall, but small enough to prevent complete protrusion of loop of the intestine, and with firm hernia ring margin or in Richter's words, "possess strong spring-force". [6] Other theory presumes that this constricting ring is a main determining factor causing strangulation and compromised blood circulation, subsequent ischaemia and gangrene of affected segment of bowel. [7] They may

present with nausea and vomiting, though less common and less severe than usual cases of strangulation because obstruction is never complete. The diagnosis is only

confirmed with laparotomy although few considered the role of diagnostic laparoscopic, but it's use needs high index of suspicion [8].

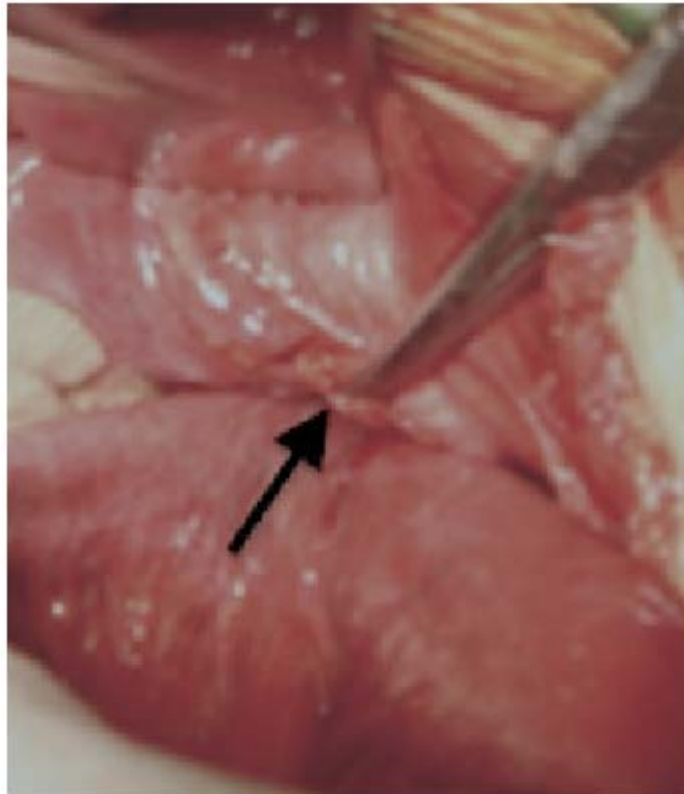


Figure 1. Herniated Loop of Small Intestine

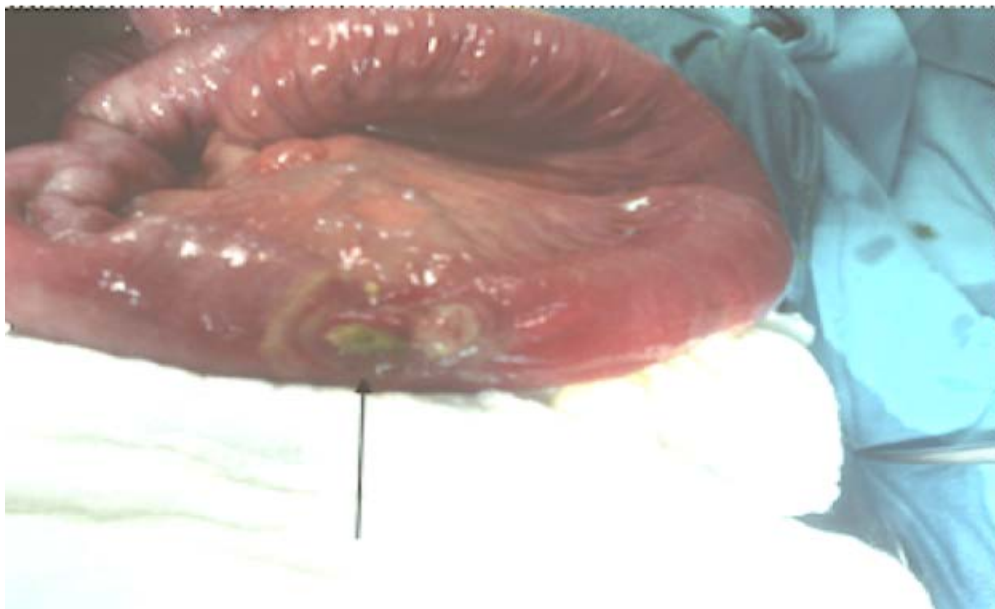


Figure 2. Incarcerated Segment of Small Intestine With Perforation

According to localization and the mode of herniation and entrapment, the clinical picture and course showed varied presentation. As obturator hernia is not visible or easily palpable leads to delay in the diagnosis, so the majority of them only present after incarceration. This late recognition of obturator hernias is the major predicting factor for the highest mortality of all the abdominal hernias [9]. It is important to note that it is a Richter type hernia that prevents development of features of intestinal obstruction, causing delay in abdominal CT scan and

subsequent surgery. [10] Similarly in this case there was vague presentation of patient and associated hypothyroidism was misleading and patient was managed conservatively. Soon patient developed feature of peritonitis and emergency laparotomy done with increased risk of mortality and morbidity.

4. Conclusion

Richter type of obturator hernia is rare and present with nonspecific early symptoms, can still be misleading even to the experienced clinicians. Its delayed diagnosis is associated with bowel necrosis and perforation with significant postoperative morbidity and mortality.

Acknowledgement

None.

Conflict of Interest

None.

"This research received no specific grant from any funding agency in the public, commercial, or not-for-profit sectors."

References

- [1] Petrie A, Tubbs Rs, Matusz P, Shaffer K, Loukas M. Obturator Hernia: Anatomy, embryology, diagnosis, and treatment. *Clin Anat* 2011;24:562-9.
- [2] Zhang H, Cong Je, Chen Cs. Ileum perforation due to delayed operation in obturator hernia: a case report and review of literature. *World J Gastroenterol* 2010;16:126-30.
- [3] Katoh T, Kawamoto R, Kusunoki T. A case of obturator hernia with overlooked howship-romberg sign and treated as sciatica. *Nihon Ronen Igakkai Zasshi* 2011;48:176-9.
- [4] Rodríguez-Hermosa Ji, Codina-Cazador A, Maroto-Genover A, et Al. Obturator hernia: clinical analysis of 16 cases and algorithm for its diagnosis and treatment. *Hernia* 2008;12:289-97.
- [5] Kammori M, Mafune K, Hirashima T, et Al. Forty three cases of obturator hernia. *Am J Surg* 2004; 187:549-52.
- [6] Yau KK, Siu WT, Fung KH, Li MK. Small-bowel obstruction secondary to incarcerated obturator hernia. *Am J Surg* 2006; 192: 207-208.
- [7] Liao Cf, Liu Cc, Chuang Ch, Hsu Kc. Obturator hernia: a diagnostic challenge of small-bowel obstruction. *Am J Med Sci* 2010; 339:92-4.
- [8] Skandalakis Pn, Zoras O, Skandalakis Je, Mirilas P. Richter hernia: surgical anatomy and technique of repair. *Am Surg* 2006;72:180-4.
- [9] Stamatiou D, Skandalakis Lj, Zoras O, Mirilas P. Obturator hernia revisited: surgical anatomy, embryology, diagnosis, and technique of repair. *Am Surg* 2011; 77:1147-57.
- [10] Mantoo Sk, Mak K, Tan Tj. Obturator hernia: diagnosis and treatment in the modern era. *Singapore Med J* 2009; 50:866-70.