

An Overview of Retrospective Studies on Distomolar Teeth in Turkish Population and 4 Case Reports

Alpin Değirmenci^{1*}, Ertan Yalçın², Gelengül Gürbüz Urvasızoğlu²

¹Oral Surgeon, Clinic of Oral Surgery, Çanakkale Dental Health Center, Çanakkale (17020), Turkey

²Department of Oral and Maxillofacial Surgery, Faculty of Dentistry, Ataturk University, Erzurum (25040), Turkey

*Corresponding author: alpn.dds@gmail.com

Abstract Supernumerary molar teeth rarely occur in the general population. Their presence particularly in the mandible is rarer. The present study summarizes some retrospective studies on Turkish population with distomolar teeth, presents four cases with mandibular distomolar teeth and the administered treatments. Clinically and radiologically accurate identification of teeth is essential to early diagnosis of distomolar teeth. Although supernumerary teeth occur asymptotically in most cases, impacted ones may cause such pathological phenomena as pain, infections, diastema, neuralgiform pains, root resorption of adjacent tooth, or dentigerous cyst. Therefore, early diagnosis of these teeth highly matters for a successful treatment.

Keywords: *supernumerary teeth, retrospective, distomolar, mandible*

Cite This Article: Alpin Değirmenci, Ertan Yalçın, and Gelengül Gürbüz Urvasızoğlu, “An Overview of Retrospective Studies on Distomolar Teeth in Turkish Population and 4 Case Reports.” *International Journal of Dental Sciences and Research*, vol. 6, no. 5 (2018): 118-123. doi: 10.12691/ijdsr-6-5-2.

1. Introduction

Supernumerary teeth are also referred to as teeth or tooth-like substance exceeding the typical number of permanent or deciduous dentition [1]. Supernumerary teeth are very often observed in permanent dentition and maxilla [1]. They are named according to their locations and morphologies. The ones observed in the maxillary central line are called mesiodens. Teeth distal to the third molar tooth are referred to as distomolar (fourth molar tooth), supernumerary teeth in the first and second molar tooth space as paramolar, and the ones in the first and second premolar space as preparamolar [1,2,3].

They are the most common maxillary mesiodens. Maxillary distomolars are the most frequent second phenomena while maxillary paramolars are the third, mandibular parapremolars the fourth, maxillary laterals the fifth, mandibular distomolars the sixth, and maxillary parapremolars the seventh [1,3,4,5,6].

Distomolars are localized between the third molar teeth and mesiodistally squeezed [7]. They generally cannot erupt due to lack of spaciousness and are observed along with such complications as impeded/delayed eruption, diastema, malposition of adjacent tooth, pericoronitis, dentigerous cyst, neoplasia, neuralgia of trigeminal nerve, and cavity [4,8]. Stafne and Tochihara report frequency rates of 2% and 0.9%, respectively, concerning the occurrence of mandibular distomolar in all the impacted teeth cases [9]. Since distomolars are mostly unerupted and asymptomatic, clinicians should be cautious of probable distomolars in the event of pain and infection in the molar space [10,11,12,13,14].

Environmental and genetic factors play crucial parts in the etiologies of supernumerary teeth [15,16,17,18,19]. Thus, there could be some racial differences across populations. [20] The present study is intended to present a brief summary of some retrospective studies on the Turkish population with distomolar teeth and four case reports to contribute to the available literature. No syndrome has been observed in any of the patients in the case series. Informed consents have been received from each patient before the operations.

2. Case Reports

2.1. Case Report 1

A 20-year-old female patient with a complaint of pain in the right mandibular posterior region was admitted to the clinic. Although her complaints assessed to result from the third molar teeth, radiological examination revealed that the third molar tooth was impacted and the tooth considered to be the third molar was actually a distomolar tooth. In the left side of the patient, the left third molar and distomolar tooth were observed impacted at the same position (Figure 1). The extraction of the right third molar and distomolar teeth was recommended, but the patient refused the extraction of the third molar teeth due to the possible occurrence of paraesthesia. It was decided that the symptomatic right mandibular distomolar teeth should be removed and the right mandibular third molar teeth would not be extracted but monitored. The examination after two months revealed that the patient had no complaints in the post-operation period and no symptom was observed in the clinical examination. As requested by

the patient, her left distomolar tooth was surgically extracted under local anesthesia in the 2-month-later examination.

2.2. Case Report 2

A 32 - year - old female patient presented to our clinic with swelling and pain in the right mandibular posterior region. In the clinical examination manifested, the right mandibular distomolar tooth was found in the inverted position in the ramus which near to the right third molar tooth (Figure 2). A radiolucent lesion covering the apices of the third right lower molar tooth and the crown of the fourth molar tooth was observed. Under general anesthesia, right mandibular third and fourth molar teeth were surgically removed and curettage of the lesion was performed. Pathological examination was confirmed the lesion as a radicular cyst. The patient recovered after the operation not to have any complaints

2.3. Case Report 3

A 20-year-old patient presented to our clinic with pain in the left mandibular region. The clinical examination revealed that the cause of the pain was left mandibular third molar teeth. During radiological examination a radiopaque mass was identified near to the erupted right

mandibular third molar tooth (Figure 3). It was concluded from the CT examination that the lesion was the fourth molar tooth with an underdeveloped root linked to the third molar (Figure 4). The patient did not complain about the right lower space and no pathology was observed in the fourth molar tooth. Having refused the surgical operation for the third and fourth right lower molar teeth, it was decided that the patient would be monitored regularly. Symptomatic left mandibular 3rd molar was surgically removed. The examination after one week revealed that the patient had no complaints and no symptom was observed in the clinical examination.

2.4. Case Report 4

A 17-year-old female patient with the complaint of pain in the lower right mandibular region was admitted to the clinic and the conducted examination manifested that she had complaint with the left mandibular third molar. Except for this, two impacted parapremolar teeth with underdeveloped roots in the bilateral mental area and two distomolar teeth, one in the right lower and the other in the left upper quadrant (Figure 5). The symptomatic third molar tooth was extracted. The patient was informed about her supernumerary teeth. Because she had refused the surgical operation, it was decided that the patient would be monitored regularly.

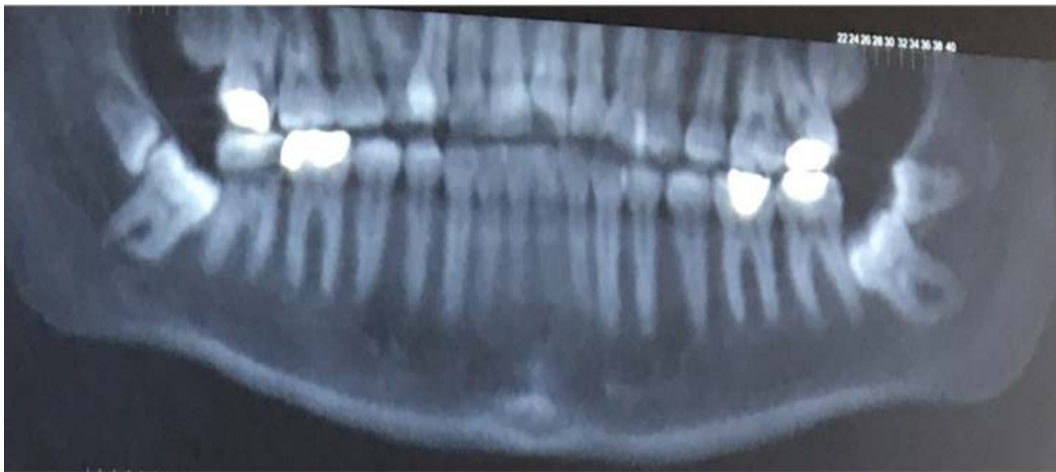

Figure 1.

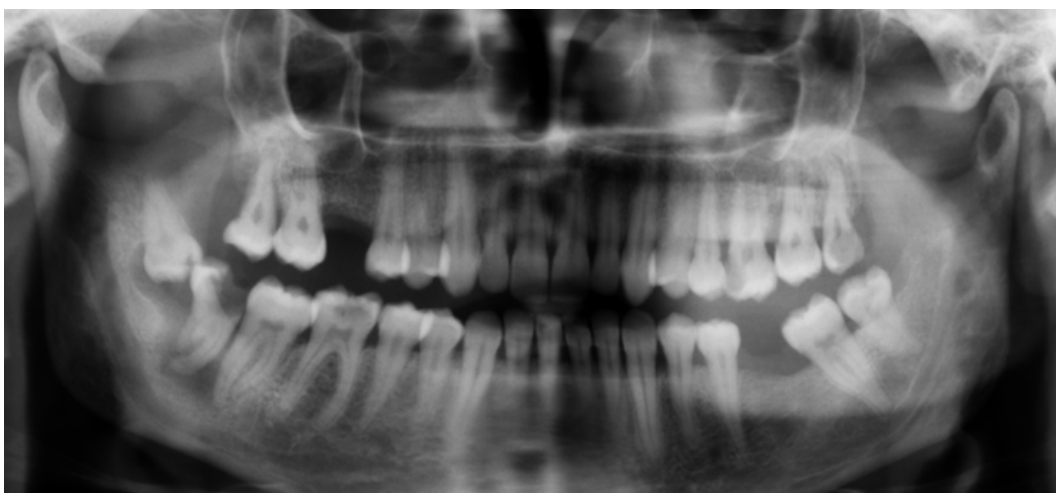

Figure 2.

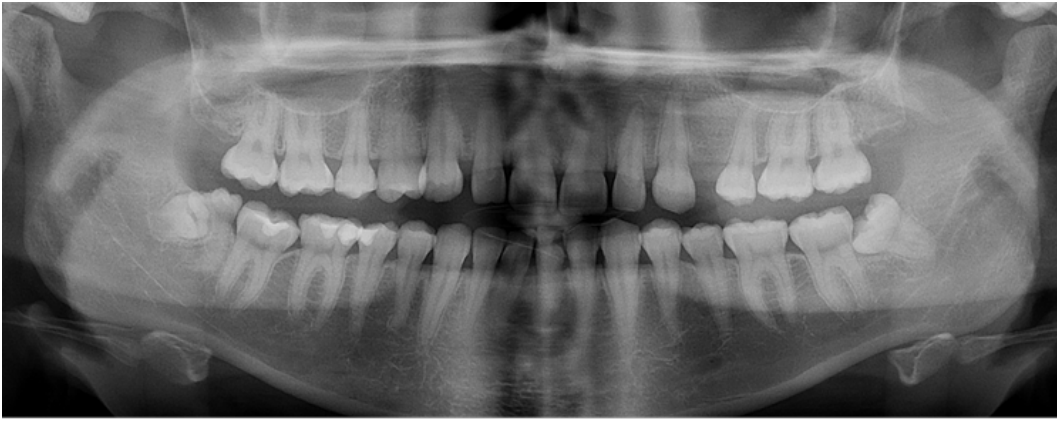


Figure 3.

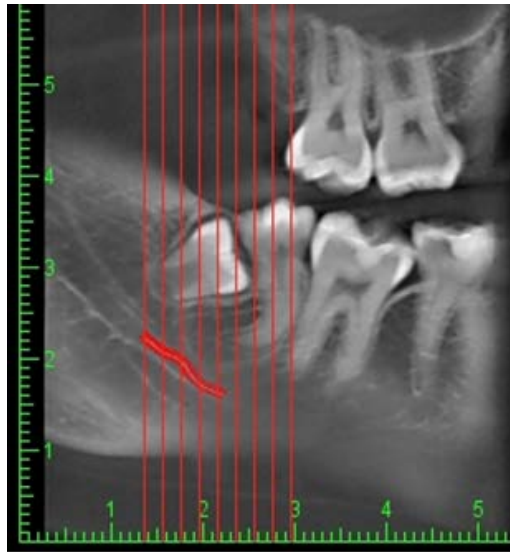


Figure 4.

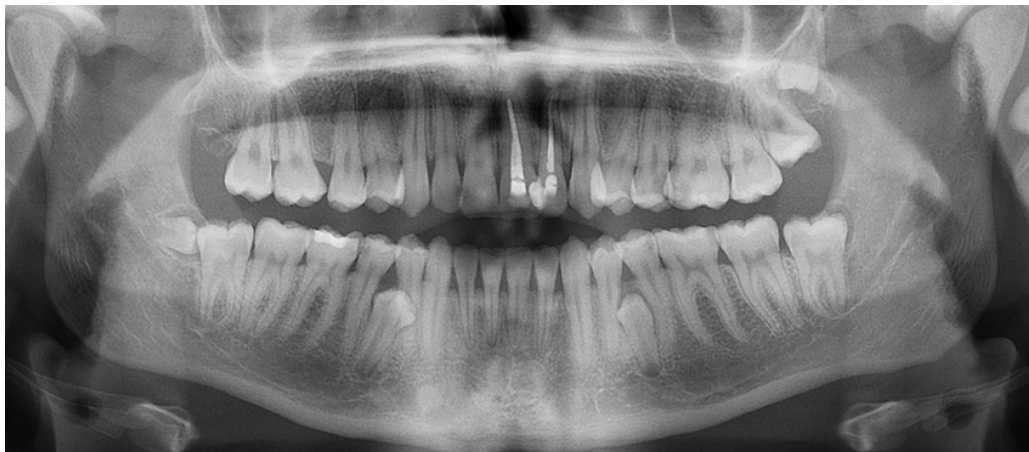

Figure 5.

3. Discussion

The etiology of the supernumerary teeth is not known thoroughly. It is thought that they were present in the mouth of primitive humans and disappeared over time, but re-appear because of environmental or genetic factors, occur due to the continuation of the proliferation of dental laminae forming deciduous and permanent dentition to form the third tooth germ or as a result of the division of permanent tooth germ. [1,10,21] The rates in the population

and the characteristics of supernumerary teeth vary according to the country where the research was conducted (0.38-02.8%) [22-29]. The differences in samples, age groups, ethnicity, and imaging techniques had effects on the prevalence differences [20].

The studies on supernumerary teeth in Turkish population report a prevalence frequency of 0.75-2.3% [20,30-37]. In a great majority of the studies, more supernumerary teeth have been observed in men than in women (1.28/-1.91/1) [20,30,31,32,33,34]. Contrastingly, some studies report no

differences in the rates of male and female participants [35,36,37].

Most of the papers report more supernumerary teeth in the maxilla at a varying range from 58% to 92% [20,30,31,32,33,34,36,37]. Contrastingly Dereci et al. [35] reports more supernumerary teeth in mandible (62%). The author [35] thinks that this difference results from detecting more parapremolar teeth than other studies and the fact that teeth of this kind are mostly observed in mandible [3,38].

The analysis of the frequencies of supernumerary teeth in the studies conducted in Turkey indicated that the most frequently observed supernumerary tooth was parapremolar teeth in three studies [33,35,36], followed by distomolar in two [31,37], and mesiodens in the other studies [20,30,32,34]. There are studies putting mesiodens [31,36], distomolar teeth [30,33], and supernumerary lateral teeth [20,32,37] in the second place. In the studies discussing supernumerary teeth in Turkey, the frequency rate of distomolar teeth range between 1.4% and 55.6%. [31,32,35,36,37]. In some research studies on supernumerary teeth in Turkey, there were no mention of distomolar teeth [34,39,40]. This may have resulted from the age group of patients. Esenlik et al. [39] (6-16 years, 8.6 on average) and Arıkan et al. [40] (3*16 years, 9.53 on average) report no distomolar teeth cases. 80% of the population in Demiriz et al. [34] is under 14 years and they also did not report any distomolar teeth.

Altun et al. [37] refers to a 14-year-old individual as the youngest patient with distomolar tooth. Karayılmaz et al. [20] report 5 (3-18 years) and Dereci et al. [41] one distomolar tooth in a sample of 15.89 years on average.

In the studies on older patient (22-28 years), 31%, 23%, 35%, and 55% of patients were observed to have distomolar teeth. Contrary to this group, Çandırılı et al. [36] identified 20% of distomolar teeth despite the participants at younger ages (avg. 13.39 years).

In the studies only investigating the prevalence of distomolar teeth in various populations, different results between 0.03% and 2.1% were obtained [4,5,42,43,44]. Piatelli and Tete reported the frequency of the distomolar cases in all the cases was calculated to be 0.075% [45]. 10 studies were identified to tackle retrospectively only distomolar teeth in Turkish population and the age average varies between 21 and 36 across the studies. [8,10,11,12,13,14,21,46,47,48] In these studies, 1800 [36], 4 000-6 000 [10,14], 8400 [48], 10 000-14 000 patients [8,11,13,21] were examined and 104.902 patients in a study [47] conducted at seven centers. The total numbers of patients in two studies are unknown [12,46]. While 1.2-1.3 distomolars on average were identified in the studies, it was less than 1.2 in two studies [10,21]. Research studies in Turkey revealed a frequency range between 0.22% and 0.57% in the Turkish population (0.33% [47] 0.17% [48], 0.57% [14], 0.32% [13], 0.22% [11], 0.30% [8], 0.23% [11], 0.34% [10], 0.26% [21]).

The analysis of these studies in consideration of the frequency of distomolar cases in Turkish male and female patients showed similar rates [10,12,21,48] in both genders, but there are a great many studies [8,11,46,47] reporting more women with distomolar cases than men.

The related literature in other countries provides that 75-91% of distomolar teeth are mostly observed in maxilla [4,49]. Similarly, distomolar cases in Turkish population were reported in the upper jaw (69-100%)

[8,10,11,12,13,14,21,46,47]. The analysis of the prevalence of mandibular distomolars in the studies on Turkish population revealed frequency rates of 0.1-0.2% [8,10,14] and 0.03-0.07% [11,21,47,48].

Mostly, distomolar teeth were unilaterally identified. Their bilateral occurrence was rare [21]. The bilateral occurrence of distomolars in the most of the reviewed studies was observed to range between 16- 33% on average [8,10,11,12,21,47]. The rate was found to be much lower 0.06%-0.07% in two studies [13,14] and much higher only Bereket et al. [46] report 59% of bilateral cases.

Supernumerary teeth can be observed along with syndromes such as Gardner syndrome, Ehler-Danlos syndrome, Fabry-Anderson syndrome, Cleidocranial Dysostosis, or Neurofibromatosis type I, but also mostly occur as isolated phenomena in nonsyndromic diseases [1,21,50]. While no other syndrome has been observed in a patient, it is rare that supernumerary teeth occur in abundance or in more than one quadrant [7,16,51]. Liu et al. [52] identified a single supernumerary tooth in 72% of the cases, two in 27%, 3 and more in 0.6%. Moreover, Ferres-padro et al. [53] report a single tooth in 65% of the cases, two in 27%, 3 and more in 6.3%. Yagüe-Garcia et al. [54] diagnosed a single supernumerary tooth in 76-78% of the cases, two in 12-23%, 3 and more in 2-8%. Ezirganlı et al. [31] identified a single supernumerary tooth in 79% of the cases, two in 8%, 3 and more in 11%. Bereket et al. [30] found a single supernumerary tooth in 77% of the cases, two in 18%, 3 in 2.35%, four in 1.41%, 5 in 1.41%, and 7 in 0.23%.

Supernumerary teeth can have a normal dental morphology and a normal tooth size (eumorphic/supplemental) or an abnormal morphology and/or a smaller size (dysmorphic/rudimentary). Rudimentary teeth have conical and tubercular (molariform) sub-types [4,16,47,55]. In a study of 40 cases with distomolar teeth, Gündüz and Çelenk [8] observed smaller distomolars (rudimentary) in 75% of the cases and normal-looking ones (supplemental) in 25%.

Mostly conical supernumerary teeth were observed in the studies [33]. More tubercular and fewer supplemental forms were observed to follow conical forms. In the studies into supernumerary teeth on Turkish population, the studies except for Öztaş et al. [33] report more conical forms than the other forms (42% vs. 29%) [20,30,32,34,41]. The author accounts for this phenomenon with the abundance of supernumerary premolars and the prevalent supplemental form of this tooth type [33]. Likewise, in four studies [10,13,21,47] where the morphological analyses have been conducted, all four present the lowest number of supplemental forms.

Supernumerary teeth were frequently observed impacted (58-79.2%) [30-37]. The impaction rate of distomolar teeth was reported to be 88.7% by Grimanis et al. [7]. While 6 of the Turkish studies indicate that 75% and over stayed impacted, the rate is 64%-69% in 4 studies [12,14,46,48]. Kara et al. [47] morphologically report that 92.1% of tubercular, 84.1% of conical, and all the supplemental distomolar teeth stay impacted. The impacted positions of distomolar teeth are mostly vertical > mesioangular > horizontal > inverted [32,33,47].

In the cases where supernumerary teeth stay impacted, they may lead to narrowing in dentition, delayed eruption,

malposition, cavities or gingival problems and impacted teeth to such pathologies as root resorption, neurosensory disorders by pressurizing neural structures, and dentigerous cyst [10,49,56]. The examination based on the complications originating from distomolar teeth showed such complications as impeded eruption (22,2 % [11], 35 % [48], 54% [8], 40 % [21]), malocclusion (11%) [8], malposition of adjacent tooth (29% [8] - 16% [21]), cavity in adjacent tooth (16%) [21], and pericoronitis (7%) [8].

In the treatments offered in view of all these factors, the extraction of supernumerary teeth leading to complications is recommended, yet asymptomatic teeth not causing complications are periodically monitored. The position of the teeth, numbers, distance to adjacent anatomic structures, and possible surgical complications should be considered in treatment planning [10,13,16,21,46].

In the surgical extraction of mandibular distomolar, surgeon should avoid damaging the adjacent permanent teeth, inferior alveolar artery [1,5,10]. The surgeon also should be remembered that these teeth may have merged with adjacent tooth or teeth [57]. In addition, if follicle or root of the third adjacent molar teeth is damaged during the extraction of distomolar teeth, ankylosis or eruption disorders may arise in the adjacent tooth [12,48,57]. Generally speaking, there is no consensus on the ideal extraction time of supernumerary teeth. Some researchers recommend that root of the adjacent tooth should fully develop [2,58]. Omer et al. [59] report the lowest number of complications when a supernumerary tooth in the anterior region has been extracted at Stage C (of the Demirjian's Classification) but the highest number of complications (root resorption of adjacent tooth, dilaceration, discontinued root development, etc.) when at Stage D, H, and F.

4. Conclusion

The frequency of distomolar teeth in Turkish population has been reported to range between 0.22% and 0.57% in the studies. For the determination of thorough prevalence and teeth's characteristics, more standardized research should be carried out on a larger sample at more centers. The average age group of 14 years and over is more suitable for the identification of distomolar teeth.

The present study offers a general evaluation of and comparison between distomolar teeth in Turkish population and attempts to contribute to the literature with the reported four cases.

Conflicts of Interest

The authors declare that there are no conflicts of interest regarding the publication of this paper.

References

- [1] Regezi JA, S.J., Jordan RC. , *Oral pathology: Clinical Pathologic Correlations*. 6 ed. 2016, USA Elsevier Health Sciences.
- [2] RAJAB L. D., H.M.A.M., *Supernumerary teeth: review of the literature and a survey of 152 cases*. International Journal of Paediatric Dentistry, 2002. 12: p. 244-254.
- [3] Solares R., R.M.I., *Supernumerary Premolars: A Literature Review*. Pediatric Dentistry 2004. 26(5): p. 450-458.
- [4] Arandi, N.Z., *Distomolars: An overview and 3 case reports*. Dental, Oral and Craniofacial Research, 2017. 4(1).
- [5] Kokten G, B.H., Buyukertan M., *Supernumerary Fourth and Fifth Molars: A Report of Two Cases*. J Contemp Dent Pract 2003. November; (4)(4): p. 067-076.
- [6] Çatalbaş B., Ç., A. Gelgör E., *Sürnümerer premolar (parapremolar) dişler: olgu sunumu (Supernumerary premolar (parapremolar) teeth: case report)*. Cumhuriyet Dental Journal, 2011. 14(1): p. 40-43.
- [7] Grimanis, G., A. Kyriakides, and N. Spyropoulos, *A survey on supernumerary molars*. Quintessence international, 1991. 22(12).
- [8] GÜNDÜZ K., Ç.P., *Distomolarlar Üzerine Retrospektif Bir Çalışma (A RETROSPECTIVE STUDY OF DISTOMOLAR TEETH)*. Türkiye Klinikleri J Dental Sci, 2006(12): p. 83-86.
- [9] Sugimura, M., et al., *Mandibular distomolars: a review of the Japanese literature and a report of three additional cases*. Oral Surgery, Oral Medicine, Oral Pathology and Oral Radiology, 1975. 40(3): p. 341-345.
- [10] Şentürk M.F., Y.D., *Distomolar Dişlerin Görülme Sıklığı: Geriye Dönük (Retrospektif) İnceleme (Retrospective Analysis Of Distomolar Frequency)*. Ege Üniversitesi Diş Hek. Fak. Derg., 2017. 38(3): p. 158-163.
- [11] ZENGİN Z., Ç.P., *Distomolarların Retrospektif Olarak İncelenmesi (Retrospective Study of Distomolars)*. Ondokuz Mayıs Üniversitesi Diş Hek. Fak. Derg., 2007. 8(3): p. 174-178.
- [12] BARDAK Ç., Ö.B., AKBULUT N. KURŞUN Ş., *SÜRNÜMERER MOLAR DIŞLERLE İLİŞKİLİ OLARAK RETROSPEKTİF BİR ÇALIŞMA (A Retrospective Study of Supernumerary Molar Teeth)*. A.Ü. Diş Hek. Fak. Derg., 2010. 37(2): p. 77-82.
- [13] Kurt H., S.T.B., Senel B., Avsever H., *A retrospective observational study of the frequency of distomolar teeth in a population of 14.250 patients*. Cumhuriyet Dental Journal, 2015. 18(4): p. 335-342.
- [14] Arslan, A., H. Altundal, and E. Ozel, *The frequency of distomolar teeth in a population of urban Turkish adults: a retrospective study*. Oral Radiology, 2009. 25(2): p. 118.
- [15] Cassetta, M., F. Altieri, and A. Giordano, *Mirror imaging of impacted and supernumerary teeth in dizygotic twins: A case report*. J Clin Exp Dent, 2015. 7(1): p. e167-9.
- [16] Ata-Ali, F., et al., *Prevalence, etiology, diagnosis, treatment and complications of supernumerary teeth*. J Clin Exp Dent, 2014. 6(4): p. e414-8.
- [17] Wang, X.X., J. Zhang, and F.C. Wei, *Autosomal dominant inheritance of multiple supernumerary teeth*. Int J Oral Maxillofac Surg, 2007. 36(8): p. 756-8.
- [18] Ratson T., P.B., *Non-syndromic Multiple Hyperdontia in Monozygotic Twin Sisters: A Report of Two Cases*. Journal of Dentistry for Children, 2014. 81(1): p. 50-53.
- [19] P. Batra, R.D., H. Parkash., *Non-syndromic multiple supernumerary teeth transmitted as an autosomal dominant trait*. J Oral Pathol Med (2005). 34: p. 621-5.
- [20] Karayılmaz, H., Z. Kirzioğlu, and A. Saritekin, *Characteristics of nonsyndromic supernumerary teeth in children and adolescents*. Turkish Journal of Medical Sciences, 2013. 43: p. 1013-1018.
- [21] Kaya, E., et al., *Prevalence and characteristics of non-syndromic distomolars: a retrospective study*. J Invest Clin Dent, 2015. 6(4): p. 282-6.
- [22] Fardi A, K.-S.A., Bachour Z, Parisis N, Tsirlis A., *The incidence of impacted and supernumerary teeth-a radiographic study in a North Greek population*. Med Oral Patol Oral Cir Bucal. , 2011. 16: p. 56-61.
- [23] Berrocal M., M.J., González J., *An observational study of the frequency of supernumerary teeth in a population of 2000 patients*. Med Oral Patol Oral Cir Bucal 2007. 12: p. 134-8.
- [24] G. ALBERTI, P.M.M., V. PARODI, *Eruption of supernumerary permanent teeth in a sample of urban primary school population in Genoa, Italy*. EUROPEAN JOURNAL OF PAEDIATRIC DENTISTRY, 2006. 2: p. 89-91.
- [25] Schmuckli R., L.C.P.T., *Prevalence and Morphology of Supernumerary Teeth in the population of a Swiss Community*. Schweiz Monatsschr Zahnmed 2010. 120(11): p. 987-9.
- [26] Mahabob, M.N., et al., *Prevalence rate of supernumerary teeth among non-syndromic South Indian population: An analysis*. J Pharm Bioallied Sci, 2012. 4(Suppl 2): p. S373-5.

- [27] Fidele, N.B., et al., *Prevalence and Pattern Occurrence of Supernumerary Teeth in the North-East Heilongjiang Population of China*. Open Journal of Stomatology, 2016. 6(02): p. 47.
- [28] Vahid-Dastjerdi, E., et al., *Supernumerary teeth amongst Iranian orthodontic patients. A retrospective radiographic and clinical survey*. Acta Odontol Scand, 2011. 69(2): p. 125-8.
- [29] Jammal Dobles, N. and R. Silva Meza, *Prevalencia de dientes supernumerarios en una muestra mexicana*. Revista Mexicana de Ortodoncia, 2015. 3(2): p. 88-91.
- [30] Bereket, C., et al., *Analyses of 1100 supernumerary teeth in a nonsyndromic Turkish population: A retrospective multicenter study*. Niger J Clin Pract, 2015. 18(6): p. 731-8.
- [31] Ezirganli, S., Ün E., Kirtay M., Özer K., Köşger H.H., *Sivas Bölgesinde Artı Dişlerin Yaygınlığının Araştırılması (The Investigation of Prevalance Supernumerary Teeth in The Sivas Region)*. Atatürk Üniv. Diş Hek. Fak. Derg., 2011. 21(3): p. 189-195.
- [32] Celikoglu, M., H. Kamak, and H. Oktay, *Prevalence and characteristics of supernumerary teeth in a non-syndrome Turkish population: Associated pathologies and proposed treatment*. Medicina Oral Patología Oral y Cirugía Bucal, 2010: p. e575-e578.
- [33] Özataş, B., et al., *Clinical characteristics of non-syndromic supernumerary teeth in a cohort of Turkish patients*. Oral Radiology, 2011. 27(2): p. 108-113.
- [34] Demiriz, L., A. Mısır, and M. Durmuşlar, *The Prevalence and the Characteristics of Supernumerary Teeth of Children and Young Adolescents from North-Western Region of Turkey*. British Journal of Medicine and Medical Research, 2015. 7(5): p. 369-377.
- [35] Dereci Ö, D.İ.M., Ay S., *A retrospective study on demographics and characteristics of the supernumerary teeth in western-central anatolian region*. Cumhuriyet Dent J, 2015. 18(3): p. 265-271.
- [36] Çandırılı, C., et al., *Prevalence and characteristics of supernumerary teeth in east-northern Turkish population*. Cumhuriyet Dental Journal, 2012. 15(4).
- [37] ALTUN O., D.N., YOLCU Ü, UMAR E., *Malatya ve Çevre İllerde Yaşayan Hastaların Süpernumerer Dişlerinin Değerlendirilmesi*. Türkiye Klinikleri J Dental Sci, 2014. 20(3): p. 141-5.
- [38] Menardia-Pejuan V., B.-A.L., Gay-Escodada C., *Supernumerary Molars .A review of 53 Cases*. Int. Rech. Sci.Stomatol Odontol, 2000. 42: p. 101-105.
- [39] Esenlik, E., et al., *Supernumerary teeth in a Turkish population*. Am J Orthod Dentofacial Orthop, 2009. 136(6): p. 848-52.
- [40] Arkan V., O.B., Tulga F., *Prevalence and Characteristics of Supernumerary Teeth in a Child Population from Central Anatolia - Turkey*. Oral Health Dent Manag, 2013. 12(4) : p. 269-72.
- [41] Dereci Ö, D.İ.M., Ay S., *A retrospective study on demographics and characteristics of the supernumerary teeth in western-central anatolian region*. Cumhuriyet Dental Journal, 2015. 18(3): p. 265-71.
- [42] Shahzad, K.M.R., L. E., *Prevalence and management of fourth molars: a retrospective study and literature review*. J Oral Maxillofac Surg, 2012. 70(2): p. 272-5.
- [43] ÖZTÜRK M.H., K.H., POLAT S., AY S., YELER H., *MANDİBULAR DİSTOMOLAR (Vaka Raporu)*. Cumhuriyet Dental Journal, 1999. 2(1): p. 62-63.
- [44] Thomas S.A., S.E., Pillai S.K., *A Study on the Prevalence and Characteristics of Distomolars among 1000 Panoramic Radiographs*. Journal of Indian Academy Oral Medicine and Radiology, 2013. 25(3): p. 169-72.
- [45] Piattelli, A. and S. Tete, *Bilateral maxillary and mandibular fourth molars. Report of a case*. Acta Stomatologica Belgica, 1992. 89(1): p. 57-60.
- [46] BEREKET C., Ç.-Ö.N., ŞENER İ ,TEK M. ,ÇELİK S., *SÜRNÜMERER MOLAR DIŞLERİN RETROSPEKTİF OLARAK İNCELENMESİ: KLİNİK VE RADYOLOJİK BİR ÇALIŞMA (RETROSPECTIVE ANALYSIS OF SURNUMERARY MOLARS: A CLINICAL AND RADIOLOGICAL STUDY)*. Atatürk Üniv. Dis Hek. Fak. Derg. (J Dent Fac Atatürk Uni), 2010. 20(3): p. 176-180.
- [47] Kara, M.I., et al., *Characteristics of 351 supernumerary molar teeth in Turkish population*. Medicina Oral Patología Oral y Cirugía Bucal, 2012: p. e395-e400.
- [48] AKYOL K.U., Ö.-O.B., *Bir Grup Hastada Distomolar Dişlerin ve Sebep Oldukları Patolojilerin Yaygınlığı (Prevalence of Distomolar Teeth and Associated Pathoses in a Group of Patients)*. ADO Journal of Clinical Sciences, 2012. 6(3): p. 1232-1235.
- [49] K., G., *Distomolar olgu bildirimleri*. GÜ Diş Hek Fak Derg, 2007. 24(2): p. 115-118.
- [50] Friedrich, R.E. and A. Reul, *Supernumerary Molars and Wisdom Tooth Shape Alterations in Patients with Neurofibromatosis Type 1*. J Oral Maxillofac Res, 2017. 8(4): p. e5.
- [51] Yusof, W., *Non-syndrome multiple supernumerary teeth: literature review*. Journal (Canadian Dental Association), 1990. 56(2): p. 147-149.
- [52] Liu DG, Z.W., Zhang ZY, Wu YT, Ma XC., *Three-dimensional evaluations of supernumerary teeth using cone-beam computed tomography for 487 cases*. Oral Surg Oral Med Oral Pathol Oral Radiol Endod, 2007. 103: p. 403-11.
- [53] Ferrés-Padró E., P.-A.J., Ferrés-Amat E., *A descriptive study of 113 unerupted supernumerary teeth in 79 pediatric patients in Barcelona*. Med Oral Patol Oral Cir Bucal., 2009. 14(3): p. 146-52.
- [54] Yagüe-García J, B.A.L., Gay-Escoda C., *Multiple supernumerary teeth not associated with complex syndromes: a retrospective study*. Med Oral Patol Oral Cir Bucal, 2009. 14: p. 331-6.
- [55] RAJAB L.D., H.M.A.M., *Supernumerary teeth: review of the literature and a survey of 152 cases*. International Journal of Paediatric Dentistry 2002. 12: p. 244-254.
- [56] Ehsan, D., H.K. Tu, and J. Camarata, *Mandibular supernumerary tooth causing neurosensory changes: a case report*. J Oral Maxillofac Surg, 2000. 58(12): p. 1450-1.
- [57] Gunduz, K., et al., *Concrescence of a mandibular third molar and a supernumerary fourth molar: report of a rare case*. Br Dent J, 2006. 200(3): p. 141-2.
- [58] Rao, P. and M. Chidzonga, *Supernumerary teeth: literature review*. The Central African journal of medicine, 2001. 47(1): p. 22-26.
- [59] Omer S.M., A.R., King N.M., *Determination of the Optimum Time for Surgical Removal of Unerupted Anterior Supernumerary Teeth*. 32, 2010: p. 14-20.