

# Mosaic Double Aneuploidy with Edwards-Klinefelter Syndromes (48,XXY, +18/46XY)

Salil Vaniawala, Pankaj Gadhia\*

Molecular Cytogenetic Unit, S.N. Gene Laboratory and Research Centre, President Plaza-A, Near RTO circle, Surat, India

\*Corresponding author: [pankajgadhia@gmail.com](mailto:pankajgadhia@gmail.com)

Received September 14, 2014; Revised November 21, 2014; Accepted November 27, 2014

**Abstract** Edward syndrome is rare in live births in comparison to most common Down and Patau syndromes. The estimated incidences are one in 6000 live births and interestingly 70 to 80% those affected are females. The occurrence of double aneuploidy involving XXY + 18 is very rare in live born however, most of cases are available with spontaneous abortions. Here, we report a 07 day a male infant with typical features of Edward syndrome such as microcephaly and low set of ears having mosaic double aneuploidy with Klinefelter syndrome.

**Keywords:** double aneuploidy, mosaic, Edward syndrome, Klinefelter syndrome

**Cite This Article:** Salil Vaniawala, and Pankaj Gadhia, "Mosaic Double Aneuploidy with Edwards-Klinefelter Syndromes (48,XXY, +18/46XY)." *American Journal of Medical Sciences and Medicine*, vol. 2, no. 6 (2014): 131-133. doi: 10.12691/ajmsm-2-6-4.

## 1. Introduction

The existence of two chromosomal abnormalities in the same individual is a rare phenomenon. The simultaneous occurrence of double aneuploidies having Edward syndrome (trisomy 18) and Klinefelter syndrome is also rare [1]. It is interesting to note here that during last 10 years (2004 – 2014), we have received 2750 cases of pediatric blood samples for chromosomal analysis. Out of which 682 cases of Down syndrome were recorded [2] and surprisingly only 03 cases of Edward syndrome. With regard to coexistence of mosaic double aneuploidy of Edward and Klinefelter syndromes worldwide, there have been total 14 cases been reported [3], our is 15<sup>th</sup> case where we report a 07 day male infant with Edward syndrome along with mosaicism for XXY.

## 2. Case Report

A 07 day old male infant was referred to our laboratory for chromosome analysis. Physical examination of boy revealed dysplastic low set ear, microcephaly and micrognathia. His both the hands were clenched with broad fingers. The age of mother was 30 years and the father was 32 years at the time of child birth. The child was born following normal gestation and delivery.

## 3. Cytogenetic Findings

Conventional cytogenetic analysis of phytohemagglutinin-stimulated peripheral blood cultures was carried out and were subjected to GTG banding and karyotyping was done according to ISCN (2009) [4]. Out of 50 metaphases, 35 metaphases showed double aneuploidy of Edward and Klinefelter syndrome (Figure 1 & Figure 2). The karyotype of child was 48,XXY, +18 [35]/46, XY [15]. Parental karyotypes were not available.

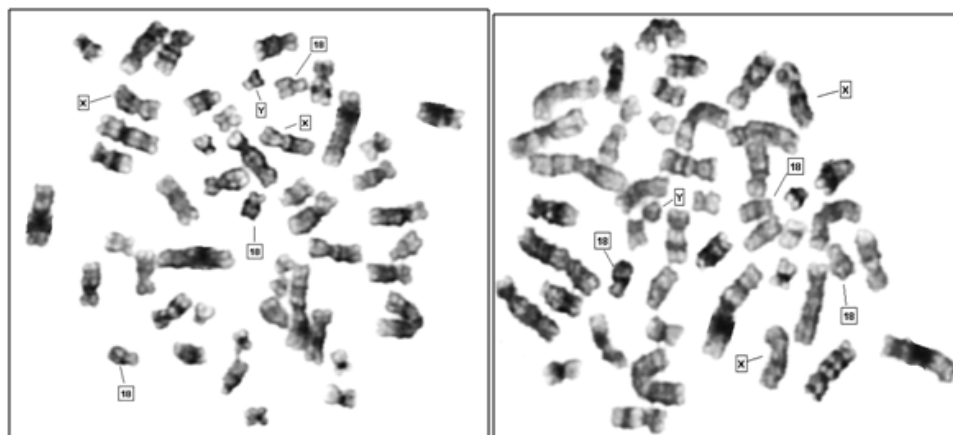


Figure 1. Two metaphase plates showing XXY, +18

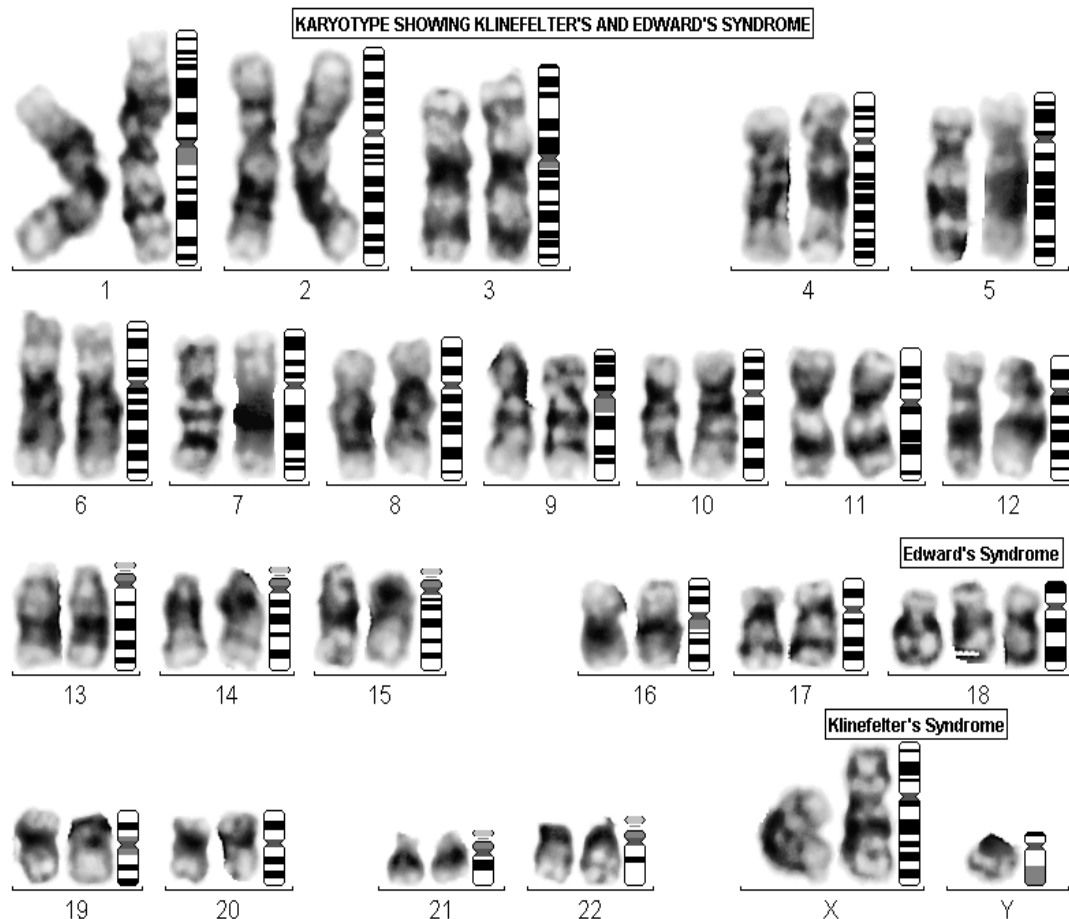


Figure 2. G-banded karyotype showing 48,XXY, +18

#### 4. Discussion

Double aneuploidy is the coexistence of two aneuploidies involving two different chromosomes in a single individual. Occurrence of double aneuploidies is rare than single aneuploidy and hence exact incidences are not known [5]. Double aneuploidy leading to trisomy and/or monosomy of 2 different chromosomes arises because of 2 meiotic non-disjunctional events. Most cases of double aneuploidy in inborn involve the sex chromosome with trisomy 13, 18 and 21 [6]. It is interesting to note here that both aneuploidies have the same or different parental origin.

Kovaleva and Mutton [7] have identified 52 live born cases and 13 prenatal cases and indicated that the frequency of all non-mosaic double aneuploidies except for 48,XXY, +21 are lower than expected, probably because of strong intrauterine selection against such pregnancies.

While scanning through the literature, the incidences of mosaic Edward and Klinefelter syndromes are very low, so total 15 cases have been reported which includes one case from the present study. Our study observed that when two conditions coexist clinical features of Edward syndrome were predominant [8] and it is difficult to diagnose Klinefelter syndrome without karyotyping.

Extra chromosomes in aneuploidies are mostly maternal in origin and usually associated with advanced maternal age rather than genetic predisposition. Furthermore in

double aneuploidies non-disjunction events involving two chromosomes can occur during cell division either in meiosis I and II. The consequences of non-disjunction during meiosis-I and meiosis-II are different.

If error occurs during meiosis-I the gamete with 24 chromosomes contains both the paternal and maternal members of the pair. If it occurs during meiosis-II the gamete with the extra chromosome contains both copies of either paternal or maternal chromosome [9]. On the other hand, trisomy-18 can originate in either of the divisions in both parents.

#### 5. Conclusions

Reporting mosaic double aneuploidy of XXY and 18 shows predominantly clinical characteristics of Edwards syndrome and cytogenetic study confirms mosaic double (48,XXY,+18) aneuploidy. The study also throws light on occurrence of such abnormality which is rare in nature in Western regions of India.

#### Acknowledgements

Authors would like to thank Ms. Avani Kathiriya for her help in analysing data.

#### Statement of Competing Interest

The authors have no competing interests

## References

- [1] Weeraesekara KP, Anjana Sirisena. Coexisting Edward syndrome and Klinefelter syndrome. *Sri Lanka J. Child Helth.* 2013; 42(3): 170-172.
- [2] Gadhia P, Kathiriya A, Vaniawala S. Prevalance of Down syndrome in Western India: A cytogenetic study. *Br. J. Med. Med. Res.* 2014; 5(10): 1255-1259.
- [3] Chen CP, Chern SR, Chen CY, Wu PC, Chen LF et al., Double aneuploidy with Edward-Klinefelter syndrome 48,XXY, +18) of maternal origin: prenatal diagnosis and molecular cytogenetic characterization in a fetus with arthrogryposis of the left wrist and aplasia of left thumb. *Taiwan J. Obst. And Gynecol.* 2011; 50: 479-484.
- [4] International System for Human Cytogenetics Nomenclature (ISCN). S. Karger Publ. Inc. (2009).
- [5] Parihar M, Koshy B, Srivastava M. Mosaic double aneuploidy: Down syndrome and XXY. *Ind. J. Humn. Genet.* 2013; 19(3): 346-348.
- [6] Cyril C, Chandra N, Jegatheesan T, Chanderelekha K, Ramesh A, Gopinath PM, Marimuthu KM. Down syndrome child with 48,XXY, +21 karyotype. *Ind. J. Humn. Genet.* 2005; 11(1): 47-48.
- [7] Kovaleva NV, Mutton DE. Epidemiology of double aneuploidies involving Chromosome 21 and the sex chromosome. *Am. J. Med. Genet.* 2005; 134: 24-32.
- [8] Hou, JW. Double aneuploidy: trisomy 18 and XXY in a boy. *Chang Gung. Med. J.* 2006; 29: 6-12.
- [9] Karman A, Kabalar, E. Double aneuploidy in Turkish child: Down-Klinefelter syndrome. *Congent. Anom. (Kyoto).* 2008; 48: 45-47.