

Giant Prolactinomas: Report of 6 Cases and Review of Literature

Mouna Ammar^{1,*}, Faten hadjkacem¹, Manel Akrouf¹, Ayman Maalej², Nadia Charfi¹, Mohamed Abid¹

¹Department of endocrinology, Hedi Chaker Hospital, Sfax, Tunisia

²Department of radiology, Habib Bourguiba Hospital, Sfax, Tunisia

*Corresponding author: ammar_mouna@hotmail.fr

Abstract Introduction: Giant prolactinomas are rare tumors, representing only 2- 3% of all prolactin (PRL)-secreting tumors. Endocrine symptoms are often present but overlooked for a long period of time. The management of giant prolactinomas remains a major challenge, despite dopamine agonists being the first line of treatment, owing to its efficacy to normalize prolactin levels and reduce tumor volume. **Aim of the study:** Describe clinical and radiological features, the treatment modalities and outcomes of 6 cases of giant prolactinomas and review of the literature. **Methods:** Retrospective data collection involving 6 patients diagnosed with giant prolactinoma in the Department of Endocrinology, Hedi Chaker Hospital, Sfax, Tunisia from January 2010 to December 2014. **Results:** All patients were men between the age of 19 and 65 years. The most common presenting features include headache and visual defects. Proptosis was reported in one patient. Tumor size ranged from 56 to 84 mm and pre-treatment PRL from 1470 to 642387 ng/mL. Endocrine evaluation performed at baseline showed secondary hypogonadism in all patients. Secondary hypothyroidism and adrenal insufficiency were found in one and four patients respectively. IGF-I level was within the normal range for age and gender for all patients. Dopamine agonists served as the primary therapy for all the patients in the present study. Trans-frontal pituitary surgery was performed in one patient with apoplexy and severe neuro-ophthalmic signs. Serum prolactin concentrations and tumor volume significantly decreased following treatment with dopamine agonists. **Conclusion:** Giant prolactinomas are uncommon and often raising both diagnostic and therapeutic challenges.

Keywords: dopamine agonist, giant prolactinoma, pituitary tumor

Cite This Article: Mouna Ammar, Faten hadjkacem, Manel Akrouf, Ayman Maalej, Nadia Charfi, and Mohamed Abid, "Giant Prolactinomas: Report of 6 Cases and Review of Literature." *American Journal of Microbiological Research*, vol. 4, no. 1 (2016): 11-16. doi: 10.12691/ajmr-4-1-2.

1. Introduction

Prolactinomas are benign tumors of the pituitary gland, accounting for 30–40 % of all pituitary adenomas, commonly present as small intra sellar microadenomas in women, but may be much larger in men, presenting as macroadenomas of more than 1 cm in diameter.

Giant prolactinoma is a rare tumor, defined as tumors >4 cm, with very high plasma prolactin levels usually >1000 ng/mL and with clinical symptoms of hyperprolactinemia or mass effect [1]. Giant prolactinomas comprise only 2% of all pituitary tumors in large series [3,4] and much more prevalent in young to middle-aged men, with a male to female ratio of about 9:1 and a mean age around 40 years [3,4,5,6,7].

Endocrine symptoms are often present but overlooked for a long period of time, and diagnosis is made when neurologic complications arise from massive extension into the surrounding structures.

Currently, the management of giant prolactinomas is still a major challenge. Dopamine agonists are the first line treatment, as they effectively normalize PRL levels

and reduce tumor volume [2]. Surgery is indicated for intolerant or resistant cases.

The purpose of this paper is to describe clinical, radiological features, the treatment modalities and outcomes of 6 cases of giant prolactinomas and review of the literature.

2. Case Reports

2.1. Case 1

A 19-year-old male suffered from headache and decreased bilateral vision for 15 days.

The Magnetic resonance imaging (MRI) of the pituitary gland revealed a large pituitary solid –cystic mass measuring 6.4 × 3.8 cm in dimension, with suprasellar, bilateral cavernous sinuses and infratemporal fossa extension. Compression effect over the optic chiasm was also noted.

On physical examination, patient was conscious and coherent. Vital signs were stable. Thyroid examination was normal. He had completed puberty and he reported no history of gynecomastia, galactorrhea or impotence. Medical family history was unremarkable.

Visual acuity was as low as light perception in both eyes. Perimetry examination showed bitemporal hemianopia.

Laboratory evaluations showed prolactin levels as high as 81940.00 ng/mL and further evaluations revealed central hypogonadism and adrenal insufficiency (Table 1).

Extensive giant prolactinoma was diagnosed.

Treatment with bromocriptine gradually increased to 7.5 mg/day and hydrocortisone 20 mg /day was initiated. After 3 days, prolactin levels dropped to 13300.11 ng/mL, with subsequent improvements in vision and headache. Prolactin level decreased to 650 ng/mL after 1 month.

2.2. Case 2

A 19-year-old male presented to the emergency department with vomiting, headache and bilateral ptosis for 5 days.

The MRI showed a giant intra-sellar mass (5.6 × 3.4 cm) with suprasellar and bilateral cavernous sinuses extension and compression of the optic chiasm.

History revealed generalized fatigue, lethargy and headache for 12 months. Physical examination was normal. There was no papilledema on fundus examination but perimetry showed bitemporal hemianopia.

Laboratory investigations showed hyperprolactinemia at (prolactin = 8865.00 ng/mL). Other pituitary work-ups revealed central hypogonadism, secondary hypothyroidism and adrenal insufficiency (Table 1).

Treatment with intravenous hydrocortisone resulted in clinical improvement with no vomiting. Then, the patient started bromocriptine 7.5 mg/day, levothyroxin 75 ug daily and hydrocortisone 20 mg/day.

One month later, prolactin level diminished to 1042.03 ng/mL and tumor size reduced on computer tomography (CT scan) to 4.7 × 3 cm in dimension. The severe frontal headache had subsided. Bromocriptine dose was increased to 10 mg per day. One year after treatment, prolactin level reached to 4.69 ng/mL and ptosis showed significant improvement.

2.3. Case 3

A 47-year-old male presented with sudden severe headache, diplopia and bilateral ptosis.

MRI revealed a giant mass measuring 8.1 × 6.6 × 5 cm in the sellar and suprasellar region with intratumoral hemorrhage invading the sphenoid, bilateral cavernous sinuses and the clivus. The optic chiasm was substantially elevated and displaced. The tumor invaded also the nasopharynx and nasal cavity (Figure 1a).

Physical examination was unremarkable. The patient denied any sexual dysfunction. Perimetry detected bitemporal hemianopia. Laboratory evaluations revealed hyperprolactinemia at 642387.00 ng/mL, central hypogonadism and adrenal insufficiency (Table 1).

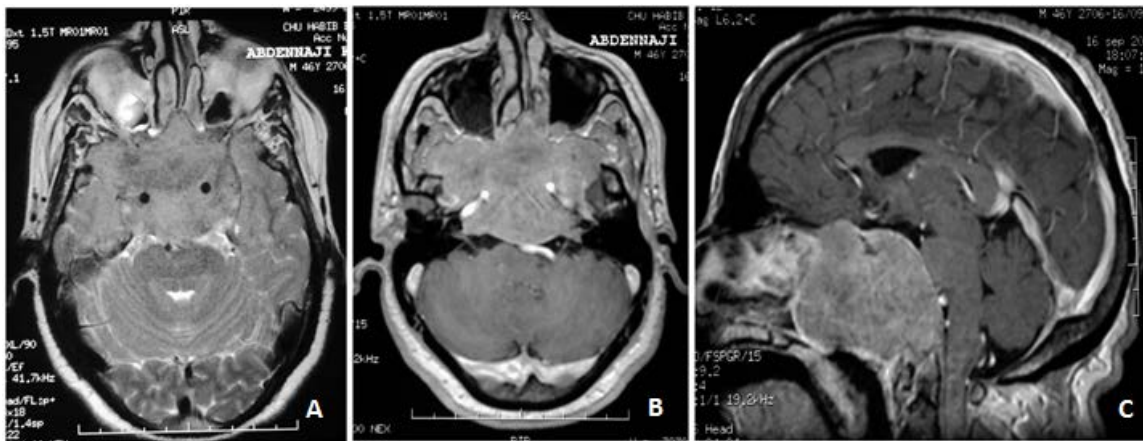


Figure 1a. A (axial T2 weighted image), B (axial T1 weighted post—gadolinium image), C (sagittal T1 weighted post—gadolinium image): giant prolactinoma with invasion of the sphenoid and nasal cavity before treatment

Table 1.

Hormone	Normal range	Case1	Case2	Case3	Case4	Case5	Case6
Prolactin	3.46-20 ng/mL	81940.00	8865.00	642387.00	1470.00	161290.91	11930.71
FSH	0.95-11.95 mUI/mL	1.9	2.3	4.4	3.3	1.7	0.1
LH	0.57-12.07 mUI/mL	1.43	0.46	1.03	0.8	1.64	0.22
Total Testosterone	3-10 ng/mL	1.59	1.16	2.62	0.58	2.01	0.3
Cortisol	50-200 ng/mL	77	<8	130	183	211	110
Cortisol 30 min after ACTH injection		137		156	371	269	147
Cortisol 60 min after ACTH injection		166		172	386	195	162
FT4	9-19 pmol/L	10.3	9.1	13.6	13	14.4	12.38
TSH	0.35-4.94 uUI/mL	0.53	0.37	1.61	0.9	0.71	4.48
IGF- I	age-dependent (ug/L)	249	284	139.7	123.9	162	158.4

The patient was eventually diagnosed with invasive giant prolactinoma with apoplexy. Treatment with cabergoline 1 mg twice weekly and hydrocortisone 20 mg resulted in clinical improvement. Prolactin level decreased

to 4150.84 ng/ml after 3 months and Cabergoline dose increased to 1.5 mg per week. Six months later, prolactin level diminished to 1834.19 ng/mL and tumor size reduced on MRI to 7.4 × 4.1 × 3.8 cm in dimension (Figure 1b).

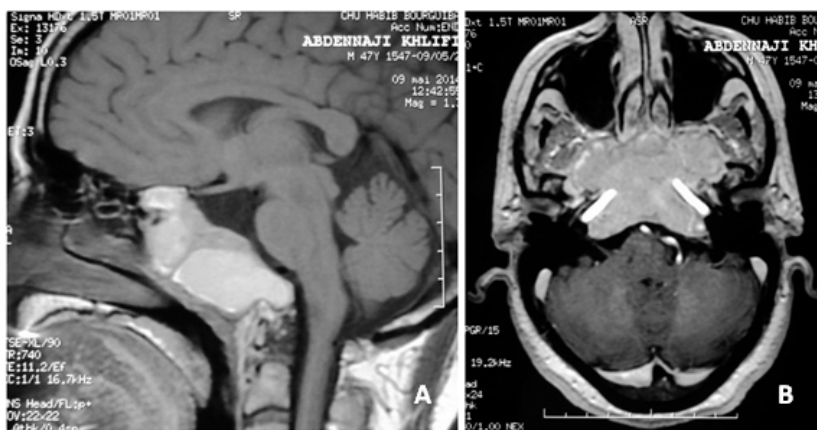

Figure 1b. A (sagittal T1 weighted post—gadolinium image), B (axial T1 weighted post—gadolinium image): Significant tumor shrinkage was induced by cabergoline treatment

2.4. Case4

A 65-year-old married man suffered from headache and blurred vision for 12 months.

The MRI showed a giant heterogeneous intra-sellar mass measuring $5 \times 6.5 \times 4$ cm in dimension with suprasellar extension and compression of the optic chiasm. The tumor invaded the bilateral cavernous sinus with encasement of the internal carotid arteries. Physical examination was unremarkable but history revealed decreased libido for 3 years. Perimetry examination showed bitemporal hemianopia.

Laboratory investigations showed hyperprolactinemia (prolactin = 1470.00 ng/mL) and central hypogonadism (Table 1). Invasive giant prolactinoma with apoplexy was diagnosed. Bromocriptine therapy was prescribed for 1 week but headache and decreased vision didn't show any improvement. A subfrontal craniotomy with removal of tumor was performed. The laterally extending parts of the tumor around the large vessels were not accessible for total resection. Seven days later, the patient's serum prolactin level decreased to 610 ng/ml and severe headache had subsided. The pathology showed a benign prolactinoma. Oral treatment with bromocriptine 7.5

mg/day was initiated. Three months later prolactin level diminished to 465ng/mL and tumor size reduced remarkably on MRI to $3 \times 2 \times 5$ cm in dimension. With increasing the bromocriptine dose to 10 mg/day, the serum prolactin level fell to 58 ng/ml 6 months later.

2.5. Case 5

A 40-year-old married man presented with gradual right-sided retro-orbital pain and proptosis. Examination revealed axial proptosis with a left-sided homonymous hemianopia. Gynaecomastia was noted on systemic examination.

A CT scan of the brain revealed a large enhancing mass centred in the sella and suprasellar regions. The lesion expanded and eroded the dorsum sella and the sellar floor. It extended laterally to invade cavernous sinuses, more prominently on the right side.

A subsequent MRI showed a giant intra-sellar mass ($8.4 \times 6.8 \times 6.4$ cm) with suprasellar and bilateral cavernous sinuses extension. A component of the tumor was noted to extend anteriorly from the right cavernous sinus and invade the right superior orbital fissure (Figure 2a).

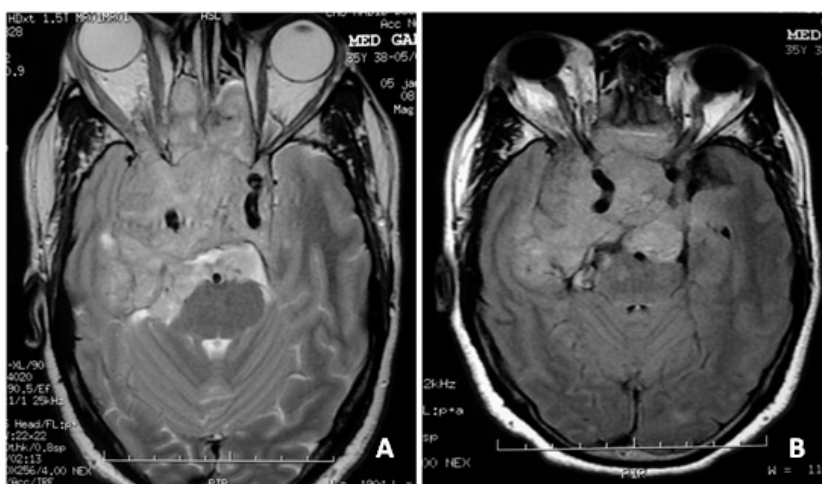


Figure 2a. A (axial T2 weighted image), B (Axial T2-weighted FLAIR image): Giant pituitary tumor with extension anteriorly into the right orbit before treatment

On biochemistry, the serum prolactin level was massively elevated, with a value of just over 161290.91 ng/mL and further evaluations revealed central hypogonadism (Table 1).

Oral treatment with bromocriptine 10 mg/day was initiated. Follow-up imaging 3 months after treatment showed moderate shrinkage of the tumor (Figure 2b) with a partial improvement in visual fields, and was accompanied by a drop in serum prolactin to 41078.27 ng/mL.

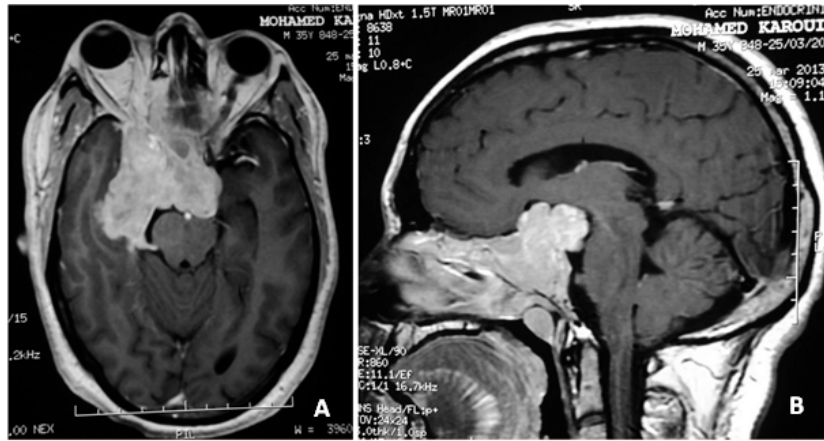


Figure 2b. A (axial T1 weighted post—gadolinium image), B (sagittal T1 weighted post—gadolinium image): Moderate shrinkage of the tumor after 3 months of treatment

2.6. Case 6

A 52-year-old married man presented with a 4-years history of headache with blurred vision and left ptosis for 15 days. MRI was done and revealed a giant mass

measuring 6 × 3.8 × 5 cm in the sellar and suprasellar region invading the sphenoid and both cavernous sinuses (Figure 3a). Compression effect over the optic chiasm was also noted.

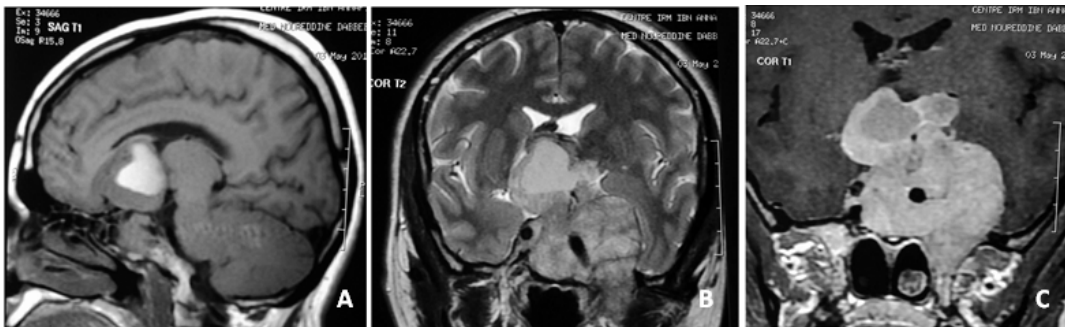


Figure 3a. A (sagittal T1 weighted image), B (coronal T2 weighted image), C (coronal T1 weighted post—gadolinium image): Huge macroprolactinoma with Intra tumoural haemorrhage and invasion of the sphenoid and both cavernous sinuses before treatment

History revealed impotence and decrease libido for 4 years and gynaecomastia was noted on systemic examination.

Perimetry examination showed bitemporal hemianopia.

Laboratory investigations showed hyperprolactinemia at (prolactin = 11930.71 ng/mL), central hypogonadism and adrenal insufficiency (Table 1).

Oral treatment with cabergoline 1 mg twice weekly and hydrocortisone 20 mg /day was initiated. After 1 month

post-treatment, prolactin levels dropped to 778 ng/mL with subsequent improvements in vision and headache. Six months later, prolactin level diminished to 50.58ng/mL and tumor size reduced on MRI to 4 × 4.5 × 5 cm in dimension (Figure 3b). Prolactin level decreased to 15.5ng/ml after 9 months but impotence and decreased libido didn't show any improvement. Testosterone level was 0.42 ng/mL. He was given testosterone (250 mg IM each 3 weeks).

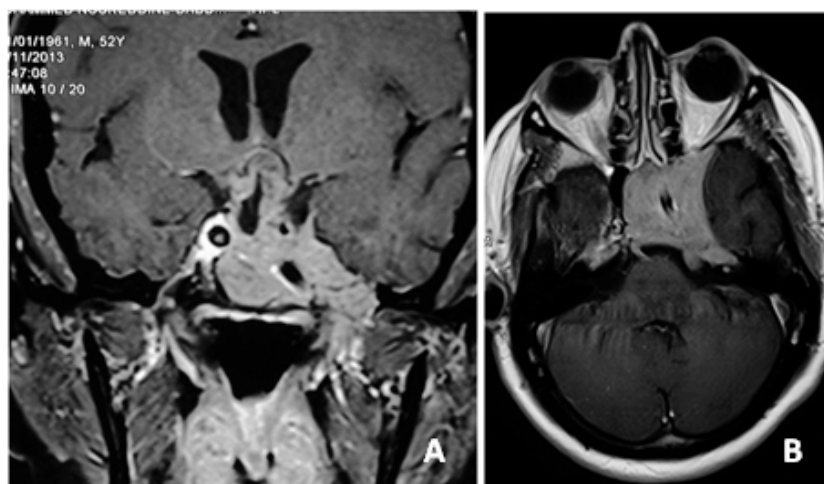


Figure 3b. A (coronal T2-weighted FLAIR image), B (axial T1 weighted post—gadolinium image): six months after treatment; significant tumor shrinkage

3. Discussion

Giant prolactinomas are very rare, representing only 2-3% of all PRL-secreting tumors [3,4]. Typical symptoms of hyperprolactinaemia or pituitary mass are observed in a significant subset of patients but overlooked for a long period of time.

A review of available literature shows that primary or secondary amenorrhoea is reported in more than three-fourths of women with a giant prolactinoma, male hypogonadism in 61%, visual problems and recurrent headaches in 71 and 59% of patients respectively. Data regarding galactorrhoea are often missing and the observed rate of 10% might be underestimated. This feature is rare in men and it is reported in a recent study in 8 of 24 women with a giant prolactinoma (33%), all younger than 50 years.

The presence of hypopituitarism is observed in about one third of patients in whom information is available [8].

Typical presentations are quite frequent and usually reflecting a large tumor extension into the surrounding intracranial structures. Giant prolactinomas frequently invade the sphenoid, ethmoid and/or cavernous sinus or the clivus. Several neurologic symptoms or complications, unusual for pituitary tumors, may be observed. These include impaired hearing [9,10], unilateral hemiparesis [10], temporal epilepsy [11] or dementia due to frontal lobe extension [12].

Hydrocephalus is a rare complication arising from a giant tumor interfering with the flow of cerebrospinal fluid within the ventricular system, most often at the level of the foramen of Monro [13,14,15].

Giant prolactinomas may extend laterally in the cavernous sinus and frequently cause cranial nerve palsies [13,16,17,18].

Orbital invasion is another rare extrasellar extension of pituitary tumors and will cause exophthalmos and optic nerve compression at the orbital apex [1,19,20].

Finally, invasion of the nasopharynx has also been described and will produce nasal stuffiness, snoring and epistaxis [2,9,21,22], and the diagnosis of prolactinoma may sometimes be made through biopsy of a nasal polypoid mass [22,23].

In this report, the most common presenting symptoms in our patients were visual disturbances and non-specific headaches. Proptosis and invasion of the nasopharynx were seen in 1 patient for each.

Giant prolactinomas are usually accompanied by a high serum prolactin concentration, extremely higher up to 50,000–80,000 ng/ml is rare [24,25]. Only one giant prolactinoma with serum prolactin level >100,000 ng/dl is reported [26].

In case 3, the serum prolactin level was massively elevated, with a value of just over 642387 ng/mL. Also, in case 5, serum prolactin level was above 100000 ng/dl.

Because these tumors are commonly invasive with a high possibility of neurological sequelae, the goals of treatment extend beyond the suppression of excessive prolactin secretion to include reducing tumor size and inhibiting tumor growth [27]. Dopamine agonists remain the first-line treatment, as they effectively normalize prolactin levels and reduce tumor volume [2].

In a previous study, 93 % of the patients who were treated with bromocriptine experienced improvement in

their visual symptoms [28]. Similarly in another report, 10 patients with giant prolactinomas treated with cabergoline reported 90 % tumor shrinkage and a complete disappearance of visual defects in 30 % [29]. The rate of prolactin normalization was documented in 5 patients and decreased in 5 patients to a level 3–5 times that of normal, which is consistent with other series in the literature.

Acute and severe neurologic complications of giant prolactinomas are often quickly relieved with Dopamine agonists. There are several reports of rapid resolution under medical treatment alone of proptosis induced by giant prolactinomas [1,19,20].

Dopamine agonists like Cabergoline has shown efficacy in the normalization of testosterone secretion, with two-thirds of patients with giant prolactinomas being biochemically normalized in a recent series [30]. Testosterone supplementation is reserved for patients with hypogonadism despite normal prolactin levels, or in those with hyperprolactinemia and low testosterone despite maximal medical treatment [31].

Our approach is consistent with current standards in which medical treatment with dopamine agonists is the corner stone of management for giant prolactinoma.

Regarding the type of Dopamine agonists, even though there is no proof of a higher efficacy of cabergoline over bromocriptine in the management of giant prolactinomas, cabergoline is certainly better tolerated and generally recommended as first-line treatment.

Finally, medical therapy needs to be maintained almost invariably lifelong in the setting of a giant prolactinoma, even in case of very favorable response.

The morbidity and mortality rates associated with surgical intervention are considerably higher for giant pituitary adenomas than for smaller, non-invasive adenomas [27]. So surgery should be restricted to some acute complications or to resistant patients in which a significant debulking is feasible.

Radiotherapy may be used post-operatively in aggressive and proliferative giant tumors, which are not controlled by Dopamine agonists treatment [32], although there is no prospective study demonstrating its usefulness in this setting.

4. Conclusion

Giant prolactinoma are rare tumors with male preponderance. They are sometimes problematic in the clinical management. Treatment of giant prolactinoma with Dopamine agonists has been observed to provide excellent outcomes in treating extensive prolactinoma with locoregional spread and visual field compromise. Dopamine agonists should therefore be considered as the primary therapy for giant prolactinomas.

Conflict of Interest

None to declare.

References

- [1] Siddiqui A, Chew N & Miszkiel K. Unusual orbital invasion by a giant prolactinoma. *British Journal of Radiology* 2008 81 259-262.

- [2] Cho EH, Lee SA, Chung JY, Koh EH, Cho YH, Kim JH, Kim CJ, Kim MS. Efficacy and safety of cabergoline as first line treatment for invasive giant prolactinoma. *J Korean Med Sci* 2009 24(5) 874-878.
- [3] Shrivastava RK, Arginteanu MS, King WA & Post KD. Giant prolactinomas: clinical management and long-term follow-up. *Journal of Neurosurgery* 2002 97 299-306.
- [4] Corsello SM, Ubertini G, Altomare M, Lovicu RM, Migneco MG, Rota CA & Colosimo C. Giant prolactinomas in men: efficacy of cabergoline treatment. *Clinical Endocrinology* 2003 58 662-670.
- [5] Moraes AB, Silva CM, Vieira Neto L & Gadelha MR. Giant prolactinomas: the therapeutic approach. *Clinical Endocrinology* 2013 79 447-456.
- [6] Delgrange E, Raverot G, Bex M, Burman P, Decoudier B, Devuyst F, Feldt-Rasmussen U, Andersen M & Maiter D. Giant prolactinomas in women. *European Journal of Endocrinology* 2014 170 31-38.
- [7] Schaller B. Gender-related differences in prolactinomas. A clinicopathological study. *Neuroendocrinology Letters* 2005 26 152-159.
- [8] Maiter D & Delgrange E. The challenges in managing giant prolactinomas. *European Journal of Endocrinology* 2014 170 213-227.
- [9] Minniti G, Jaffrain-Rea ML, Santoro A, Esposito V, Ferrante L, Delfini R & Cantore G. Giant prolactinomas presenting as skull base tumors. *Surgical Neurology* 2002 57 99-104.
- [10] Ahmed M & Al-Nozha O. Images in clinical medicine. Large prolactinoma. *New England Journal of Medicine* 2010 363 177.
- [11] Deepak D, Daousi C, Javadvpour M & MacFarlane IA. Macroprolactinomas and epilepsy. *Clinical Endocrinology* 2007 66 503-507.
- [12] Brisman MH, Fetell MR & Post KD. Reversible dementia due to macroprolactinoma. Case report. *Journal of Neurosurgery* 1993 79 135-137.
- [13] Schofl C, Schofl-Siegert B, Karstens JH, Bremer M, Lenarz T, Cuarezma JS, Samii M, von zur Muhlen A & Brabant G. Falsely low serum prolactin in two cases of invasive macroprolactinoma. *Pituitary* 2002 5 261-265.
- [14] Scarone P, Losa M, Mortini P & Giovanelli M. Obstructive hydrocephalus and intracranial hypertension caused by a giant macroprolactinoma. Prompt response to medical treatment. *Journal of Neuro-Oncology* 2006 76 51-54.
- [15] Alkatari S & Aljohani N. Obstructive hydrocephalus, fifth nerve and hypothalamus involvement: acute presentation of a giant prolactinoma. *Clinical Medicine Insights. Case Reports* 2012 5 115-118.
- [16] Chattopadhyay A, Bhansali A & Masoodi SR. Long-term efficacy of bromocriptine in macroprolactinomas and giant prolactinomas in men. *Pituitary* 2005 8 147-154.
- [17] Fleseriu M, Lee M, Pineyro MM, Skugor M, Reddy SK, Siraj ES & Hamrahian AH. Giant invasive pituitary prolactinoma with falsely low serum prolactin: the significance of 'hook effect'. *Journal of Neuro-Oncology* 2006 79 41-43.
- [18] Baldari S, Ferrau F, Alafaci C, Herberg A, Granata F, Militano V, Salpietro FM, Trimarchi F & Cannavo S. First demonstration of the effectiveness of peptide receptor radionuclide therapy (PRRT) with ¹¹¹In-DTPA octreotide in a giant PRL-secreting pituitary adenoma resistant to conventional treatment. *Pituitary* 2012 15 (Suppl 1) S57-S60.
- [19] Berwaerts J, Verhelst J, Abs R, Appel B & Mahler C. A giant prolactinoma presenting with unilateral exophthalmos: effect of cabergoline and review of the literature. *Journal of Endocrinological Investigation* 2000 23 393-398.
- [20] Cackett P, Eunson G, Bath L & Mulvihill A. Proptosis as the presenting sign of giant prolactinoma in a prepubertal boy: successful resolution of hydrocephalus by use of medical therapy. *Future Oncology* 2012 8 1-6.
- [21] Inagawa H, Ishizawa K, Mitsuhashi T, Shimizu M, Adachi J, Nishikawa R, Matsutani M & Hirose T. Giant invasive pituitary adenoma extending into the sphenoid sinus and nasopharynx: report of a case with intraoperative cytologic diagnosis. *Acta Cytologica* 2005 49 452-456.
- [22] Care RH, Sunkaraneni VS, Theaker J & Harries PG. Rapidly progressing giant invasive prolactinoma. *Journal of Laryngology and Otology* 2012 126 840-843.
- [23] Sunil B, Reddy A, Bryant N, Young DW & Ashraf AP. Invasive giant prolactinoma presenting as a nasal polyp. *Journal of Pediatrics* 2013 162-435.
- [24] Grebe SK, Delahunt JW, Feek CM. Treatment of extensively invasive (giant) prolactinomas with bromocriptine. *NZ Med J* 1992 105 129-131.
- [25] Perani D, Colombo N, Scotti G, Tondon C. Rapid size reduction of giant prolactinoma following medical treatment. *J Comp Assist Tomogr* 1984 8 131-133.
- [26] Ariel L, Barkan MD, William F, Chandler MD. Giant pituitary prolactinoma with falsely low serum prolactin: the pitfall of the "High-dose Hook Effect": Case report. *Neurosurgery* 1998 42 913-916.
- [27] Gillam MP et al. Advances in the treatment of prolactinomas. *Endocr Rev* 2006 27(5) 485-534.
- [28] Wu ZB, Yu CJ, Su ZP, Zhuge QC, Wu JS, Zheng WM. Bromocriptine treatment of invasive giant prolactinomas involving the cavernous sinus: results of a long-term follow up. *J Neurosurg* 2006 104(1) 54-61.
- [29] Corsello SM, Ubertini G, Altomare M, Lovicu RM, Migneco MG, Rota CA, Colosimo C. Giant prolactinomas in men: efficacy of cabergoline treatment. *Clin Endocrinol (Oxf)* 2003 58(5) 662-670.
- [30] Shimon I, Benbassat C, Hadani M. Effectiveness of long-term cabergoline treatment for giant prolactinoma: study of 12 men. *Eur J Endocrinol* 2007 156 225-31.
- [31] Davis JR, Farrell WE, Clayton RN. Pituitary tumours. *Reproduction* 2001 121(3) 363-71.
- [32] Yang MY, Shen CC & Ho WL. Treatments of multi-invasive giant prolactinoma. *Journal of Clinical Neuroscience* 2004 11 70-75.