

Large Cervical Osteophytes Mimicking a Hypopharyngeal Neoplasm

Matteo Pezzoli^{1*}, Sebastiano Bucolo¹, Federico Griva², Alessandro Pagliassotto¹

¹ENT Unit, Ospedale San Giovanni Bosco, Turin, Italy

²Neurosurgery Unit, Ospedale San Giovanni Bosco, Turin, Italy

*Corresponding author: ma.pezzoli@libero.it

Received August 03, 2021; Revised September 05, 2021; Accepted September 13, 2021

Abstract Hypertrophic anterior osteophytes of the vertebrae affecting the anterior longitudinal ligament of the spine are typical of diffuse idiopathic skeletal hyperostosis (DISH), a spinal disorder of the elderly also known as Forestier Disease, from the name of the first author who reported it in 1950. Usually, patients are asymptomatic or have mild dysphagia, due to compression of the digestive tract but less commonly can have acute dyspnea requiring to secure the airway has been rarely reported. Diagnosis is usually obtained with radiologic exams that reveal a bony mass. In some cases, fibrosis and inflammation due to the constant movement of the cricoid lamina over a projecting osteophyte are also seen with the CT Scan. In this paper, we describe a distinct entity of a giant lesion of the cervical spine that appeared as a pseudotumor of cervical soft tissue and caused acute upper airway obstruction requiring emergency tracheostomy. Details of his clinical examination, radiologic imaging, and surgical management are provided and discussed.

Keywords: *DISH, Osteophytosis, Tracheostomy, Acute dyspnea*

Cite This Article: Matteo Pezzoli, Sebastiano Bucolo, Federico Griva, and Alessandro Pagliassotto, "Large Cervical Osteophytes Mimicking a Hypopharyngeal Neoplasm." *American Journal of Medical Case Reports*, vol. 9, no. 12 (2021): 705-708. doi: 10.12691/ajmcr-9-12-11.

1. Introduction

Anterior cervical osteophytes can cause dysphagia or odynophagia due to direct compression on the pharynx or upper esophagus. However, the presence of a large cervical osteophyte can also cause respiratory symptoms. We describe a case of a rare case of acute airway obstruction that due to the endoscopic appearance mimicked a neoplasm necessitating an emergent tracheostomy.

2. Case Report

An 81-year-old man presented to the Emergency Department (ED) following the worsening of breathing difficulties which became noisy and had slowly appeared during the 2 months before admission. He also had mild dysphagia particularly for solids without pain. There was no history of recent illnesses. His past medical history included a 65-year history of smoking, long-lasting hypertension and monoclonal gammopathy of undetermined significance under regular follow-up and prostatic adenoma.

On evaluation in the ED physical examination was notable for mild hypertension, a respiratory rate of 26 breaths per minute with 93% of peripheral oxygen saturation; ECG showed sinus rhythm. Arterial blood gas

(ABG) showed mixed respiratory acidosis and metabolic alkalosis. The chest radiograph revealed a mild left pleural effusion. Blood count was normal and the rest of blood test showed a slightly increased protein C-reactive protein (1.1 mg/dl) creatinine (1.3 mg/dl) and d-dimer (1.10 mcg/ml). On examination, the patient had audible inspiratory stridor, mild suprasternal retractions, and no neck masses. The oropharynx was normal.

Fiber-optic laryngoscopy (Figure 1) revealed a mass and a severe protrusion of posterior hypopharyngeal wall with an edematous but intact surface. Vocal cords were not visible due to the mass and patient respiratory distress. Due to a further deterioration in his respiratory status an emergent tracheostomy was performed under local anesthesia. Once secured the airway a computed tomography scan and an MRI of the neck were obtained, revealing a large anterior cervical osteophyte extending from C3 to C5 with a hypodense soft tissue mass with mild contrast enhancement of 2,5 cm extending anteriorly to the vertebrae (Figure 2 and Figure 3).

A direct microlaryngoscopy was planned and biopsies were performed at the level of posterior pharyngeal mass. The patient was placed on a course of steroid treatment waiting for the anatomopathological examination, which revealed inflammatory proliferative changes with no evidence of malignancy. The patient was re-evaluated by flexible laryngoscopy that did not reveal improvement of the mass protruding in the airway.

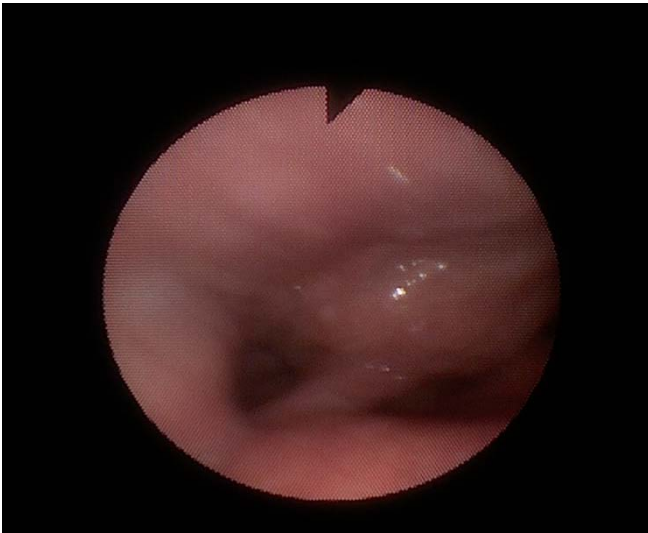

Figure 1. Endoscopic image showing the protruding mass

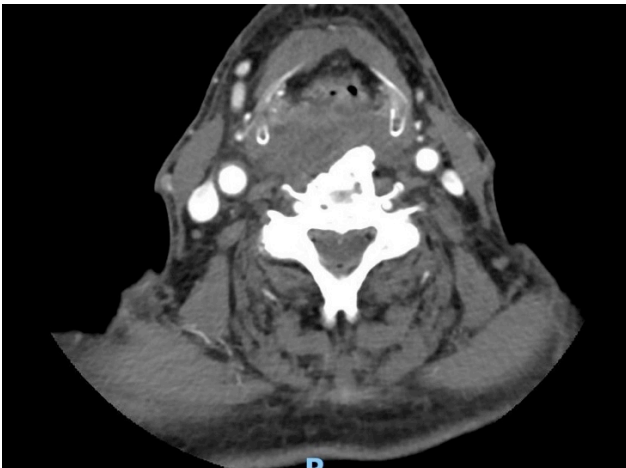

Figure 2. CT Scan of the neck

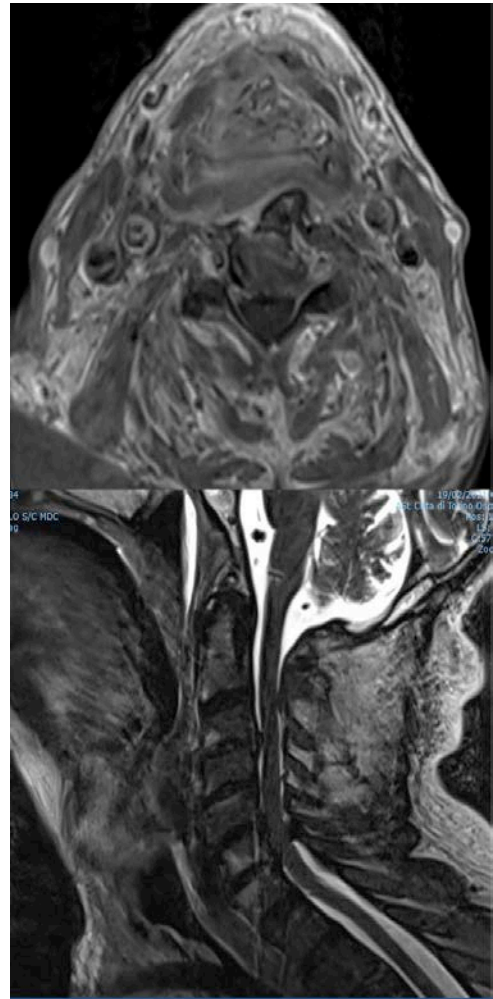
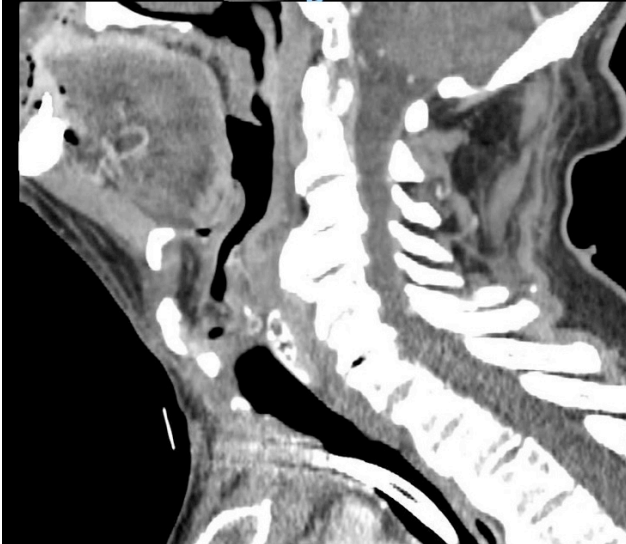


Figure 3. MRI Scan of the neck

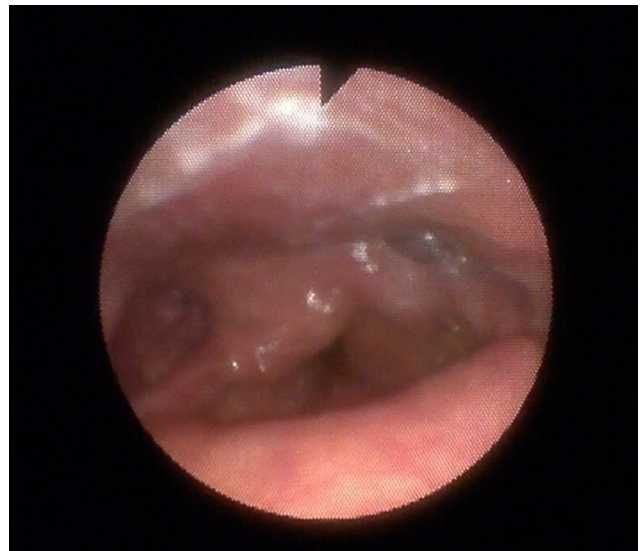


Figure 4. Post treatment endoscopic image

3. Differential Diagnosis

Dysphagia associated with dyspnea is a common symptom presentation and the differential diagnoses are various. When the onset is rapid is crucial to rule out acute airway obstruction. ENT examination should include a fiber optic to obtain a preliminary insight on the cause and the need for emergency tracheotomy. Once the airway was secured a CT scan was ordered showing cervical osteophytosis but also a pharyngeal mass. Since the patient was not septic at presentation an infective cause was ruled out and biopsies were planned in the hypothesis of a neoplastic lesion, especially in consideration of the fact that CT scan showed aspects that were compatible with a mesenchymal tumor of the larynx. Because of the rapid onset of symptoms osteophytes were overlooked as the primary cause as long as pathologist did not conclusively rule out a neoplastic lesion.

4. Treatment and Follow up

Resection of the osteophytes under general anesthesia was planned. The patient underwent surgery with a lateral cervical approach . The patient underwent surgery with a right-sided anterolateral cervical approach and the osteophytes from C3 to C5 were removed under fluoroscopy control with Kerrison and a high-speed drill. A deep drain was then placed and the wound closed in anatomic layers. The patient was discharged under a course of systemic antibiotics with the tracheostomy tube. Three weeks after surgery, fiberoptic laryngoscopy demonstrated normal mobility of both vocal folds and improved airway with reduction of supraglottic edema (Figure 4). The tracheostomy tube was removed with saturations remaining 97% on room air. The patient was re-evaluated after one month and did not report airway obstruction, however, complained of noisy respiration especially during nighttime. On examination with flexible endoscopy there was no airway obstruction, a mucosal fold, vibrating during heavy inspiration, was noted at the site of the previous bulge. Excision with diode laser was planned. Two months later the fiberoptic examination was normal and the patient did well.

5. Discussion

The patient reported in this paper had a lesion of the hypopharynx that required immediate tracheostomy. Ct scan was planned after airway was secured and showed a mass, without significant contrast enhancement, anterior to an osteophyte originating from third, fourth and fifth cervical vertebrae. The soft tissue mass measured 2,5 cm on the anteroposterior projection and caused a reduction of the airway at the level of the hypopharynx. Due to the acute presentation of symptoms and the endoscopic picture the hypothesis of a submucosal neoplasm was done. Endoscopy disclosed what was thought to be a neoplasm involving the hypopharynx and the larynx. The ct scan showed a soft tissue mass anterior to the cervical

spine that was prominent with respect to the abnormal ossification of the cervical spine which was thought to be an incidental finding, as cervical osteophytosis is found in approximately 20–30% of the elderly [1]. In the majority of these patients, bony spurs are asymptomatic or associated with neck stiffness and localized or radiating pain [2]. However, large osteophytes that impinge on the pharynx or upper esophagus . have been found to cause dysphagia, odynophagia, and globus symptoms [1,3]. Resnick et al. [4] coined the term "diffuse skeletal hyperostosis, (DISH)" to describe these prominent bridging osteophytes of the cervical and lumbar spine. They found that dysphagia was the most common presenting symptom, probably due to direct mechanical compression of the digestive tract or mechanical irritation of the retrocricoid area or cricopharyngeal spasm caused by mucosa rolling over the bony spurs at each swallow [5]. Chronic irritation is probably responsible for the soft tissue fibrosis that simulated a neoplasm. In our case, the soft tissue mass mimicked a tumor and the presence of the osteophytes was overlooked and considered an incidental finding.

Even if rare, acute airway compromise were described in previous reports and thought to be derived from extraluminal osteophytic masses obstructing directly the supraglottic airway [6] or such in our cases due to inflammatory and fibrotic laryngeal involvement [7,8].

When symptoms are severe and there is airway obstruction surgical treatment is indicated. We choose to perform surgery via the anterior approach [9] due to more familiarity with the anatomy of this area, however, also transpharyngeal approaches were described [10].

Our patient had complete resolution of the symptoms following treatment and a successful decannulation was possible shortly after surgery, however, we must be aware of potentially severe complications of surgical treatment such as hematoma, Horner syndrome, recurrent nerve palsy, superior laryngeal nerve palsy, and esophageal injury [8].

References

- [1] Bone RC, Nahum AM, Harris AS. Evaluation and correction of dysphagia-producing cervical osteophytosis. *Laryngoscope*. 1974; 84: 2045-2050.
- [2] Hardin JG, Halla JT. Cervical spine and radicular pain syndromes. *Curr Opin Rheumatol* 1995; 7: 136-140.
- [3] Saffouri HH, Ward PH: Surgical correction of dysphagia due to cervical osteophytes. *Ann Otol Rhinol Laryngol*. 83: 65-70, 1974.
- [4] Resnick D, Shaul SR, Robins JM. Diffuse idiopathic skeletal hyperostosis (DISH): Forestier's disease with extraspinal manifestations. *Radiology* 1975; 115: 513-524.
- [5] Giger R, Dulguerov P, Payer M. Anterior cervical osteophytes causing dysphagia and dyspnea: an uncommon entity revisited. *Dysphagia* 2006; 21: 259-63.
- [6] Dagher W, Nasr V, Patel AK, Flis D, and Wein R. An Unusual and Rare Cause of Acute Airway Obstruction in the Elderly: Forestier's Disease. *Journal of Emergency Medicine*, 46 (2014), 617-19.
- [7] Sobol SM, Rigual NR. Anterolateral extrapharyngeal approach for cervical osteophyte-induced dysphagia; literature review. *Ann Otol Rhinol Laryngol* 1984; 93: 498-504.
- [8] Ohki M. Dysphagia due to diffuse idiopathic skeletal hyperostosis. *Case Reports in Otolaryngology*. 2012; 2012: 123825.

- [9] Carlson ML, Archibald DJ, Graner DE, et al. Surgical management of dysphagia and airway obstruction in patients with prominent ventral cervical osteophytes. *Dysphagia* 2011; 26: 34-40.
- [10] S. Uppal and A. H. Wheatley, "Transpharyngeal approach for the treatment of dysphagia due to Forestier's disease," *Journal of Laryngology and Otology*, vol. 113, no. 4, pp. 366-368, 1999.



© The Author(s) 2021. This article is an open access article distributed under the terms and conditions of the Creative Commons Attribution (CC BY) license (<http://creativecommons.org/licenses/by/4.0/>).