

A Case of Pulmonary Alveolar Hemorrhage Mimicking Community Acquired Pneumonia

Caleb V Wutawunashe, Kourosh Shargani*, Anu Menon

Northwell Lenox Hill Hospital, New York, NY. 100 E 77th St, New York, NY 10075, USA

*Corresponding author: Kshargani@northwell.edu

Received May 27, 2021; Revised July 03, 2021; Accepted July 12, 2021

Abstract Granulomatosis with polyangiitis is a vasculitis that affects small to medium sized blood vessels in the lungs and kidneys. Alveolar hemorrhage is often initially misdiagnosed as pneumonia and treated incorrectly, leading to higher adverse outcomes in patients with undiagnosed vasculitis. We describe a case of a 68-year-old female who presented to our institution and was initially diagnosed and treated for community acquired pneumonia, however, after a protracted clinical course with no improvement in her respiratory status, she underwent a bronchoscopy that revealed pulmonary alveolar hemorrhage, a manifestation of underlying granulomatosis with polyangiitis.

Keywords: *granulomatosis with polyangiitis, pulmonary alveolar hemorrhage, pneumonia, granulomatosis with polyangiitis*

Cite This Article: Caleb V Wutawunashe, Kourosh Shargani, and Anu Menon, "A Case of Pulmonary Alveolar Hemorrhage Mimicking Community Acquired Pneumonia." *American Journal of Medical Case Reports*, vol. 9, no. 11 (2021): 535-537. doi: 10.12691/ajmcr-9-11-4.

1. Introduction

Granulomatosis with polyangiitis is a vasculitis that affects small to medium sized blood vessels in the lungs and kidneys. One of the major pulmonary complications is alveolar hemorrhage. Alveolar hemorrhage has both high morbidity and mortality and requires aggressive treatment. Alveolar hemorrhage is often misdiagnosed as pneumonia and treated incorrectly, leading to higher adverse outcomes in patients with undiagnosed vasculitis.

2. Case Presentation

A 68-year-old female with a past medical history of Crohn's Disease and a recent hospital admission for COVID-19 pneumonia presented to the emergency room (ER) for evaluation of shortness of breath and productive cough for 1 week. She reported that her symptoms started during an outpatient pulmonary function test (PFT) during which she believed that she may have aspirated. In the ensuing days, her symptoms progressed to include myalgias, congestion, and streaks of blood in her sputum. She trialed ibuprofen, with little symptomatic relief, and, subsequently, called her primary care physician, who instructed her to go to the ER for evaluation. On presentation, she was afebrile with a heart rate of 104 beats per minute, a blood pressure of 180/85 mmHg, a respiratory rate of 22 breaths per minute, and an oxygen saturation of 91% on room air. Her physical exam was pertinently significant for left sided

crackles without wheezing or rhonchi on auscultation. Her lab studies were significant for a white blood cell count of 13.9, a hemoglobin level of 8.9, a procalcitonin level of 0.16, a c-reactive protein (CRP) level of 19, and a D-dimer level of 528. Urinalysis was notable for trace protein and few red blood cells. CT Chest revealed a left lobar pneumonia with slight interval increase in extent of areas of lung fibrosis, suspected sequelae of prior COVID-19 (Figure 2 and Figure 3). She was started on Ceftriaxone and Azithromycin for treatment of community acquired pneumonia (CAP). She was subsequently admitted to the hospital for management of acute hypoxic respiratory failure and sepsis secondary to CAP. On the second day of her hospitalization, her urine legionella and streptococcal antigen were negative. She continued to have episodes of hemoptysis with no clinical improvement in her respiratory status. She underwent a bronchoscopy with a broncho-alveolar lavage (BAL) on the third day of her hospitalization. The procedure was complicated by an episode of hemoptysis that caused her hemoglobin to drop below 7.0 post procedure. She received a unit of packed red blood cells for acute blood loss anemia and was transferred to the medical intensive care unit for closer monitoring. The results of the BAL were negative for pneumocystis, acid fast bacterium, fungal and bacterial organisms. An autoimmune panel was sent, and a Rheumatology consult was called after her serum antineutrophilic cytoplasmic antibody (c-ANCA) returned positive. A CT of her head performed prior to discharge illustrated nasal ulceration. The patient was subsequently started on an intravenous steroid regimen and remained hemodynamically stable in the MICU for two days,

requiring high flow nasal cannula that was successfully weaned down to nasal cannula. The patient was transitioned to an oral steroid regimen after her clinical

status improved and was stepped down to the regional medical floor with a plan to discharge with outpatient Rheumatology follow up.

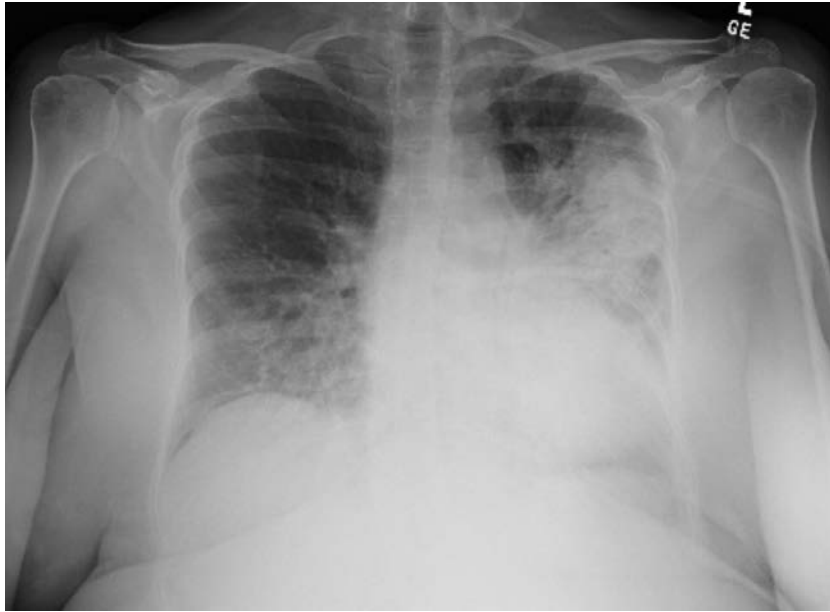

Figure 1. Chest radiograph on initial presentation

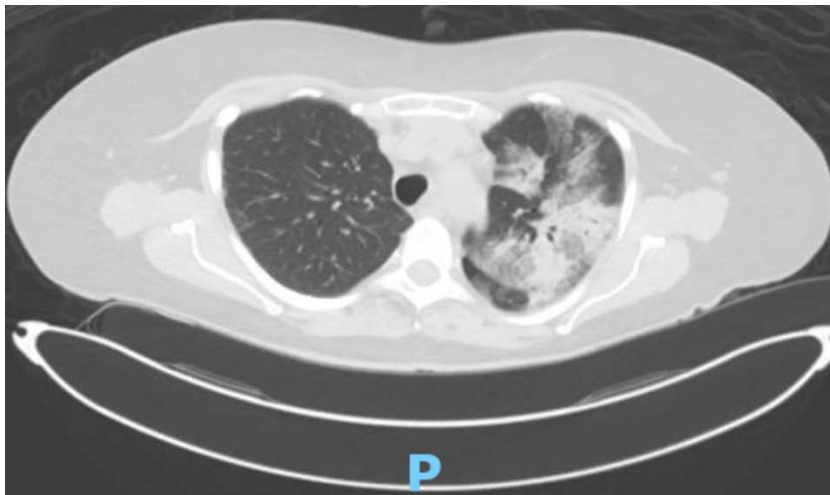

Figure 2. Computer tomography (CT) of the chest without IV contrast on initial presentation

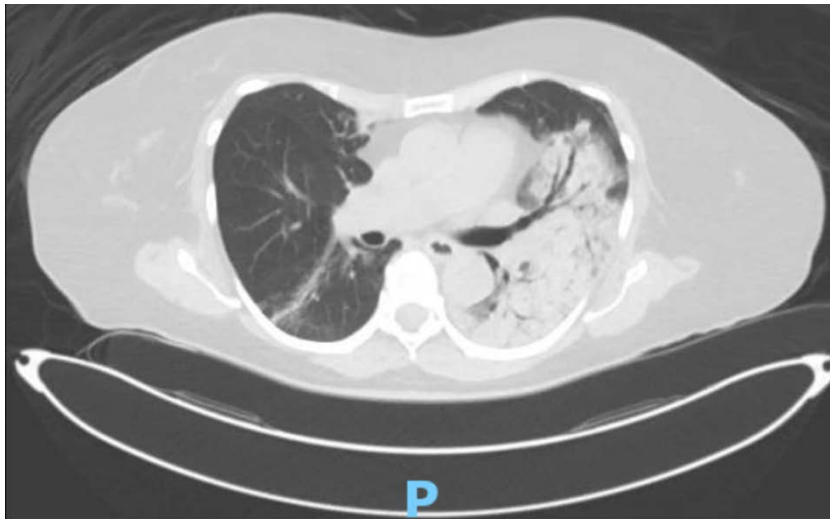


Figure 3. Computer tomography (CT) of the chest without IV contrast on initial presentation

3. Discussion

Granulomatosis with polyangiitis is one of the most common causes of alveolar hemorrhage, typically affecting those between 30 to 50 years old. The incidence is estimated to be between 8 to 10 cases per million annually [2]. Pulmonary hemorrhage may appear as infiltrates or cavitation on chest x-ray, which can be mistaken for pneumonia [3]. Hemoptysis may be absent with alveolar hemorrhage as the alveoli can absorb a significant amount of blood before reaching the large airways [2], thus making the diagnosis more difficult. CT is thought to be more sensitive than X-ray in differentiating pulmonary hemorrhage from other causes. Usually, the diagnosis is made when the patient does not improve on antibiotics [1]. Once pulmonary hemorrhage is identified and suspected to be due to Granulomatosis with polyangiitis, the standard of treatment is with steroids, immunosuppressants, and plasmapheresis. The combination of cyclophosphamide and methylprednisolone induces

remission in about 80% to 90% of patients with ANCA-associated vasculitis, with 75% experiencing complete remission within 2 to 6 months [2]. It is important to recognize that alveolar hemorrhage from undiagnosed Granulomatosis with polyangiitis can mimic pneumonia and lead to delay in diagnosis and treatment due to the non-specific presenting clinical features.

References

- [1] Black, A.D. *Non-infectious mimics of community-acquired pneumonia. pneumonia.* 8, 2 (2016).
- [2] Lababidi MH, Odigwe C, Okolo C, Elhassan A, Iroegbu N. *Microscopic polyangiitis causing diffuse alveolar hemorrhage and rapidly progressive glomerulonephritis. Proc (Bayl Univ Med Cent).* 2015; 28(4): 469-471.
- [3] Spalding SJ, Cambria M, Arkachaisri T. *Distinguishing Wegener's granulomatosis from necrotizing community acquired pneumonia: A case report and comparison of radiographic findings. Pediatr Pulmonol.* 2009; 44(2): 195-197.



© The Author(s) 2021. This article is an open access article distributed under the terms and conditions of the Creative Commons Attribution (CC BY) license (<http://creativecommons.org/licenses/by/4.0/>).