

Cervical Teratoma: A Rare Neck Swelling in an Adult

Sze Li Siow*, Hans Alexander Mahendran

Department of Surgery, Sarawak General Hospital, Jalan Hospital, 93586, Kuching, Sarawak, Malaysia

*Corresponding author: szeli18@yahoo.com

Received January 20, 2015; Revised January 30, 2015; Accepted February 03, 2015

Abstract Cervical neck teratoma in adult is rare. It has a distinctly different clinicopathological behavior compared to those of the neonate and infant. We report an 18-year-old man who presented with a benign cervical neck teratoma, and present a review of cervical neck teratoma in the literature. Surgery is the primary modality of treatment as malignant transformation occurs during adulthood. The diagnosis of malignancy is based on histopathologic examination. Adjuvant chemotherapy is indicated when malignancy is confirmed.

Keywords: *teratoma, adult, cervical neck, surgery*

Cite This Article: Sze Li Siow, and Hans Alexander Mahendran, "Cervical Teratoma: A Rare Neck Swelling in an Adult." *American Journal of Medical Case Reports*, vol. 3, no. 3 (2015): 75-78. doi: 10.12691/ajmcr-3-3-6.

1. Introduction

Cervical teratomas are uncommon pathological entities that are usually diagnosed at birth and rarely reported in older children and adults. We report a mature cervical teratoma in an adult and offer a brief review of the literature.

2. Case

An 18-year-old teenage male presented with a 4 months history of a progressive anterior midline neck swelling. There was no associated dysphagia, shortness of breath or hoarseness of voice. He had no prior surgery or irradiation to his neck and he was clinically and biochemically euthyroid.

Clinical examination showed a firm, oval-shaped mass that had a smooth surface in the midline of the anterior neck. The lesion measured 4x5 cm and moved with swallowing and protrusion of tongue. There were no

palpable cervical lymph nodes and the rest of his physical examination was otherwise unremarkable.

Ultrasonography of the neck findings revealed a midline tubular structure that ended in a well-defined cystic structure separate from the thyroid gland suggestive of a thyroglossal cyst. The thyroid gland had a few subcentimeter nodules in the left thyroid gland that were homogenous in appearance. He was counseled for a Sistrunk procedure with a left hemithyroidectomy.

A neck collar skin crease incision with elevation of subplatysmal flaps followed by retraction of the strap muscles laterally revealed a tubular structure extending from the hyoid bone extending inferiorly in the pretracheal plane. This tubular structure measuring 5cm in length, ended in a lobular mass that was located anterior to the left thyroid gland (Figure 1), distinctly separate from the gland and extended to the retrosternal area. Post-operatively, he was well with no haematoma or wound infection. He was discharged without complication uneventfully on the first post-operative day. Histopathological examination of the specimen showed features that are in keeping with mature teratoma (Figure 2, Figure 3). At one-year follow-up he had no evidence of local recurrence.

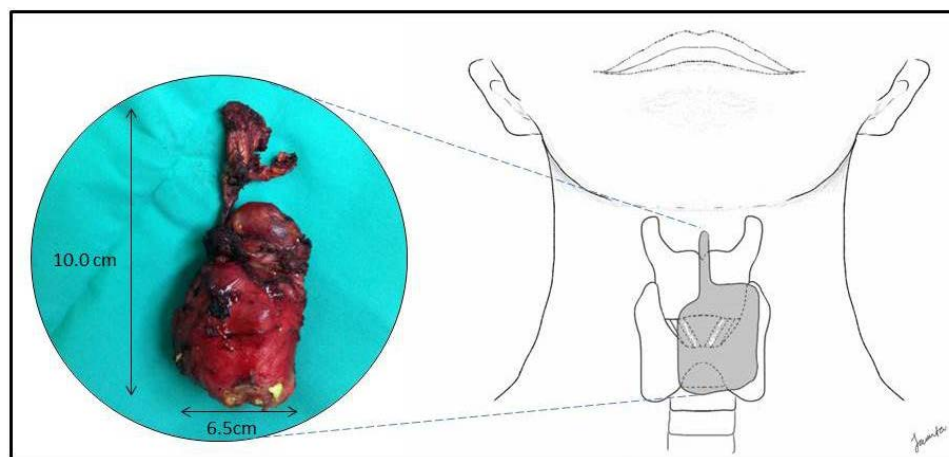


Figure 1. Dissected out cervical teratoma with its superiorly located tract extending to the center of the hyoid bone

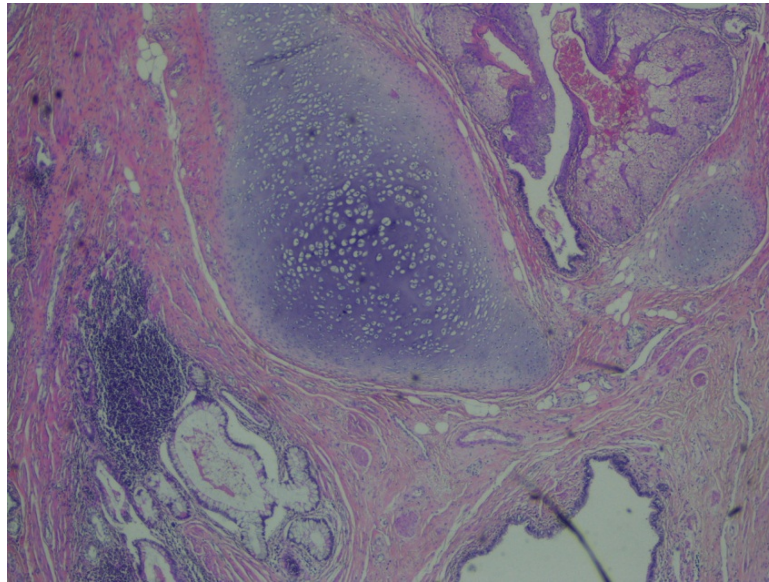


Figure 2. Section shows that the tumour is composed of mature elements of mesenchymal and ectodermal origin: hair follicle, sebaceous gland, mature cartilage, mature intestinal epithelium, mature lymphoid tissue and respiratory type epithelium.

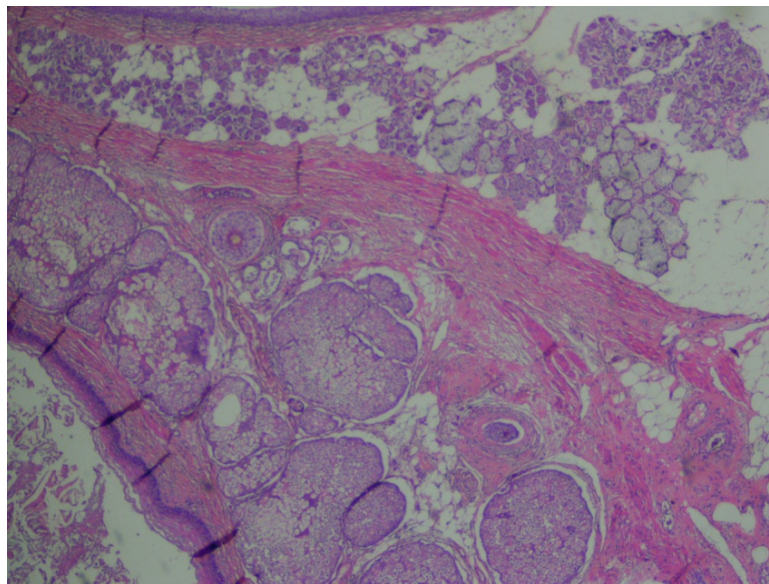


Figure 3. Section shows that a cyst is lined by skin epithelium and its appendages including hair follicles and sebaceous glands along with mature adipose tissue

3. Discussion

Teratomas are germ cell tumors arising from the abnormal development of pluripotent stem cells. Etymologically, the word teratoma is derived from Greek *teras* which literally means monster, was coined by Virchow. Teratomas have been reported to occur in various sites and organs: ovaries, testes, sacrococcygeal region, head and neck, anterior mediastinum, retroperitoneum, body wall, brain, spinal cord, and liver [1]. The term cervical teratoma incorporates lesions arising in the anterior and posterior triangles of the neck [2]. It comprises only about 3% of all teratomas [3] with the majority occurring in neonates or infants. The reported incidence of cervical teratoma in newborn, children aged 1 month to 18 years and adults were 75.1%, 14.3% and 10.6% respectively [3]. The clinicopathologic behaviour of the cervical teratoma in adults is distinctly different from those of the neonate and infant. In contrast to cervical teratomas in newborns, those in adults are often highly malignant with a tendency

to metastasize and have poor prognosis [2,3,4,5]. A Medline search was made on all publications involving cervical teratomas occurring in adults yielded less than 50 such case reports. However, if we exclude those occurring in thyroid, base of skull and along the cervical spine, there were only 10 cases reported (Table 1) [2,5-13].

The aetiology of the cervical neck teratomas remains unknown. Classifications have been made in the past in an attempt to define these tumours in relationship to the thyroid gland. It is still debated whether teratomas of the thyroid gland and teratoma of a neck origin are distinctively different entities [14,15,16]. However, there is no clinical significance as these tumours have no difference in terms of prognosis or treatment [2,3]. With regards to pathogenesis for teratomas of the neck, it is postulated that the embryonic tissues in proximity to the primitive streak and notochord somehow lose its governing influence over the totipotent cells, possibly due to alteration in the sterol chemistry in the embryonic primitive streak, notochord, or adjacent structures [5,17].

Table 1. Summary of case reports on cervical neck teratoma in adult (locations at thyroid, skull base and along cervical spine omitted)

Author	Age of patient (yrs)	Sex	Histology
Marescot 1945 ¹	36	Female	Benign teratoma
Woods 1978 ²	40	Female	Benign teratoma
Colton 1978 ³	77	Male	Malignant teratoma
Tobey 1980 ⁴	51	Male	Malignant teratoma
Mochizuki 1986 ⁵	26	Female	Benign teratoma
Sawafuji 1993 ⁶	21	Male	Benign teratoma
Abe 1997 ⁷	21	Female	Benign teratoma
Als 1998 ⁸	33	Male	Malignant teratoma
Lukman 2005 ⁹	22	Male	Malignant teratoma
Omranipour 2007 ¹⁰	20	Male	Cervical mature teratoma, late relapse after left orchidectomy for testicular teratocarcinoma 17 years ago and
Our patient	18	Male	Benign teratoma

The diagnosis of teratoma is based on histopathologic examination. Ultrasound neck is the first line modality for evaluating cervical neck abnormalities, especially for assessment of concomitant thyroid pathology. However, it did not identify the tumour as in our case as the echogenic profile mimicked the thyroid gland which was compressed. Computed tomography (CT) of the neck would have been more accurate but we were misled to believe we were dealing with a simple thyroglossal cyst. CT appearance will depend on the type of teratomas, with a variable attenuation, consistent of different tissues: fat-fluid levels with areas of calcification [18]. Mature teratomas are usually cystic in comparison to immature teratomas which are usually solid [18].

Teratomas have diverse histopathologic differentiations due to a wide range of cellular differentiation and variable degrees of maturation [2,19]. However, histologic immaturity should not be equated to malignancy [19]. In general, they can be categorized into three types: mature teratomas, immature teratomas and teratomas with malignant transformation [20]. Mature teratomas, are composed of fully differentiated tissue elements of all 3 germ layers although the presence of only 2 germinal components does not exclude this diagnosis [18]. Derivatives of 1 or 2 germ layers may overgrow others.

Immature teratomas and mature teratomas contain the same elements as the primitive tissues found in fetus but differ in the degree of differentiation of the tissue elements. Teratomas with malignant transformation occur in 30% of cases and are usually adenocarcinomas occurring in mature teratomas; or angiosarcomas or rhabdomyosarcomas occurring in immature teratomas [21].

Teratomas have an unpredictable biologic potential and often undergo malignant transformation during adulthood [9]. Therefore, complete surgical excision is recommended for cervical teratomas found in adults. If histopathological examination shows the tumour to be a malignant cervical teratoma, then complete resection is followed by adjuvant chemotherapy.

Anatomically, the cervical teratomas lie in the visceral space between the anterior strap muscles of the neck (sternohyoid and sternothyroid) and the pretrachea fascia that split to enclose the thyroid gland. Its upward extension is therefore limited by attachments of anterior strap muscles to the hyoid bone at the midline. However, its downward extension into the anterior mediastinum is unhindered and often occurs as in our patient. We did not require a median sternotomy as the inferior edge was just at the level of the thoracic inlet and we were able to retract it superiorly.

The long dormant period from inception to diagnosis for cervical teratomas in adults is uncommon. Generally in males, anterior neck swellings are only noticed once they have achieved a significant size as the well-developed muscles in males mask smaller swellings. The tumour itself is slow-growing by nature and has been undetected all this while. Clinical examination grossly underestimated the size of the lesion and most of the tumour was located retrosternally pushed down by the muscles.

Our patient was unique clinically and ultrasonographically that the tumour strongly mimicked a thyroglossal cyst and intra-operatively there was a midline tubular structure that extended inferiorly from the hyoid bone. This raises the possibility that the tumour in our patient might possibly a thyroglossal teratoma derived from the pluripotent cells of the remnant foramen caecum. Furthermore, the tumour was also densely adherent to the pretracheal fascia, and was difficult to be separated from the thyroid gland following the tract path of a remnant thyroglossal tract.

In conclusion, cervical neck teratoma of adult is rare. The diagnosis is based on histopathologic examination. Preoperative investigation with CT neck requires high index of suspicion. Due to concerns of malignant transformation during adulthood, complete surgical resection is recommended. Adjuvant chemotherapy is indicated when malignancy is confirmed histologically.

Acknowledgement

We would like to thank the Director General of Health, Malaysia for permission to publish this paper.

References

- [1] Tapper D, Lack E. Teratomas in infancy and childhood. *Arch Surg*. 1983; 198: 398-410.
- [2] Als C, Laeng H, Cerny T, et al. Primary cervical malignant teratoma with a rib metastasis in an adult: Five-year survival after surgery and chemotherapy. *Ann. Oncol.* 1998; 9: 1015-1022.
- [3] Jordan RB, Gauderer MWL. Cervical teratomas: an analysis, literature review and proposed classification. *J Pediatr Surg*. 1988; 23(6): 583-591.
- [4] Kimler SC, Muth WF. Primary malignant teratoma of the thyroid, case report and literature review of cervical teratoma in adults. *Cancer* 1998; 42: 311-7.
- [5] Colton JJ, Batsakis JG, Work WP. Teratomas of the neck in adults. *Arch Otolaryngol.* 1978; 104: 271-272.
- [6] Marescot IE. Tumoresteratoidesdelcuello. *Rev Espan Cir.* 1945; 2: 382-383.
- [7] Woods RD, Pearson BW, Weiland LH. Benign cervical cystic teratoma. *ORL.* 1978; 86: 468-72.

- [8] Tobey DN, Mangham C. Malignant Cervical Teratomas. *Otolaryngol Head Neck Surg.* 1980; 88: 215-7.
- [9] Mochizuki Y, Noguchi S, Yokoyama S, et al. Cervical teratoma in a fetus and an adult. Two case reports and review of literature. *ActaPatholJpn.* 1986; 36: 935-43.
- [10] Sawafuji M, Kakizaki T, Yamamoto T, et al. A case of cervical teratoma in adult. *Nihon KyobuGekaGakkaiZasshi.* 1993; 41: 2220-3.
- [11] Abe H, Sako H, Tamura Y, et al. Benign cervical teratoma in an adult: Report of a case. *Surg Today.* 1997; 27: 469-472.
- [12] Lukman MR, Jasmi AY, Sarinah B, et al. Malignant cervical teratoma in an adult presenting with impending airway obstruction. *Asian J Surg.* 2005; 28: 227-9.
- [13] Omranipour R, Alavion M. Cervical mature teratoma 17 years after initial treatment of testicular teratocarcinoma: report of a late relapse. *World J Surg Oncol.* 2007; 5:1.
- [14] Saphir O. Teratoma of the neck. *Am. J. Path.* 1929; 5: 313-321.
- [15] Bale GF. Teratoma of the neck in the region of the thyroid gland: a review of the literature and report of four cases. *Am. J. Path.* 1950; 26: 565.
- [16] Silberman R, Mendelson IR. Teratoma of the neck. Report of two cases and review of the literature. *Arch Dis Child.* 1960; 35: 159-170.
- [17] Rundle FW. Cervical teratoma. *J Otolaryngol.* 1976; 5:513-518.
- [18] Choi SJ, Lee JS, Song KS et-al. Mediastinal teratoma: CT differentiation of ruptured and unruptured tumors. *AJR Am J Roentgenol.* 1998; 171: 591-4.
- [19] Rothschild MA, Catalano P, Urken M, et al. Evaluation and management of congenital cervical teratoma. Case report and review. *Arch Otolaryngol Head Neck Surg.* 1994; 120:444-448.
- [20] Chen C, Zheng H, Jiang S. An unusual case of giant mediastinal teratoma with malignant transformation. *Ann. Thorac. Surg.* 2008; 86 (1): 302-4.
- [21] William Herring. Recognizing Diseases of the Chest. In: William Herring. *Learning Radiology: Recognizing The Basics*, 2nd edn. Philadelphia: Elsevier Mosby, 2012; 109-113.