

# Study of Thoracic Vertebral Synostosis in North India

Preeti Goswami, Yogesh Yadav\*

Department of Anatomy, Rama Medical College, Hapur, UP

\*Corresponding author: [dryogeshyadav@gmail.com](mailto:dryogeshyadav@gmail.com)

Received July 15, 2014; Revised August 18, 2014; Accepted September 02, 2014

**Abstract** The fusion of vertebral column is a rare anomaly usually congenital in origin. Fusion of the vertebra can be congenital or acquired. Embryologically, failure of resegmentation of the vertebra is the cause. The differentiation and resegmentation of vertebrae occur at the time of organogenesis. Thus resegmentation is the hallmark of vertebral development. Inappropriate vertebral fusion results in block vertebrae or spinal fusion or vertebral synostosis. Fusion of vertebrae can be acquired in case of trauma, tuberculosis and juvenile arthritis. It can occur at various levels viz., cervical, lumbar and thoracic vertebral levels in order of frequency. Among the 350 dry specimens of all vertebrae collected in the Department of Anatomy, two anomalous sets of fused thoracic vertebrae were found. Knowledge about any deviation from the normal anatomy of our vertebral column is very essential especially for orthopedician, forensic pathologist, neurologist and clinical anatomist for diagnosing the patients with such vertebral anomalies. Any congenital or acquired abnormality in the vertebrae may be asymptomatic or a cause of discomfort and inability to carry out various day to day activities because of the important structure related to them.

**Keywords:** fused vertebrae, thoracic synostosis

**Cite This Article:** Preeti Goswami, and Yogesh Yadav, "Study of Thoracic Vertebral Synostosis in North India." *American Journal of Medical Case Reports*, vol. 2, no. 9 (2014): 170-172. doi: 10.12691/ajmcr-2-9-2.

## 1. Introduction

The fusion of two or more vertebrae is a congenital anomaly of vertebral column. Such fusions may occur in the cervical, thoracic or lumbar region [1]. The fusion of thoracic vertebrae can present clinical signs like congenital scoliosis early in life and shortening of the trunk with scoliosis and/or lordosis in older children [2].

The vertebral column is derived from the sclerotomes of somites [3]. It is composed of vertebrae and intervertebral discs between them [4]. It is one among the chief manifestations of body segmentation or metamerism. The fusion of two or more vertebrae may occur in the cervical region (Klippel-Feil syndrome), atlas to occipital bone (occipitalization of atlas), fifth lumbar vertebra to the sacrum (sacralization of fifth lumbar vertebra) or in the thoracic region [5]. The fusion of thoracic vertebrae is the rarest among the three types- cervical, lumbar and thoracic. The fusion of two vertebrae can be congenital or acquired. The surgical fusion of two vertebrae is known as spondylodesis or spondylosyndesis. Acquired fusion can be due to diseases like tuberculosis, juvenile rheumatoid arthritis and trauma [6]. The prevalence of vertebral synostosis in Lithuanian population is 2.6% of cervical vertebra fusion, 1.6% of thoracic vertebral fusion and 0.5% of lumbar vertebral fusion [7].

## 2. Methods

A study on 350 dry specimens of vertebrae was done on the different features of specimens. They were also

checked for variations from normal anatomy. The embryological and clinical significance due to variations are discussed.

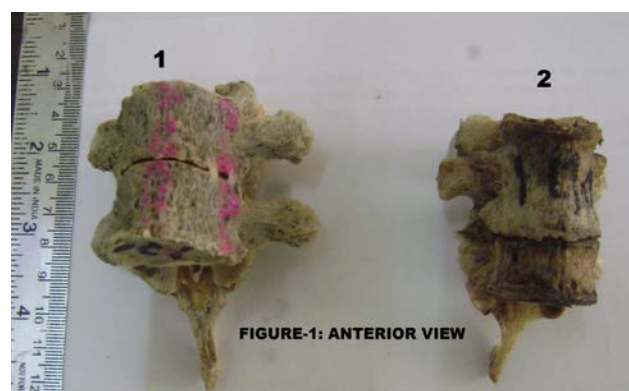


FIGURE-1: ANTERIOR VIEW

Figure 1.

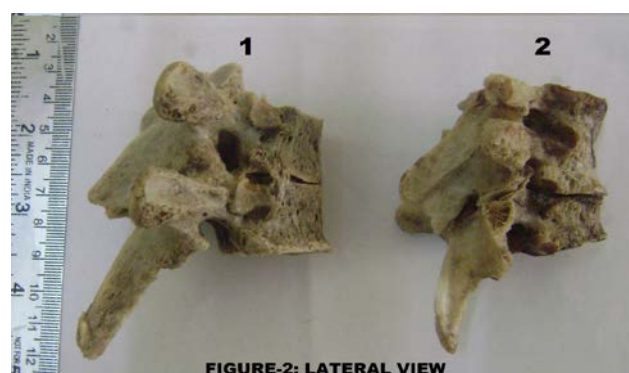

FIGURE-2: LATERAL VIEW

Figure 2.

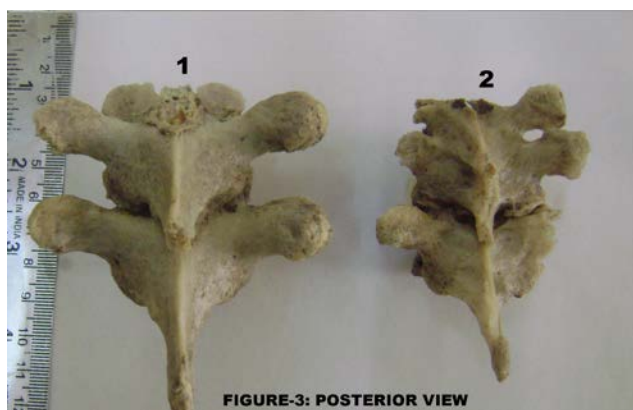


Figure 3.

### 3. Observations

In the present study, we found two sets of fused thoracic vertebrae among 350 dry specimens of all assorted vertebrae of unknown sex (Figure 1). In first set two thoracic vertebrae and in second set three thoracic vertebrae were fused. Features of the first and second specimen were discussed in Table 1 and Table 2 respectively. In first specimen the junction of fusion of both laminae and spinous process (Figure 2), there is a groove with linear crest on both sides, which demarcates the fusion. The costal facets are seen on either side of the body near its junction. In second specimen at the junction of fusion of both laminae and spinous process, there is a groove with linear crest on both sides, which demarcates the fusion is present between 2<sup>nd</sup> & 3<sup>rd</sup> vertebrae. The costal facets are seen on either side of the body near its junction. There is no clear demarcation between the body, lamina & spinous process of 1<sup>st</sup> & 2<sup>nd</sup> vertebrae (Figure 3). Costal facets on either side of body and vertebral foraminae are seen.

Table 1. Various dimensions of 1 set of fused vertebrae

Parts of Vertebra	View	Upper Vertebra	Lower Vertebra
Body	AP	2.0 cm.	2.3 cm.
	Transverse	2.7 cm.	2.9 cm.
Spinal Canal	AP	1.3 cm.	1.6 cm.
	Transverse	1.7 cm.	1.8 cm.
Vertebral Foramen	Right	1.0 cm.	
	Left	0.8 cm.	
Fused Lamina	4.2 cm.		

Table 2. Various dimensions of 2 set of fused vertebrae

Parts of Vertebra	View	Upper Vertebra	Lower Vertebra
Body	AP	1.4 cm.	2.3 cm.
	Transverse	2.1 cm.	2.9 cm.
Spinal Canal	AP	1.2 cm.	1.6 cm.
	Transverse	1.4 cm.	1.8 cm.
Vertebral Foramen	Right	0.7 cm.	0.8 cm.
	Left	0.7 cm.	0.9 cm.
Fused Lamina	5.0 cm.		

### 4. Discussion

The vertebral column develops from paired somites, each composed of a dermatome, myotome and sclerotome. They arise initially in the cervical region (4th week), increasing in number cranio-caudally. In the 5th week, the sclerotomic cells of the somites lose their adherence and migrate to the vertebral centrum, neural processes and costal processes. Each thoracic neural process gives rise to a cartilaginous pedicle, transverse process, and lamina. The ossification centres arise, one for the centrum and one each for the neural processes. Their timing is idiosyncratic, starting in the 4th month at T10 and L1 (centra) and C2 and T1 (neural processes) and spreading up and down the column [8]. The segmentation of the vertebra occurs at the time of organogenesis. The non-segmentation of the primitive sclerotome is the cause for fused vertebra or block vertebra. The embryological time period for the occurrence of synostosis can be analyzed from the anatomical features. In this case, the pedicles and transverse process are not fused indicates that the initial development was normal [9]. Radiologically, three types of vertebral fusion have been described: Single fused cervical segment seen in 25% of patients, multiple, contiguous fused segments seen in 25% patients and multiple, non-contiguous fused seen in 50% patients [10].

Anatomically, the intervertebral discs form a fifth of the post axial vertebral column [11]. The absence of intervertebral disc therefore leads to shortening of the column and thereby shortening of the trunk. The thoracic vertebrae and the intervening disc along with the ribs help to maintain the shape and length of the thorax. Fusion of the vertebrae and the absence of the disc will narrow the thorax and can lead to respiratory distress. Asphyxiating thoracic dystrophy is caused by narrow thorax and short ribs [12]. Apart from the developmental anomalies the vertebral fusion can be associated with radiculopathy and myelopathy. The other associated complications mentioned are [13]:

1. Musculoskeletal-club feet, Sprengel’s deformity, Klippel-Feil syndrome, dysplasia of hip, scoliosis
  2. Renal-unilateral horse-shoe kidney, duplicated kidney or ureters, hypospadias
  3. Congenital heart disease
  4. Neural axis-diastematomyelia, tethered cord, Arnold-Chiari malformation
  5. Jaw and external deformities, cleft palate, cervical rib.
- Such fusion may also lead to wrong calculation of vertebrae clinically as well as radiologically.

### 5. Conclusion

Fusion of the vertebra can be congenital or acquired. Embryologically, failure of resegmentation of the vertebra is the cause. This can lead to wide complications affecting different systems of body. Knowledge about any deviation from the normal anatomy of our vertebral column is very essential especially for orthopedician, forensic pathologist, neurologist and clinical anatomist for diagnosing the patients with such vertebral anomalies as well as misinterpretation of number of vertebrae radiologically and clinically.

## References

- [1] Seaver LH, Boyd E. Spondylarcarpotarsal synostosis syndrome and cervical instability. *PubMed Am J Med Genet* 2000; 91(5): 340-4.
- [2] Al Kaissi A, Ghachem MB, Nassib N, Ben Chechida F, Kozlowski K. Spondylarcarpotarsal synostosis syndrome (with a posterior midline unsegmented bar). *Pub Med Skeletal Radiol* 2005; 34(6): 364-6.
- [3] Inderbir Singh, Pal GP. *Human Embryology*. 8th ed. India: Mac Millan Publishers Limited; 2007. p. 116.
- [4] Datta AK. *Essentials of Human Embryology*. 6th ed. Kolkata: Current Books International; 2010. p. 278.
- [5] Inderbir Singh, Pal G P. *Human Embryology*. 8th ed. India: Mac Millan Publishers Limited; 2007. p. 119.
- [6] Erdil H, Yildiz N, Cimen M. Congenital fusion of cervical vertebrae and its clinical significance. *Journal of Anatomical Society of India* 2003; 52(2): 125-7.
- [7] Masnicova S, Benus R. Developmental anomalies in skeletal remains from the Great Moravia and Middle Ages cemeteries at Devin. *International journal of osteoarchaeology* 2003; 13:266-74.
- [8] Murray Brookes, Anthony Zietman. *Clinical Embryology*. USA: Library of Congress; 1998. p. 293.
- [9] Kulkarni Vasudha, Ramesh BR. A spectrum of Vertebral Synostosis. *International Journal of Basic and Applied Medical Sciences* 2012; 2(2): 71-7.
- [10] Jin-Kyu Park, Han – Young Huh, Kyeong-Sik Ryu and Chun-Kun Park. Traumatic Hemiparesis associated with Type III KlippelFeil syndrome. *Journal of Korean Neurosurgical Society* 2007; 42: 145-8.
- [11] Henry Grey, Editor. *Grey's Anatomy*, 38th ed, Churchill Livingstone 1995, p. 513.
- [12] Satish Bhargava. *Radiological Differential Diagnosis*. 1<sup>st</sup> ed. New Delhi: Jaypee Brothers; 2005. p. 528.
- [13] Batra Sameer, Ahuja Sashin. Congenital Scoliosis: Management and future directions. *Actaorthopedica Belgica* 2008; 74: 147-60.