

Case Report: L-2-Hydroxyglutaric Aciduria in Sibling Sisters

Rasim Bakhtiyar Bayramov¹, Mehriban Musa Sariyeva^{2,*}, Narmin Eldar Maharramli²

¹Chief of Diagnostic Radiology Department, Educational – Surgical Clinic of Azerbaijan Medical University

²Diagnostic Radiology Department, Educational – Surgical Clinic of Azerbaijan Medical University

*Corresponding author: dr.sariyeva@gmail.com

Received March 04, 2022; Revised April 06, 2022; Accepted April 12, 2022

Abstract Our case report presents one of the rarely seen disorders L-2-hydroxyglutaric aciduria. Very little information is given in the literature and it remained undiagnosed until the 1980s. According to our information, only 295 events have been described in the literature till date. Our case report describes the disease manifestations, clinical pictures, and a review of the relevant literature on L-2-hydroxyglutaric aciduria. Our patients were females aged 12 and 13 years, respectively, which were born in consanguineous and Caucasian descent family.

Keywords: L-2-hydroxyglutaric aciduria, mental retardation, speech difficulties, generalized seizure, febrile seizures, diffuse subcortical white matter lesions

Cite This Article: Rasim Bakhtiyar Bayramov, Mehriban Musa Sariyeva, and Narmin Eldar Maharramli, “Case Report: L-2-Hydroxyglutaric Aciduria in Sibling Sisters.” *American Journal of Medical Case Reports*, vol. 10, no. 4 (2022): 93-97. doi: 10.12691/ajmcr-10-4-3.

1. Introduction

L-2-hydroxyglutaric aciduria belongs to the group of organic acidurias. L-2-hydroxyglutaric aciduria is an inherited, autosomal recessive disease and has a slow-progressing disease pattern. Prominent clinical features in our patients were febrile seizures, generalized seizures, mental retardation, and speech difficulties. We confirmed the diagnosis by characteristic brain magnetic resonance imaging (MRI) findings and laboratory tests.

2. Case Report

A 13-year-old girl presented to the emergency department with a generalized seizure. After pediatric and neurological evaluation, the patient showed mental retardation, cognitive impairment, speech difficulties, and ataxia. Magnetic resonance imaging (MRI) and computed tomography (CT) findings showed diffuse lesions in subcortical white matter with spared deep white matter, basal ganglia, and brainstem (Figure 1, Figure 2, Figure 3). Cerebellar vermis and dentate nuclei involvement was seen (Figure 2a). After contrast administration, no significant change was detected in MR sequences.

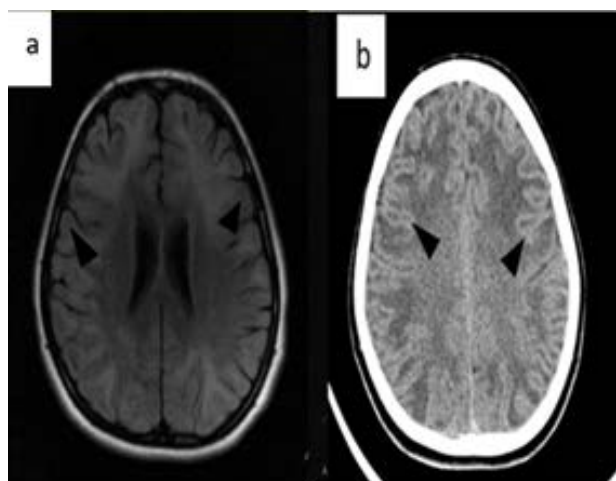


Figure 1. 13 years old girl's brain axial FLAIR MR and axial CT imagings mention cerebral subcortical white matter lesions in bilateral frontal and parietal lobes: a) diffuse hyperintense areas (black arrowhead); b) diffuse hyperdense areas (black arrowhead)

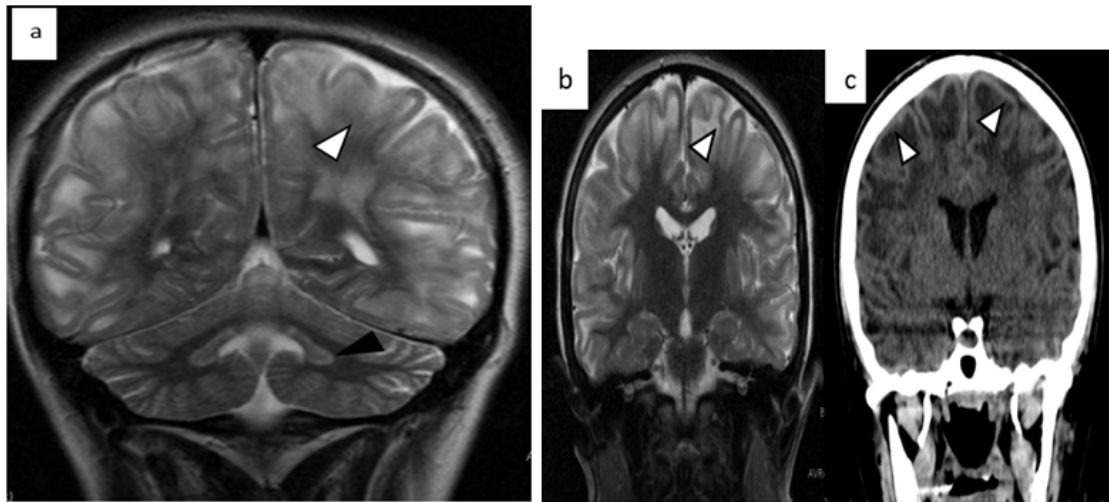


Figure 2. 13 years old girl's brain Coronal T2 MR and CT image: a) Coronal T2 MR of the brain shows in the posterior fossa, a high signal due to involvement of the bilateral dentate nucleus (black arrowhead), bilateral and symmetrical high signal in the subcortical U-fibers of temporal and parietal lobes (white arrowhead). b) Coronal T2 MR - preserved the periventricular region's deep matter and brainstem. Bilateral and symmetrical high signal in the subcortical U-fibers of temporal and parietal lobes (white arrowhead). c) Coronal CT of the same brain shows hyperdense bilateral and symmetrical subcortical white matter lesions of temporal and parietal lobes (white arrowhead)

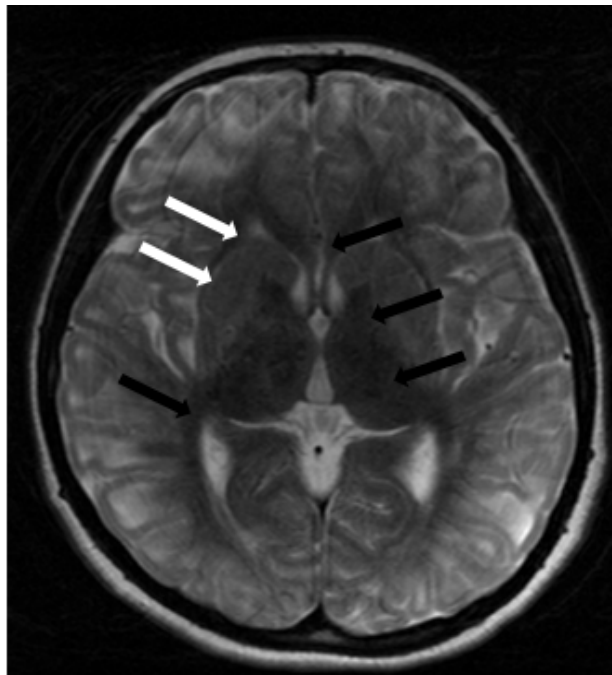


Figure 3. 13years old girl MR Axial T2 imaging: High signal in the putamen and bilateral presence of caudate head (white arrows). The corpus callosum, bilateral thalamus, inner capsule, and deep white matter are not affected (black arrows)

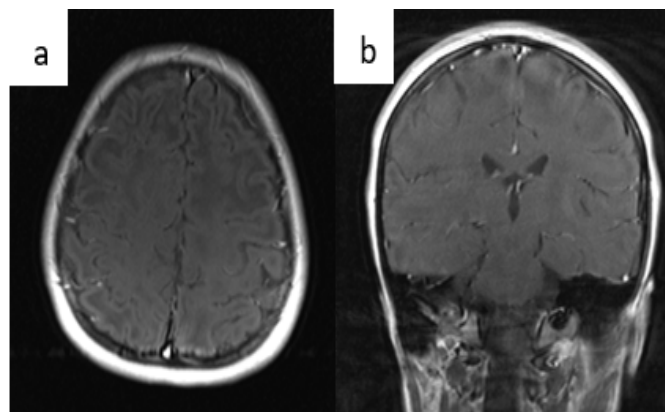


Figure 4. 13years old girl Axial (a) and Coronal (b) MR imaging after contrast administration: Axial (a) and Coronal (b) T1 Fat-Sat + C MR enhancement was not observed in subcortical white matter lesions

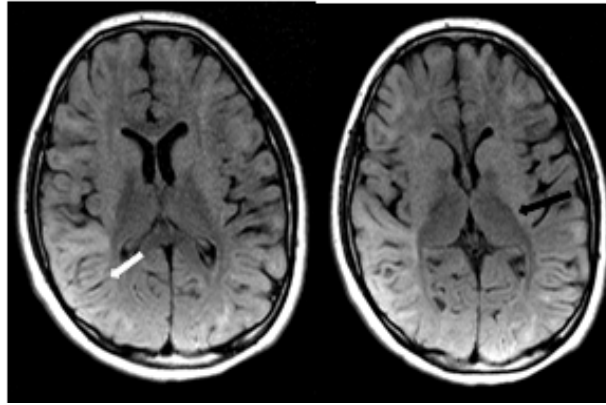


Figure 5. 12years old girl (younger sibling) brain Axial FLAIR MR image: Hyperintense diffuse brain subcortical white matter lesions (white arrow). The deep white matter of the bilateral thalamus and periventricular region is preserved (black arrow)

The first episode manifested as a febrile seizure at 7 days of age, resolving with antipyretics. Delayed milestones were observed from 2 years of age. The first pronounced cognitive impairment was onset at 9 years of age after an upper respiratory viral infection when the patient came to the emergency department with a febrile seizure. Further investigations revealed that her sibling, a 12 years old girl had prominent mental retardation and generalized seizures episodes. Specific MRI findings confirmed the diagnosis (Figure 5) and increased L-2-hydroxyglutaric acid (L-2-HGA) levels in urine and blood. Parents and their 5 years old son were disease-free. Additional family history includes Caucasian descent, consanguineous marriage, uneventful pregnancy, and normal root of delivery for all the children.

3. Discussion

Initially, L-2-HGA was described and characterized by Duran, Barth, and their colleagues as a rare autosomal recessive organic aciduria affecting only the central nervous system, manifesting itself with specific MRI changes [1,2].

Despite the first report on L-2-HGA in 1980, a total of 295 cases have been reported worldwide in the literature [3,4].

L and D isoforms of 2-HGA can be found in the urine in equal amounts in healthy individuals. An increase of any isoform (L-D) configurations is a sign of potential disease. Progression of disease in L-2-HGA is slow, however, D-2-HGA among neonates may present prominently and with severe manifestations [5,6,7].

The pathogenesis of L2HGA is uncertain, and the accumulation of L-2-Hydroxyglutarate (L-2-HG) damages white matter [8,9]. MR spectroscopy shows a decrease in the neuronal N-acetyl aspartate (NAA) and choline and increases the Myo-inositol peaks [10]. The myo-inositol peaks, which is a precursor of phosphatidylinositol, suggest inhibition of phosphatidylinositol synthesis, whereas the reduction of choline may reflect a progressive stage of neurodegeneration [10].

A definitive diagnosis depends on characteristic MRI findings, which include scattered or diffuse subcortical white-matter abnormalities that fade centripetally and detection of increased L-2 HGA levels in the urine, blood, and cerebrospinal fluid [5,11-15].

Differential diagnosis with other similar diseases also plays an important role in making a diagnosis. MRI manifestations of Canavan diseases have also similar findings as noted in L-2-HGA. In L-2-HGA white matter the cortical region is more involved than the periventricular. This is one of the main differences between L-2-HGA from other leukodystrophies. In addition to subcortical cerebral white matter abnormalities, L-2-HGA and Canavan disease mainly cause symmetrical hyperintensity in the dentate nuclei. However, Canavan disease affects the brainstem, whereas L-2-HGA does not [12].

In L-2-HGA, the symptoms like mental retardation, cognitive impairment, ataxia, and macrocephaly are presented at a young age. At older ages, walking disorder which manifests as ataxia and decreased IQ levels are more prominent signs [5,16]. Some studies mention that before 10 years of age IQ levels of patients were between 50 and 75 [17]. Patients who have a late onset of disease compared to patients whose disease manifestations occur earlier have milder clinical manifestations [16].

In our case, the older sibling presented cognitive symptoms at age 9, and the younger sibling developed cognitive regression earlier (4 years). However, no macrocephaly was observed in both sisters.

Some studies in the literature suggest that epileptic seizures or even status epilepticus may occur in the early stages of L-2-HGA. This is probably due to early subcortical white matter changes with the subsequent development of epilepsy. Febrile seizures partial and major seizures have been reported and are generally difficult to control [5,11-13].

In our cases, the first alarming sign was a febrile seizure that occurred before the generalized seizure. Although febrile seizures are not considered a risk factor for grand mal, we consider that as lesion areas enlarge, the magnitude of seizure expands.

Previously Mediterranean origin of the disorder was mentioned in the literature, additional surveys conducted all in Turkey, that included haplotype and mutation analyses of families, revealed nine different mutations which excluded a founder effect [13,17].

Regarding the study that we came across in the library, 18 families were selected for evaluation. They were from rural areas of Turkey in Central and South-East Anatolia. Consanguinity was known in 17 families. A total of 89

individuals including 28 affected subjects (15 males and 13 females) were analyzed. The mean age at the time of diagnosis was 13.4 years (2.5–32 years) [17].

One of the retrospective study studies evaluated MRI findings of L-2 HGA among 17 patients, and also described sibling patients. The author relates the severity of clinical symptoms with the severity of MRI findings, but atrophy of white matter is related to the duration of the disease [18]. In another study along with 8 patients which also included siblings despite both patients' speech difficulties being onset at an early age, walking difficulties and ataxia started later years of age. And the same study mentions that these patients can walk without support before they lost of walking ability [19].

An Our patients were same age range when the disease is diagnosed. Clinical symptoms were similar, except for prominent mental retardation in 13 years old patients started at 9 years of age but in younger 12 years old patients at 5 years of age with prominent speech difficulties, and cognitive impairment. Also, ataxia and walking difficulties were only noticed after neurologic evaluation which was unrecognized by parents. Regarding family history, a recent paper about Pakistani siblings with l-2-hydroxyglutaric which also was born from consanguineous parents, with a similar clinical picture as our patients, mentions mental regression and seizures in both patients of patients [20]. But in our case, after neurologic evaluation of mental deterioration, cognitive impairment, and speech difficulty was seen in neither parent.

Reaching more patients reaches adulthood, studies mention an increased incidence of brain tumors in the late years of age were observed [21,22,23]. This feature of L-2-hydroxyglutaric aciduria also makes it important to diagnose and evaluate.

4. Conclusion

Our cases were a few among the rare autosomal-recessive and inherited neurometabolic disorders. A high index of suspicion should be noted from childhood as evidenced by delayed milestones, psychomotor retardation, speech difficulties, spasticity, and seizures.

Our observations and previous studies in the literature frequently mentioned Caucasian, and Mediterranean populations being increasingly affected by the disease. Also, consanguineous families carry a high risk of developing L-2-HGA.

Also increased incidence of brain tumors in this population requires frequent follow-up of patients.

Conflict of Interest

The authors state that there is no conflict of interest.

Acknowledgments

The consent form was filled out by the parents of participants.

Abbreviations

CT- Computed Tomography
MRI- Magnetic Resonance Imaging
NAA - Neuronal N-acetyl aspartate
L-2-HGA - L-2-hydroxyglutaric aciduria

References

- [1] Barth P.G., Hoffmann G.F., Jaeken J., et al. L-2-hydroxyglutaric acidemia: a novel inherited neurometabolic disease. *Ann Neurol* 1992; 32: 66-71.
- [2] Duran M., Kamerling J.P., Bakker H.D., van Gennip A.H., Wadman S.K. L-2-hydroxyglutaric aciduria: an inborn error of metabolism? *J Inher Metab. Dis.* 1980; 3: 109-112.
- [3] George J., Sandhya P., Sajitha K.V., et al. Attention deficit hyperactivity disorder: a rare clinical presentation of L-2-hydroxyglutaric aciduria. *BMJ Case Reports CP* 2021; 14: e244038.
- [4] Chaudhari D.M., Renjen P.N., Goyal N., et al. Central variant reversible encephalopathy syndrome *BMJ Case Reports C.P* 2022; 15: e245636.
- [5] Topçu M., Aydın O.F., Yalçinkaya C., et al. L-2-hydroxyglutaric aciduria: a report of 29 patients. *Turk J. Pediatr* 2005; 47: 1-7.
- [6] Moroni I., D'Incerti L., Farina L., et al. Clinical, biochemical and neuroradiological findings in L-2-hydroxyglutaric aciduria. *Neurol Sci* 2000; 21: 103-8.
- [7] Haliloglu G., Jobard F., Oguz K.K., et al. L-2-hydroxyglutaric aciduria and brain tumors in children with mutations in the L2HGDH gene: neuroimaging findings. *Neuropediatrics* 2008; 39: 119-22.
- [8] Latini A., Scussiato K., Borba Rosa R., et al. Induction of oxidative stress by L-2-hydroxyglutaric acid in rat brain. *J. Neurosci Res.* 2003; 74: 103-110.
- [9] Ullah M.I., Nasir A., Ahmad A., et al. Identification of novel L2HGDH mutation in a large consanguineous Pakistani family—a case report. *BMC Med. Genet.* 2018; 19: 25.
- [10] Hanefeld F., Kruse B., Bruhn H. and Frahm J. (1994). In vivo proton magnetic resonance spectroscopy of the brain in a patient with L-2-hydroxyglutaric acidemia. *Pediatr. Res.*, 35, 614-616.
- [11] Mete A., Isikay S., Sirikci A., et al. Eyelid myoclonia with absence seizures in a child with l-2 hydroxyglutaric aciduria: findings of magnetic resonance imaging. *Pediatr Neurol* 2012; 46: 195-7.
- [12] Topçu M., Erdem G., Saatçi I., et al. Clinical and magnetic resonance imaging features of L-2-hydroxyglutaric acidemia: report of three cases in comparison with Canavan disease. *J Child Neurol* 1996; 11: 373-7.
- [13] Zafeiriou D.I., Sewellb A., Savvopoulou-Augoustidoua P., Gombakisa N., Katzoset G. L-2-Hydroxyglutaric aciduria presenting as status epilepticus. *Brain Dev.* 2001; 23(4):255-7.
- [14] Moroni I., D'Incerti L., Farina L., et al. Clinical, biochemical and neuroradiological findings in L-2-hydroxyglutaric aciduria. *Neurol Sci* 2000; 21: 103-8.
- [15] Karatas H., Saygi S., Bastan B. L-2-hydroxyglutaric aciduria. Report of four Turkish adult patients. *Neurologist.* 2010; 16: 44-6.
- [16] Fujitake J., Ishikawa Y., Fujii H., et al. L-2-hydroxyglutaric aciduria: two Japanese adult cases in one family. *J.Neurol* 1999; 246: 378-382.
- [17] Meral Topçu., Florence Jobard., Sophie Halliez., Turgay Coskun, Cengiz Yalçinkaya, Filiz Ozbas Gerceker, Ronald J.A. Wanders, Jean-François Prud'homme, Mark Lathrop, Meral Özguc, Judith Fischer, L-2-Hydroxyglutaric aciduria: identification of a mutant gene C14orf160, localized on chromosome 14q22.1, *Human Molecular Genetics*, Volume 13, Issue 22, 15 November 2004, Pages 2803-2811.
- [18] Héla Fourati, Emna Ellouze, Mourad Ahmadi, Dhouha Chaari, Fatma Kamoun, Ines Hsairi, Chahnez Triki, Zeineb Mnif, MRI features in 17 patients with l2 hydroxyglutaric aciduria. *European Journal of Radiology Open*, Volume 3, 2016, Pages 245-250, ISSN 2352-0477.

- [19] Canda, Ebru & Kose, Melis & Yazıcı, Havva & Er, Esra & Eraslan, Cenk & Ucar, Sema & Habif, Sara & Karaca, Emin & Onay, Hüseyin & Ozkinay, Ferda & Coker, Mahmut. (2018). Clinical, Neuroimaging, And Genetic Features of Patients With L-2-Hydroxyglutaric Aciduria. *The Journal of Pediatric Research*. 5. 10.4274/jpr.59454.
- [20] László Sztriha, Aithala Gururaj, Peter Vreken, Michael Nork, Gilles G Lestringant, L-2-hydroxyglutaric aciduria in two siblings, *Pediatric Neurology*, Volume 27, Issue 2, 2002, Pages 141-144.
- [21] Aghili I, Zahedi F, Rafiee E. Hydroxyglutaric aciduria and malignant brain tumor: a case report and literature review. *J Neurooncol* 2009; 91: 233-6.
- [22] Haliloglu G, Jobard F, Oguz KK, et al. L-2-hydroxyglutaric aciduria and brain tumors in children with mutations in the L2HGDH gene: neuroimaging findings. *Neuropediatrics* 2008; 39: 119-22.
- [23] Moroni I, Bugiani M, D'Incerti L, et al. L-2-hydroxyglutaric aciduria and brain malignant tumors: a predisposing condition? *Neurology* 2004; 62: 1882-4.



© The Author(s) 2022. This article is an open access article distributed under the terms and conditions of the Creative Commons Attribution (CC BY) license (<http://creativecommons.org/licenses/by/4.0/>).