

Usefulness of Ultrasound for Differentiating between Decompression Sickness and Drowning in the Emergency Room

Kenji Kawai, Hiroki Nagasawa, Youichi Yanagawa*

Acute Critical Care Medicine, Juntendo Shizuoka Hospital, Izunokuni City, Shizuoka Prefecture, Japan

*Corresponding author: yyanaga@juntendo.ac.jp

Received October 11, 2021; Revised November 13, 2021; Accepted November 26, 2021

Abstract A 47-year-old woman, who had been diving 6 times, panicked during diving training and surfaced suddenly after a 15-minute dive at a depth of 19 meters. She had nausea, vomiting, and headache immediately after surfacing. Decompression sickness (DCS) was suspected, and she was transported to the emergency room (ER) of our hospital by ambulance. Upon arrival, she had mild consciousness disturbance and hypoxia requiring oxygen. Her symptoms remained. She initially received 12 L per minute of oxygen and rapid infusion for DCS. However, ultrasound study showed no air bubbles in the inferior vena cava or portal vein. Trunk computed tomography (CT) showed infiltrative lesions in the bilateral lung fields without gas in any vessels. The diagnosis was drowning with alternobaric vertigo. She was treated with an antibiotic without recompression therapy. The patient's dizziness and vomiting subsided quickly. Her post-admission course was uneventful and she was discharged to her home on the 9th hospital day. We report a case in which ultrasound was useful for differentiating between DCS and drowning. When patients have symptoms after diving, confirmation of the presence of gas in the heart or vessels using ultrasound in the acute phase is important for the diagnosis of DCS.

Keywords: *decompression sickness, ultrasound, alternobaric vertigo*

Cite This Article: Kenji Kawai, Hiroki Nagasawa, and Youichi Yanagawa, "Usefulness of Ultrasound for Differentiating between Decompression Sickness and Drowning in the Emergency Room." *American Journal of Medical Case Reports*, vol. 10, no. 1 (2022): 7-9. doi: 10.12691/ajmcr-10-1-3.

1. Introduction

Decompression sickness (DCS) is a condition in which excessive decompression causes a decrease in the solubility of gases (mainly nitrogen) in the blood and tissues, resulting in the formation of bubbles and the appearance of disorders. DCS is classified into two types: Type I and Type II. [1] Type I DCS is characterized by arthralgia and cutaneous symptoms due to lymphatic vessel damage. Type II is a potentially life-threatening condition in which organs, such as the central nervous system, respiratory organs, circulatory organs, and inner ear are damaged. DCS should always be suspected when a person who has been exposed to a decompressive environment, especially when a person has been diving for a long time at a depth of 10 meters or more, shows some symptoms after surfacing. Divers also often suffer from drowning. [2] Differentiation between drowning and DCS is important because the latter requires recompression therapy. [3,4] We report a case in which ultrasound was useful for differentiation between decompression illness and drowning in the emergency room.

2. Case Report

A 47-year-old woman, who had been diving 6 times, panicked during diving training and suddenly surfaced after a 15-minute dive at a depth of 19 meters. She had nausea, vomiting, and headache immediately after surfacing, and DCS was suspected. She was transported to the emergency room (ER) of our hospital by ambulance. She had no remarkable personal or family history. Upon arrival, her vital signs were as follows: Glasgow Coma Scale, E3V4M6; blood pressure, 131/71 mmHg; pulse rate, 94 beats per minute; respiratory rate, 26 breaths per minute; and percutaneous saturation, 94% under room air. She displayed restlessness, dizziness and nausea, and vomited frequently. On examination, there were no skin findings or joint pain; however, coarse crackles were heard in the bilateral lungs. As she had the history of sudden ascent during diving, she was treated for DCS. She received 12 L per minute of oxygen by reservoir mask to washout nitrogen gas and rapid infusion of fluids to correct dehydration. Electrocardiography revealed no specific findings. Ultrasound showed no air bubbles in the inferior vena cava or portal vein (Figure 1).

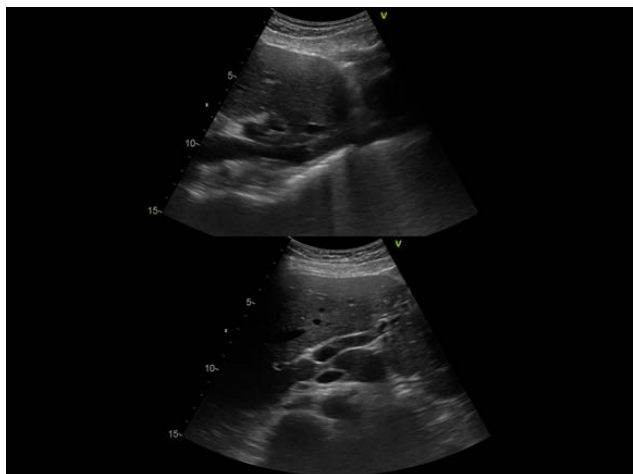


Figure 1. Abdominal ultrasound on arrival. No air bubbles were observed in the inferior vena cava or portal vein

Chest X-ray showed infiltrative lesions in the bilateral lung fields. Computed tomography (CT) also showed the same lesions without gas in any vessels (Figure 2).

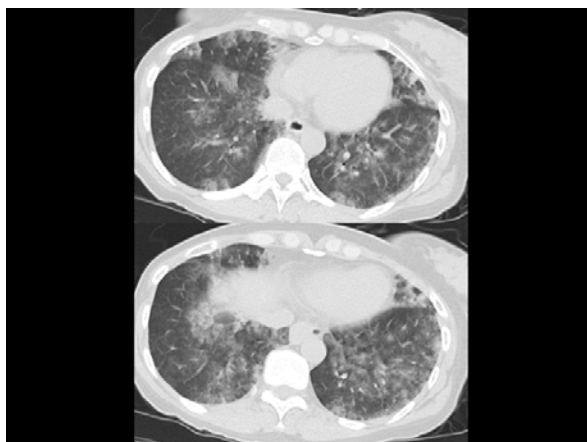

Figure 2. Chest computed tomography (CT) on arrival. CT showed diffuse infiltrative lesions in the bilateral lung fields. No gas was observed in the vessels or heart

The main results of a blood examination were leukocytosis (11500/ μ l) and normal level of fibrin degradation product. The diagnosis was drowning and inner ear disorder (Alternobaric Vertigo (AV)) due to pressure change; not DCS. She was infused with tazobactam/piperacillin for aspiration without recompression therapy. The patient's dizziness and vomiting subsided within 30 minutes in the ER. On the 2nd hospital day, her blood inflammatory response worsened. However, her oxygen demand gradually decreased and oxygen was no longer required on the 4th hospital day. The patient was discharged to her home on the 9th hospital day.

3. Discussion

In this case, DCS was initially suspected from the patient's history. However, ultrasonography showed no gas bubbles in the portal vein, inferior vena cava, or heart, and CT showed no intravascular gas. Accordingly, we concluded that the patient did not have DCS. Rather, she mainly had respiratory symptoms due to drowning and aspiration, in addition to AV. The fact that her symptoms

were relieved by the administration of oxygen and antibiotics without recompression therapy, was compatible with our hypothesis. In diving, more nitrogen gas dissolves into the body in comparison to under atmospheric pressure due to the pressurized environment. Therefore, it is known that bubbles can be detected in the veins by ultrasonography, which is highly sensitive for detecting gas, even if there are no symptoms after surfacing following decompression according to the decompression table. [5,6] Therefore, we considered that if the patient had symptoms associated with DCS in the acute phase after diving, gas would be detected by ultrasonography. Conversely, if gas is not detected soon after diving in a symptomatic patient, other diseases should be considered. [3,7] Further studies are needed to investigate how long gas can be detected by ultrasound in patients with DCS.

The differential diagnosis of dizziness after diving includes DCS, inner ear barotrauma, AV and other common inner ear disorders. [8,9] In the present case, gas associated with DCS was not detected in the acute phase, and the onset was after rapid surfacing from a dive, subsided within 30 minutes after arrival without recompression, and there were no symptoms other than vertigo. Accordingly, we diagnosed the patient with AV. [10]

4. Conclusion

We report a case in which ultrasound was useful for differentiating between DCS and drowning in the ER. When patients have symptoms after diving, confirmation of the presence of gas in the portal vein, inferior vena cava, or heart using ultrasound in the acute phase is important for the diagnosis of DCS.

Acknowledgements

This work was supported in part by a Grant-in-Aid for Special Research in Subsidies for ordinary expenses of private schools from The Promotion and Mutual Aid Corporation for Private Schools of Japan.

References

- [1] Cooper JS, Hanson KC. Decompression Sickness. In: StatPearls [Internet]. Treasure Island (FL): StatPearls Publishing; 2021 Jan. 2021 Jul 18.
- [2] Casadesús JM, Aguirre F, Carrera A, Boadas-Vaello P, Serrano MT, Reina F. Diving-related fatalities: multidisciplinary, experience-based investigation. *Forensic Sci Med Pathol.* 2019 Jun; 15(2):224-232.
- [3] Yanagawa Y, Omori K, Takeuchi I, Jitsuiki K, Ohsaka H, Ishikawa K. The on-site differential diagnosis of decompression sickness from endogenous cerebral ischaemia in an elderly Ama diver using ultrasound. *Diving Hyperb Med.* 2018 Dec 24; 48(4): 262-263.
- [4] Zwingelberg KM, Green JW, Powers EE. Primary Causes of Drowning and Near Drowning in Scuba Diving. *Phys Sportsmed.* 1986 Sep; 14(9):145-51.
- [5] Blogg SL, Gennser M, Møllerlørkken A, BrubakkAO. Ultrasound detection of vascular decompression bubbles: the influence of new technology and considerations on bubble load. *Diving Hyperb Med.* 2014; 44: 35-44. PMID: 24687484.

- [6] Spencer MP, Johanson DC; Investigation of new principles for human decompression schedules using the Doppler blood bubble detector. Washington: Office of Naval Research Tech Rep ONR Contract N00014-73-C-0094; 1974.
- [7] Yanagawa Y, Takeuchi I, Ishiyama J. Ultrasound in the diagnosis of acute-phase decompression sickness. *Radiol Case Rep.* 2021 Mar; 16(3): 698-700.
- [8] Ohsaka H, Jitsuiki K, Takeuchi I, Yoshizawa T, Omori K, Ishikawa K, Yanagawa Y. Ultrasound for diagnosing inner ear decompression sickness. *Sch J Med Case Rep* 2016; 4(8): 605-606.
- [9] Scarpa A, Ralli M, De Luca P, Gioacchini FM, Cavaliere M, Re M, Cassandro E, Cassandro C. Inner Ear Disorders in SCUBA Divers: A Review. *J Int Adv Otol.* 2021 May; 17(3): 260-264.
- [10] Francescon D, Jamal Z, Cooper JS. Alternobaric Vertigo. 2021 Jul 18. In: *StatPearls [Internet]*. Treasure Island (FL): StatPearls Publishing; 2021 Jan-. PMID: 29489288.



© The Author(s) 2022. This article is an open access article distributed under the terms and conditions of the Creative Commons Attribution (CC BY) license (<http://creativecommons.org/licenses/by/4.0/>).