

The Association between Epileptiform Activity and Autistic Symptoms in Three Cases with Tuberous Sclerosis

Kunio Yui^{1,*}, George Imataka², Hitomi Sasaki¹, Ryoichi Shiroki¹

¹Department of Urology, Fujita Health University School of Medicine, Aichi, Toyoake, 470-1192, Japan

²Department of Pediatrics, Dokkyo Medical University, Mibu 321-0293, Tochigi, Mibu, Japan

*Corresponding author: yui16@bell.ocn.ne.jp

Received September 10, 2019; Revised October 24, 2019; Accepted October 30, 2019

Abstract This case study examined the association between epileptic activity such as epileptiform discharges and autistic symptoms; and to examine the effect of mTOR inhibitor everolimus on seizures and epileptiform discharges in three cases with TSC and autistic symptoms. The everolimus treatment improved autistic symptoms in all four cases, however, epileptiform discharges did not disappear in all four cases with everolimus treatment. Thus, epileptiform activity and autistic symptoms may be two end-results of separate brain dysfunction. The evrolimus treatment disappeared a seizure in only one case, suggesting partial overlap between mTOR hyperactivity and a seizure in small subset of cases with TSC. This study for firstly revealed that the everolimus treatment was inefficient for epileptiform discharges. Antiepileptic therapy at early stage of brain development might be effective for epileptic activity.

Keywords: tuberous sclerosis complex, seizure control, Epileptiform discharges, autistic symptoms, mTOR inhibitor

Cite This Article: Kunio Yui, George Imataka, Hitomi Sasaki, and Ryoichi Shiroki, "The Association between Epileptiform Activity and Autistic Symptoms in Three Cases with Tuberous Sclerosis." *American Journal of Clinical Medicine Research*, vol. 7, no. 2 (2019): 57-59. doi: 10.12691/ajcmr-7-2-5.

1. Introduction

Most children suffering from TSC with ASD experienced early onset of epilepsy including infantile spasms, West syndrome or focal seizures with impaired awareness [1]. Epileptic activity such as epileptiform discharges (referred to as spikes) in these seizures may contribute to the brain dysfunction as called epileptic encephalopathy,¹ which may sometimes induce autistic symptoms such as impaired communication and repetitive behavior [1]. However, the contribution of epileptiform activity to the development of autistic symptoms remains open to debate [1].

TSC is caused by mutations in the *TSC1* or *TSC2* genes, and induce mTOR hyperactivation, inducing neuropsychiatric impairments and epileptogenesis [2]. mTOR inhibitors (everolimus and rapamycin) improve TSC-associated seizures and ASD, and epileptiform activity such as epileptiform discharge [3]. However, there is few data on potential anti-epileptogenic action of mTOR inhibitors [4].

This study attempted to untangle the association between epileptiform discharges and autistic symptoms; and to examine the effect of everolimus on epileptiform discharges in four cases with TSC. This study may shed light on a new aspect of the neurobiological bases of ASD.

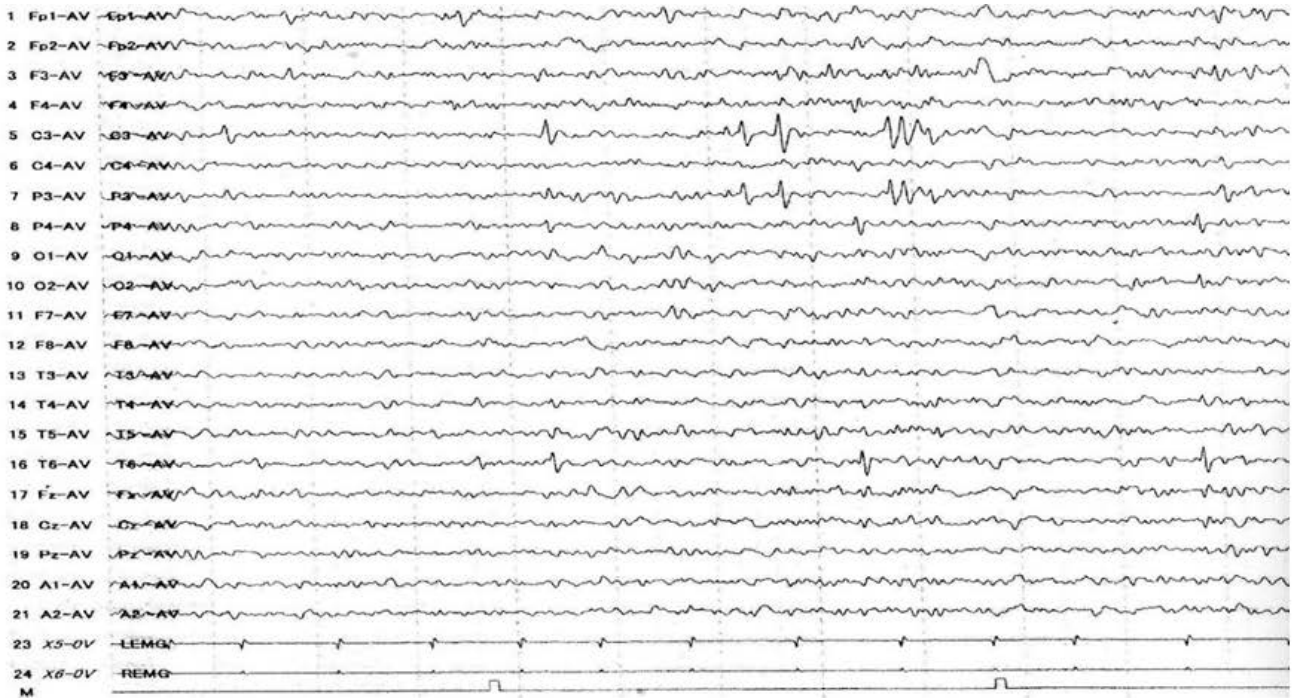2. Case Reports

Case 1 was 10 years old male with TSC accompanied with the autistic social impairment and verbal stereotypy. A subependymal nodule located at the left frontal area and AML were detected, meeting the TSC diagnostic criteria. At age 5 months, the patient experienced a severe epilepsy syndrome of the triad of focal epileptic spasms (West syndrome), characterized by clusters of epileptic spasms, psychomotor delay, and a specific interictal EEG pattern known as hypsarrhythmia. He continued to take anticonvulsants, however his seizures persisted. Thus, he received focal resection of a subependymal nodule, and his seizure disappeared following this resection at age 2 years. However, epileptiform discharges were still detected. At age 10 years, his EEG was highly disorganized with low voltage irregular slow waves intermixed with multifocal spikes. At age 6 years, his ASD symptoms gradually developed. To improve his autistic symptoms and EEG abnormalities, he was treated with everolimus (3.6 mg/day for 24 weeks). The everolimus treatment disappeared autistic symptoms. However, epileptiform discharges persisted.

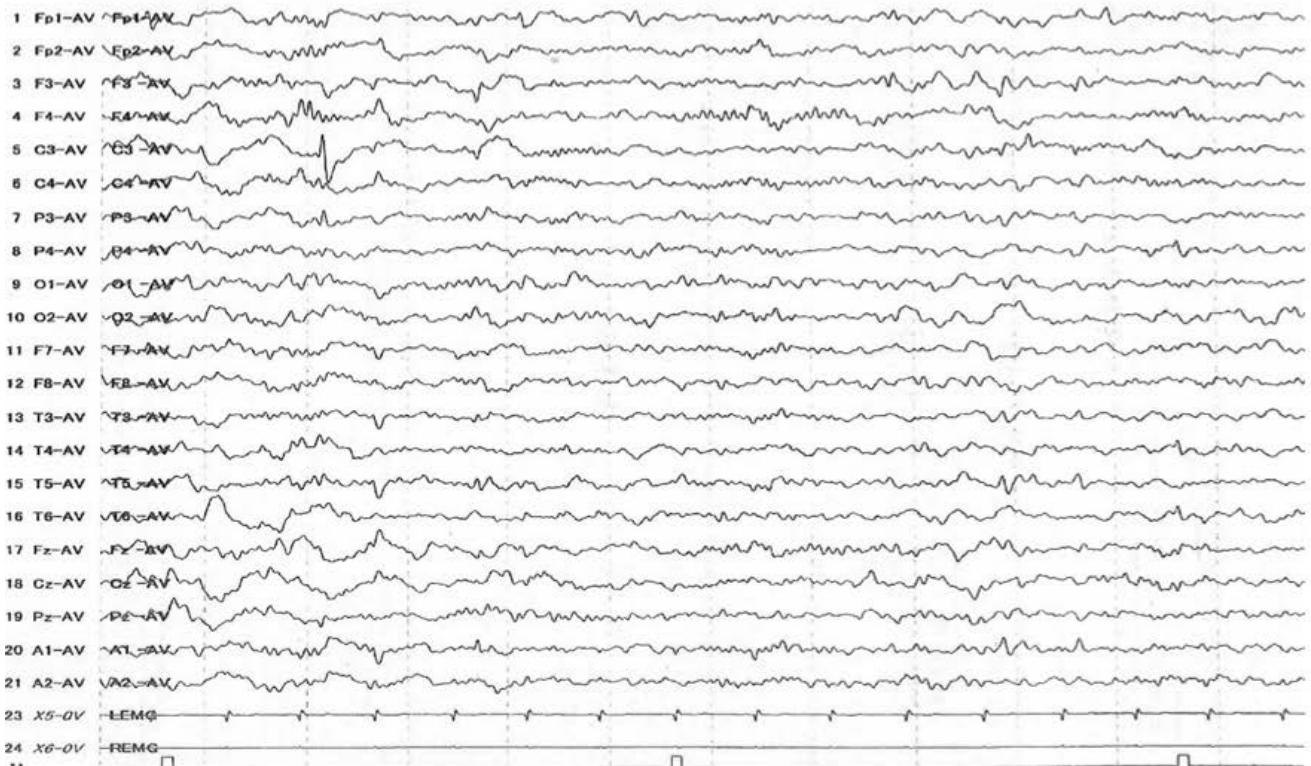
Case 2 was 9 years old girl with TSC accompanied with the autistic social impairment. At age 7 years, a

subdendymal nodule on left anterior horn of lateral ventricle was detected. At age 4 months, she experienced focal seizures with impaired awareness characterized by clusters of epileptic spasms from right face to left hand seizure, following language development delay. She was treated with anticonvulsants, and her seizure disappeared. At age 2 years, she experienced re-occurrence of focal seizure with impaired awareness and treated with clonazepam, resulting disappearance of her seizure.

At age 7 years, her EEG indicated high voltage irregular slow waves intermixed with spikes and polyspikes (hypsarhythmia). At age 4 years, her impaired social interaction gradually developed. Everolimus treatment (2.5 mg/day for 24 weeks) improved social impairment, however, her seizures and epileptiform discharges did not disappear. Thus, at age 9 years, she received complete corpus callosotomy, leading to disappearances of seizures and epileptiform discharges.



A. Before everolimus treatment



B. After everolimus treatment

Figure 1. Electroencephalographic recordings of case 2

Case 3 was age 6 years old girl with TSC accompanied with autistic social impairments and stereotyped behaviors. At age 6 months, SEGA located at the right foramen of Monro and subependymal nodules located at both side interventricular form were detected, meeting the diagnostic criteria for TSC. At age 6 months, she exhibited infantile spasms. At age 13 months, she experienced her first episode of focal seizures with impaired awareness. The patient was treated with various anticonvulsants, however, her epilepsy gradually increased in frequency and severity. Her EEG frequently showed spikes and spike-and-wave complexes at the central areas. Since she was 7 months of age, she developed impaired social interaction. She had difficulty with motor coordination. At age six years, everolimus treatment (3.0 mg/day for 24 weeks) improved autistic symptoms and disappearance of her seizures, however, epileptic discharges persisted.

3. Discussion

Epileptic seizures of case 1 disappeared with antiepileptic therapy before everolimus treatment. Epileptiform discharges disappeared in all four cases during and after the everolimus treatment. Several neurological studies confirmed the relationship of the epileptiform discharges and autistic symptoms [1]. While, some longitudinal case studies postulated that autistic symptoms and seizures may be separate phenotype from a standpoint of mechanisms [1]. Thus, the association between epileptiform discharges and autistic symptoms remains open to debate. This study revealed no overlap between the epileptiform discharges and autistic symptoms in all cases. The core TSC pathophysiology, hyperactivation of the mTOR pathway, induces impaired brain functioning such as abnormalities in intracellular signaling inducing altered neuronal connections, leading to the autistic symptoms and epilepsy [2]. The everolimus treatment improved autistic symptoms in all four cases. Previous studies indicated that mTOR hyperactivity is critical for epileptiform discharges, suggesting that mTOR inhibitors may disappear epileptiform discharges [3]. However, epileptiform discharges did not disappear

with everolimus treatment in all cases. Our finding, considering together with the previous postulation that no clinical data on anti-epileptogenic activity of everolimus [5], and mTOR inhibitors have only stalling effect for epilepsy progress [4], our above finding may be reasonable.

A previous review article suggested overlap in the presentation of epileptogenesis and autistic symptoms [1]. In this study, although everolimus treatment improved autistic symptoms in all four cases, epileptiform discharges did not disappear in all four cases with everolimus treatment. Thus, epileptiform activity and autistic symptoms may be two separate terminal-output of brain dysfunction. Additionally, the present finding that the everolimus treatment disappeared seizure in only case 4 suggested partial overlap between mTOR hyperactivity and seizures in small subset of cases with TSC.

There are few information on the most optional treatment for refractory seizures associated with TSC[5]. Although mTOR inhibitors have efficacy in the treatment of TSC-associated seizures [3], this study for firstly revealed that everolimus treatment may inefficient for epileptiform discharges. Antiepileptic therapy at early stage of brain development might be effective for epileptic activity.

References

- [1] Srivastava S, Sahin M. Autism spectrum disorder and epileptic encephalopathy: common causes, many questions. *J Neurodev Disord.* 2017, 9:23.
- [2] Feliciano DM, Lin TV, Hartman NW, Bartley CM, Kubera C, Hsieh L, et al. A circuitry and biochemical basis for tuberous sclerosis symptoms: from epilepsy to neurocognitive deficits. *Int J Dev Neurosci.* 2013, 31: 667-78.
- [3] Costa V, Aigner S, Vukcevic M, Sauter E, Behr K, Ebeling M, et al. mTORC1 Inhibition Corrects Neurodevelopmental and Synaptic Alterations in a Human Stem Cell Model of Tuberous Sclerosis. *Cell Rep.* 2016, 15(1):86-95.
- [4] Wong M. mTOR as a potential treatment target for epilepsy. *Future Neurol.* 2012, 7:537-545.
- [5] Ryther RC, Wong M (2012) Mammalian target of rapamycin (mTOR) inhibition: potential for antiseizure, antiepileptogenic, and epileptostatic therapy. *Curr Neurol Neurosci Rep.* 2012, 12(4):410-8.

