

Procedural Success and Immediate Results of Percutaneous Trans Mitral Commissurotomy: An Experience from a Tertiary Care Hospital in Northern Division of Bangladesh

Rahman M^{1,*}, Islam MH¹, Uddin MB², Elahi ME³, Mahmud AA¹,
Awal A⁴, Barman RN¹, Sarkar H¹, Ghafur S¹

¹Department of Cardiology, Rangpur Medical College & Hospital, Rangpur, Bangladesh

²Department Cardiology, Kushtia Medical College, Kushtia, Bangladesh

³Department of Medicine, M Abdur Rahim Medical College & Hospital, Dinajpur, Bangladesh

⁴Department of Cardiology, Chittagong Medical College & Hospital, Chattagram, Bangladesh

*Corresponding author: mahbub56dmc@gmail.com

Received May 17, 2021; Revised June 21, 2021; Accepted July 01, 2021

Abstract Background: One of the ultimate grave consequences of rheumatic heart disease is mitral stenosis. Percutaneous trans-mitral commissurotomy (PTMC) has been practiced with good results in the world since Inoue introduced it in 1982. But in Bangladesh we have very few research-oriented data regarding the effectiveness and patient compliance of this procedure. **Aim of the study:** The aim of this study was to audit the procedural success, in-hospital outcome in patients undergoing percutaneous trans-mitral commissurotomy (PTMC). **Methods:** This observational cross-sectional study was conducted in northern division of Bangladesh with the collaboration of the Department of Cardiology, Rangpur Medical College Hospital, Rangpur & Zia Heart Foundation, Dinajpur during the period from February 2018 to November 2019. In total 45 patients who fulfill the inclusion and exclusion criteria for PTMC was enrolled in this study as the study people. Among them the procedural success & immediate results were assessed. Proper written consents were taken from all the participants before starting data collection. A pre-designed questionnaire was used in patent data collection. All data were processed, analyzed and disseminated by MS Office and SPSS version as per need. **Result:** In our study in analyzing the comparative Echo Doppler data of pre & post PTMC among the participants in both mean (\pm SD) MVA (cm²) and mean (\pm SD) MVPG (mmHg) we found extremely statistically significant correlation between pre and post PTMC stages where the P values were less than 0.0001. Besides these, in analyzing the pre & post PTMC hemodynamic and procedural data of participants we observed, against LA Pressure (mmHg) (Mean \pm SD), RV Pressure (mmHg) (Mean \pm SD), LVEDP (mmHg) (Mean \pm SD) and Transmitral PG (mmHg) (Mean \pm SD) there were extremely significant correlation between pre and post PTMC stages. In all the parameters the p values were less than 0.0001. **Conclusion:** We conclude that, percutaneous trans-mitral commissurotomy (PTMC) is a safe procedure in experienced hand with good success rate and optimal results even in patients with special problems like pregnancy, previous CVA and redo cases.

Keywords: Mitral stenosis (MS), Percutaneous Transmitral Commissurotomy (PTMC), immediate outcome

Cite This Article: Rahman M, Islam MH, Uddin MB, Elahi ME, Mahmud AA, Awal A, Barman RN, and Sarkar H, "Procedural Success and Immediate Results of Percutaneous Trans Mitral Commissurotomy: An Experience from a Tertiary Care Hospital in Northern Division of Bangladesh." *American Journal of Cardiovascular Disease Research*, vol. 7, no. 1 (2021): 4-9. doi: 10.12691/ajcdr-7-1-2.

1. Introduction

Rheumatic heart disease is still a common problem in Bangladesh and other developing countries, though its incidence is on decline in the western world. The prevalence of rheumatic fever in Bangladesh is 0.6/1000 population and that of rheumatic heart disease is 0.3/1000 [1]. Most frequently affected valve in rheumatic heart

disease is Mitral valve, in 40% cases other heart valves are also affected along with Mitral valve but in 25% patients, Mitral valve is solely affected [3]. Mitral stenosis is more common in female while in male mitral regurgitation is more common. Male are more prone to suffer from aortic valve disease than female [4] and it results in increased morbidity and mortality [5]. Mitral stenosis alone or in combination with other valvular lesions is almost always rheumatic in origin [6] while other valvular lesions may have etiologies other than rheumatic fever. An

exceedingly rare form of mitral stenosis is congenital stenosis which is associated with high mortality in first few years of life [7]. In our subcontinent, during pregnancy most common cardiac lesion detected is mitral stenosis, rheumatic in origin [8] and it is due to overcrowding and poor socioeconomic status of population. Late diagnosis and late referral for management to specialized cardiac centers are the main problems responsible for these complications and sometimes lack of resources are also responsible for it. In 1982, Inoue K and colleagues were the first to perform percutaneous trans-mitral commissurotomy (PTMC) and since then PTMC is the treatment of choice for symptomatic patients with moderate to severe MS having suitable valves for PTMC. In pregnancy, medical treatment is the first line of treatment and PTMC is only indicated when patients do not respond to medical treatment and / or patients presented with repetitive or persistent heart failure. Due to high maternal (1.7%-3.1%) and fetal (5%-33%) mortality rate, surgical commissurotomy is not good option in pregnancy [9]. In literature, there is almost more than 10 years documented experience of PTMC for mitral stenosis in pregnancy [10]. We can delay mitral valve replacement surgery for ten or more years in patients who benefited from PTMC with additional option to redo PTMC later on in suitable cases [11,12]. Two main techniques of commissurotomy are in the world; the balloon and the Metallic Commissurotomy. The Inoue balloon is the most commonly used technique today worldwide and it was also used by the authors. Other balloon techniques are: (a) Double balloon technique and (b) Multitrack technique; it is the refinement of the double balloon technique that employ a monorail system first described by Bonhoeffer et al [13]. Metallic commissurotomy was introduced by Cribier et al in 1990s [14]. It carries a high risk of haemo-pericardium due to stiff guide wire in LV cavity and now it is not commonly used. The potential advantage of this technique is its cost effectiveness. Mitral regurgitation is a major complication of PTMC [15] and its incidence is 1.4% - 7.5% as documented in the literature [16]. Immediate results of PTMC are predicted from mitral valve anatomy as was evident in many studies. Regarding the procedural success and hemodynamic effects of PTMC very few studies have been done and data in Bangladesh is not sufficient. The objective of this study was to audit all my cases of PTMC, so far, I have done from Feb 2018 to November 2019 at department of Cardiology, Rangpur Medical College Hospital, Rangpur & Zia Heart Foundation, Dinajpur, those are at northern division of Bangladesh.

2. Methodology & Materials

This was an observational cross-sectional study conducted from Feb 2018 to November 2019 at the Department of Cardiology, Rangpur Medical College Hospital, Rangpur & Zia Heart Foundation, Dinajpur of Bangladesh. In total 45 patients were enrolled as study people. According to the inclusion criteria of this study

patients (Male or female) of age ≥ 10 years having symptomatic MS with NYHA functional class II or more with mitral valve area (MVA) ≤ 1.5 cm² and mitral valve Echocardiographic score ≤ 11 according to scoring system described by Wilkins et al. were included. On the other hand, according to the exclusion criteria of this study patients with significant mitral regurgitation (MR ≥ 2), bilateral Commissural calcification, clot in LA and/or LAA, presence of other lesions which need open heart surgery, Wilkin Score > 12 , end stage renal or liver disease and with severe COPD were excluded. Besides these, patients were excluded if valve area measurement was performed using other methods than area tracing technique (like mean trans-mitral diastolic pressure gradient technique or pressure-half-time technique) in a setting of associated mitral regurgitation. Informed written consent from all the patients who participated in the study was taken. The demographic data regarding age, gender, occupation etc. were collected and a detailed physical examination especially relevant cardiovascular examination of all the patients were done. Symptoms regarding their referral for medical checkup were recorded. Height, weight and other anthropometric measurements of all the patients were taken at the hospital using standardized techniques. Previous record of each patient was scrutinized and noted. Baseline routine investigations including complete blood count with ESR, electrolytes, CRP, LFT, RFT were done in each case. Any rheumatic activity was assessed by looking the ESR, CRP of the patient. To evaluate rate and arrhythmia like atrial fibrillation ECG was performed at the time of examination and at morning on procedure day. To see signs of pulmonary oedema, pulmonary hypertension and other lung pathology like pulmonary infarction and infection, X-ray chest PA view was done. From clinical symptoms and signs functional status of the patients was graded according to the New York Heart Association (NYHA). A baseline color echocardiogram was performed in all patients. Examination was acquired by using a commercially available system (GE, vivid S-70N, USA) equipped with 2.5 and 3.5MHz transducers. Mitral stenosis was assessed with 2D, Spectral and Color Doppler echocardiography. Mitral valve area was calculated by planimetry using 2D Echo in parasternal short axis view and by pressure half time method, then finally valve area was determined by averaging the values. Every patient was subjected to Continuous Wave (CW) and Pulse Wave (PW) Doppler studies in apical 4 chambers view. Mitral valve gradient (Peak and Mean) observed in left ventricular inflow in each case. In apical 4 chamber view tricuspid pressure gradient was used to assess pulmonary artery pressure. Severity of mitral stenosis was graded as: very severe stenosis (valve area < 1 cm²), severe (valve area 1-1.5 cm²) moderate (valve area 1.5-2 cm²) and mild (valve area > 2.0 cm²). Transthoracic echocardiographic examinations were done within a week before intervention, during procedure and one day after the procedure. To assess the mitral valve morphology, Wilkins scoring systems were used.

Table 1. Echocardiographic Wilkin's scoring system to predict PTMC outcome

Grade	Mobility	Valvular Thickening	Calcification	Sub-valvular Thickening
1	Only tips of leaflet restricted	Thickness of leaflet is near normal (4-5 mm)	Echo brightness increased at a single area	Just below the mitral valve there is minimal thickening.
2	Leaflets show reduced mobility in basal and middle portions	Margins of leaflet are markedly thickened	Leaflet margins show scattered areas of brightness	1/3 rd of chordal length show thickening of chordal structures.
3	Mainly base of leaflet move forward in diastole	Entire leaflet show thickening (5-8 mm)	Up to mid portion of leaflet brightness extends	Thickening extends up to distal 1/3 rd of chordate
4	In diastole leaflet show minimal forward movement	Whole leaflet tissue shows marked thickening (>8-10 mm)	Most of the leaflet tissue show extensive brightness	Subvalvular apparatus shortened and extensively thickened up to papillary muscles.

Presence of MR with its severity was noted. Color flow mapping was used to assess MR severity by expressing the ratio of maximal jet area to left atrial area in the same view and was graded from one to four according to Essop et al. In cases of uncertainty, PISA method was used to assess MR severity. Presence of commissural calcification is another important factor to determine the suitability for PTMC and was assessed on 2D echocardiographic short-axis view. Commissural calcification (1 or both commissures) is an independent predictor of near-term success during the procedure, as well as long-term outcome¹⁷. In Cath. Lab pre and post PTMC invasive hemodynamics including LA, RA, RV, left ventricular end-diastolic pressure (LVEDP), and transmitral pressure gradient (PG) was calculated. The patient remained in the supine position during the procedure. There are two approaches to reach mitral valve, retrograde (Transarterial) and anterograde (Transvenous) approach. The retrograde approach has a potential risk of arterial damage but eliminates risk of residual ASD after PTMC [18]. Most commonly used approach in the world is antegrade through right femoral vein [19] and it was adopted by us. Interatrial septal puncture was done in lateral projection with Brockenbrough needle at 4° clock to 6° clock at fossa ovalis level. In supine position when we look from foot side of the patient atrial septum runs from 1° clock to 7° clock. Successful entry into the left atrium was confirmed by pressure tracing, by withdrawing oxygenated blood from LA and typical fluoroscopic picture during contrast injection. Those patients who have echo contrast on echocardiography were given 5000 IU heparin IV after septal puncture. As described in literature, standard protocol for PTMC was adopted [14]. Antibiotic prophylaxis was initiated in all patients thereafter. The procedure was performed under local anesthesia, if needed moderate sedation was given with midazolam. As a rule of thumb the equation was used to choose balloon size as-PTMC: Balloon Size=(Patients height in cm÷10+10). In some special cases for septal puncture transthoracic echo was used. After each inflation, balloon was withdrawn in LA to measure LA pressure or to assess MR on color Doppler. Abrupt increase in LA or pulmonary artery pressure, suggests acute severe MR. The procedure was ended when either adequate increase in mitral valve area or increase in degree of MR or decrease in mitral valve gradient was observed. In Cath Lab. on the basis of hemodynamic criteria we evaluated the immediate results. For good immediate results frequently two definitions were used. First one is valve area $\geq 1.5\text{cm}^2$ without mitral regurgitation ≥ 2 and the second one is valve area $\geq 1.5\text{cm}^2$ with an increase in valve area of at least 50% of pre

PTMC area. At the end of procedure RA, RV, pulmonary artery pressure, LA pressure, LVEDP, was measured with multipurpose catheter. After 24-48 hours patient was discharged and before discharge transthoracic echo was done to measure all the parameters as pre PTMC along with any echo finding of pericardial effusion. Data were analyzed by SPSS (Statistical Package for Social Sciences). Significance testing of difference between proportions was conducted with a value corresponding to $p < 0.05$ for significance.

3. Result

In this study total 45 patients were studied. Among them 27% (n=12) were male whereas 73% (n=33) were female. So female was dominating in number and the male-female ratio was 1:2.75. The mean age of the participants was 29.28 ± 8.4 , ranged from 10 to 60 years. In this study the highest number of participants were from 21-30 years' age group which was 51%. Then 27% 11%, 7% and 4% participants were from 10-20, 31-40, 41-50 and 51-60-years' age groups respectively. Among total participants 27 (60%) patients were with atrial fibrillation and the rest 18 (40%) had sinus rhythm. The procedure was successful in 43 (95.56%) patients and PTMC was unsuccessful and was abandoned in 1 (2.22%) patient. In one patient we failed to puncture the septum due to giant LA with aneurismal thick septum. In this study 33.33% and 73.33% participants were with NYHA Class II, NYHA Class III respectively. After PTMC, iatrogenic ASD was present in 2 (4.44%) patients. Before procedure 4 (8.89%) patients had G-I MR.

After PTMC, G-I MR was present in 3 (6.67%) patients & G-II MR was seen in 2 (4.44%) patients. In this study in pre PTMC period pulmonary hypertension (mmHg) was found mild, moderate and severe among 4.44%, 13.33% and 82.22% patients respectively. On the other hand, in post PTMC period pulmonary hypertension (mmHg) was found mild, moderate and severe among 73.33%, 22.22% and 4.44% patients respectively ($P=0.440$). But in analyzing the comparative Echo Doppler data of pre & post PTMC among the participants in both mean (\pm SD) MVA (cm^2) and mean (\pm SD) MVPG (mmHg) we found extremely statistically significant correlation between pre and post PTMC stages where the P values were less than 0.0001. Besides these, in analyzing the pre & post PTMC hemodynamic and procedural data of participants we observed, against LA Pressure (mmHg) (Mean \pm SD), RV Pressure (mmHg) (Mean \pm SD), LVEDP (mmHg) (Mean \pm SD) and Transmitral PG (mmHg) (Mean \pm SD) there

were extremely significant correlation between pre and post PTMC stages. In all the parameters the p values were less than 0.0001.

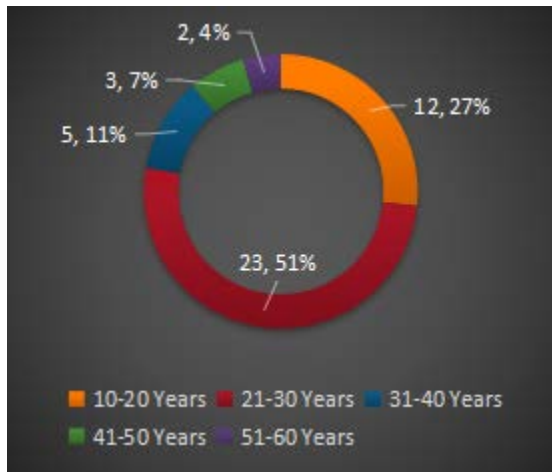


Figure 1. Age distribution of participants (n=45)

Table 2. Baseline characteristic of patients (n=45)

Variables	n	%
Gender		
Female	33	73%
Male	12	27%
Rhythm		
Atrial Fibrillation	27	60.00%
Sinus Rhythm	18	40.00%
Other Associated Lesions		
Mild AR	5	11.11%
Successful PTMC	43	95.56%
PTMC Abandoned/Unsuccessful	1	2.22%
NYHA Class		
NYHA Class II	15	33.33%
NYHA Class III	33	73.33%
NYHA Class IV	0	0

Table 3. Comparative Echo Doppler data of Pre & Post PTMC (n=45)

Parameters	Pre PTMC	Post PTMC	P value
Mean (±SD) MVA (cm ²)	0.92±0.14	1.43±0.28	<0.0001
Mean (±SD) MVPG (mmHg)	26.94±6.18	8.07±4.78	<0.0001
Pulmonary Hypertension (mmHg)			
Mild	2 (4.44%)	33 (73.33%)	0.440
Moderate	6 (13.33%)	10 (22.22%)	
Severe	37 (82.22%)	2 (4.44%)	
Mitral Regurgitation			
G-I	4 (8.89%)	3 (6.67%)	0.454
G-II	0	2 (4.44%)	
G-II+	0	0	

Table 4. Pre & post PTMC hemodynamic and procedural data of participants (n=45)

Parameters	Pre PTMC	Post PTMC	P value
LA Pressure (mmHg) (Mean ±SD)	29.05±8.63	11.77±6.16	<0.0001
RV Pressure (mmHg) (Mean ±SD)	64.82±9.32	43.22 ±8.39	<0.0001
LVEDP (mmHg) (Mean ±SD)	3.31±2.11	6.37±2.25	<0.0001
Transmitral PG (mmHg) (Mean ±SD)	25.93±5.46	6.72±4.04	<0.0001

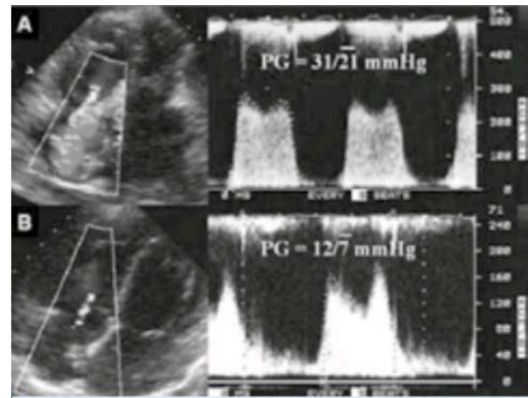


Figure 2. Echocardiographic pressure gradient across mitral valve

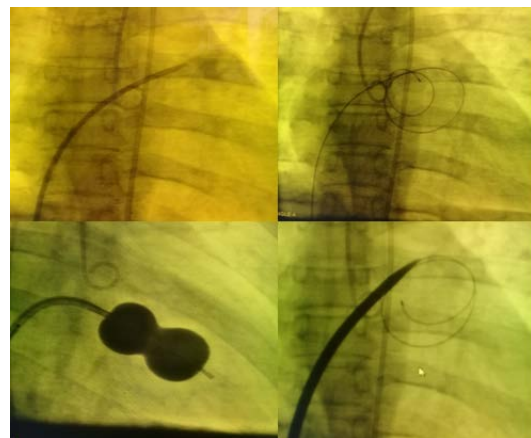


Figure 3. Several steps of PTMC

4. Discussion

Rheumatic heart disease is the most frequent cause of abnormal valvular function. In the United States the prevalence of rheumatic fever is less than 1/100000 people and in India and other developing countries prevalence is 100–150 cases per 100,000 people. Due to aggressive initial attack, rheumatic heart disease may develop as early as in teenage.

In Bangladesh and other developing countries Mitral stenosis is mostly rheumatic in origin. Due to overcrowding and low socioeconomic background, it is more common in young female. Percutaneous Transcatheter Mitral Commissurotomy (PTMC) is treatment of choice for symptomatic mitral stenosis patients [12] since 1982, after the first mitral valvuloplasty by Inoue et al [20]. Prediction of procedural success and immediate results is multifactorial. Independent predictors for procedural success and immediate results are; severity of mitral stenosis, presence of MR before PTMC, annular or commissural calcification, pulmonary artery pressure, severity of TR, history of previous commissurotomy, age of patient, NYHA functional class and morphologic factors [18]. In the study, procedure was successful in 29 (96.66%) patients. These results coincide with the results of international studies conducted by M S Alkhalife et al [21] and Syed Dawood Md et al [22] in which procedural success was 94.5% and 95% respectively. One subcontinental study conducted at Peshawar, Pakistan by Sher Bahader Khan et al [23] showed procedural success

in 96% patients which coincides with our results. In 1% to 17% patients, PTMC may be unsuccessful and this failure result due to unfavorable anatomy i.e giant LA, thick septum, during initial portion of learning curve of the operator, sub-valvular disease or heavy calcification or special problem like hiatus hernia, kyphoscoliosis and in our study PTMC was unsuccessful or/and abandoned in 1(3.33%) patient and this result coincide with other international studies. The PTMC was considered unsuccessful if we could not succeed to puncture the septum, failure to cross the balloon through septum, or cannot cross MV or both commissures remained fused after balloon inflation. Most commonly documented complication of PTMC is mitral regurgitation and frequency of severe MR varies from 2% to 19% [24]. Significant MR is defined as MR of $\geq 2/4$ grade. Our results showed that 2(6.66%) got G-I MR & 1(3.33%) had MR grade II and these results coincide with other studies. Factors predicting severe MR during PTMC are not fully understood and rather controversial [25]. This complication is related to tear of the posterior or anterior leaflet. Sometimes due to asymmetrical significant commissural calcification, severe MR can occur due to the non-calcified commissural tear. After balloon valvuloplasty, the frequency of atrial septal defects in different studies ranges from 10% to 90% and these shunts are very small and left to right restrictive shunt. Sometimes, though rare due to very severe pulmonary hypertension these shunts are right-to-left. In this study, frequency of iatrogenic ASD was observed in 2(6.66%) patients and it coincides with other studies results. In this study, we could not perform PTMC for one patient(3.33%) due to failure of septal puncture due to giant LA & aneurismal thick septum. There was no mortality (00%) regarding his study. One patient was resuscitated during procedure for haemopericardium due to free wall puncture. Blood from pericardium was aspirated and auto transfusion was done and patient was survived. Incidence of procedural mortality is documented 0-3% in other studies which coincide with our results. Poor general health and free wall perforation are the main causes of mortality. 0.5% to 12.0% patients may develop hemopericardium and this is due to free wall perforation by guide wires or balloon or during septal puncture. If haemopericardium occurs emergency pericardiocentesis should be done and patient should be transfer immediately to cardiac surgery after stabilization. During PTMC incidence of embolic events ranges 0.5% to 5.0% and sometimes but rarely this embolic event can cause death or permanent disability and in our study no patient got ischemic / embolic event. To avoid this complication TEE is must especially in patients having atrial fibrillation or previous history of TIA or stroke and high-risk patients having lot of echo contrast in LA/ LAA must be given heparin after septal puncture. About 1.5% patients may develop complete heart block during PTMC and it is mostly transient and very rarely may require a permanent pacemaker. In our study no patient (00%) patient got this complication. The frequency of restenosis in different studies at 3-10 years interval after percutaneous mitral valvuloplasty is 2% to 40%. It is defined as loss of more than 50% of area gained during PTMC with a valve area less than 1.5 cm². Re do balloon valvuloplasty or surgical mitral valve replacement are

options for restenosis after PTMC [18,26,27]. In our study, we performed one re do PTMC.

5. Limitations of the Study

This study has number of limitations. First, we could not perform transoesophageal echo because of lac and unavailability of such super-specialized investigation in such a peripheral part of the country. Second, this was a hospital-based study. There was possibility that only patients with advanced disease and significantly symptomatic cases were referred to us, representing the proverbial tip of a very great iceberg. The patients included in the study, are not likely to be the representative of the disease burden in our community.

6. Conclusion and Recommendations

Percutaneous transmitral valvuloplasty (PTMC) is a safe and effective intervention for patients with severe MS and suitable valve in expert hand and even during special situations like pregnancy and re do cases. In our population, large definitive studies to be executed. A screening program on echocardiography-based is the need of time to determine the true prevalence of rheumatic valvular diseases especially in our childhood population and to strengthen the commitment to primary and secondary prevention programs.

References

- [1] M. Mostafa Zaman et al. Prevalence of rheumatic fever & rheumatic heart disease in Bangladeshi children. *Indian Heart J* 2015; Jan-Feb, 67(1):45-49.
- [2] Eisenberg MJ. Rheumatic heart disease in the developing world: prevalence, prevention and control. *Euro Heart J* 1993; 14(1): 122-128.
- [3] Braunwald E. *Heart Disease: A text book of cardiovascular medicine*. 6th edition. Philadelphia W B Saunders 2001; 291-294.
- [4] Movahed MR, Ahmad Kashani M, Kasravi B, Saito Y. Increase prevalence of mitral stenosis in women. *J Am Soc Echocardiogr* 2006; 19: 911-913.
- [5] Ozer O, Davutoglu V, Sari I, Akkoyun DC, Suco M. The spectrum of rheumatic heart disease in the south eastern entolia endemic region. Results from 1900 patients. *J Heart Valve Dis* 2009; 18: 68-72.
- [6] Padamavati S: Rheumatic fever and rheumatic heart disease in developing countries. *Bull World Health Org Suppl* 1978; 56: 543-550.
- [7] Moore P, Adatia I, Spevak PJ, et al: Severe congenital mitral stenosis in infants. *Circulation* 1994; 89: 2099-2106.
- [8] Rizvi SF, Khan MA, Kundi A, Marsh DR, Samad A, Pasha O. Status of rheumatic heart disease in rural Pakistan. *Heart* 2004; 90: 394-399.
- [9] Elkayam U, Bitar F. Valvular heart disease and pregnancy part I: native valves. *J Am Coll Cardiol* 2005; 46: 223-230.
- [10] Esteves CA, Munoz JS, Braga S, Andrade J, Meneghelo Z, Gomes N, et al. Immediate and long-term follow-up of percutaneous balloon mitral valvuloplasty in pregnant patients with rheumatic mitral stenosis. *Am J Cardiol* 2006; 98: 812-816.
- [11] Mohamed Ben et al. Percutaneous balloon versus closed and open mitral commissurotomy seven year follow up results of a randomized trial. *Circulation* 1998; 97:245-250.

- [12] Bonow RO, Carabello B, de Leon AC Jr, et al. ACC/AHA guidelines for the management of patients with valvular heart disease: a report of the American College of Cardiology/American Heart Association task force on practice guidelines (committee on management of patients with valvular heart disease). *J Am Coll Cardiol* 1998; 32: 1486-1588.
- [13] Bonhoeffer P, Esteves C, Casal U, et al. Percutaneous mitral valve dilatation with the Multi-Track System. *Catheter Cardiovasc Interv* Oct 1999; 48(2):178-186 [Medline].
- [14] Cribier A, Eltchaninoff H, Koning R, Rath PC, Arora R, Imam A, et al. Percutaneous mechanical mitral commissurotomy with a newly designed metallic valvulotome: immediate results of the initial experience in 153 patients. *Circulation* Feb 1999; 99(6):793-799. [Medline].
- [15] Kaul UA, Singh U, Kalra G, et al. Mitral regurgitation following percutaneous transvenous mitral commissurotomy: a single-center experience. *Journal of Heart Valve Disease* 2000; 9(2): 262-268.
- [16] Padial LR, Freitas N, Sagie A, et al. Echocardiography can predict which patients will develop severe mitral regurgitation after percutaneous mitral valvulotomy. *J Am Coll Cardiol*. 1996; 27(5): 1225-1231.
- [17] Bonow RO, Carabello BA, Chatterjee K, de Leon AC Jr, Faxon DP, Freed MD, et al. 2008 focused update incorporated into the ACC/AHA 2006 guidelines for the management of patients with valvular heart disease: a report of the American College of Cardiology/ American Heart Association Task Force on Practice Guidelines (Writing Committee to revise the 1998 guidelines for the management of patients with valvular heart disease). Endorsed by the Society of Cardiovascular Anesthesiologists, Society for Cardiovascular Angiography and Interventions, and Society of Thoracic Surgeons. *J Am Coll Cardiol* 2008; Sep 23. 52(13):e1-142. [Medline].
- [18] Topol EJ. Mitral valvuloplasty. *Textbook of Interventional Cardiology*. 5th. Saunders Elsevier 2008; 50.
- [19] Joseph G, Chandy S, George P, George O, John B, Pati P, et al. Evaluation of a simplified transseptal mitral valvuloplasty technique using over-the-wire single balloons and complementary femoral and jugular venous approaches in 1,407 consecutive patients. *J Invasive Cardiol* Mar 2005; 17(3):132-138. [Medline].
- [20] Inoue k, Owaki T and Nakamura T. Clinical application of transvenous mitral commissurotomy by a new balloon catheter. *Journal of Thoracic and Cardiovascular Surgery* 1984;87(3): 394-402.
- [21] M S Alkhalifa, Huda H M Elhassam, F A Suleman, Ibtisam A Ali, Tamadur E Elsadig, M K Awad Gasim. Percutaneous Transmitral Balloon Commissurotomy (PTMC): Procedural success and immediate results at Ahmed Gasim Cardiac Center Khartoum Sudan. *Sudan JSM*. Dec 2006; 1(2): 115-119.
- [22] Syed Dawood Md, Rezaul Karim, M. Maksumul Haq, Md Liaquat Ali, Mahbub Mansur Mashhud Zia Chowdhury et al. Percutaneous Transvenous Mitral Commissurotomy. In-Hospital Outcome of Patients with Mitral Stenosis. *Ibrahim Card Med J* 2011; 1(2): 24-28.
- [23] Sher Bahader Khan, Jabar Ali, Rafiullah, Sultan Zeb, Muhammad Irfan, Adnan Mahmood Gul, et al. Percutaneous Commissurotomy (PTMC): Procedural Success and Immediate Results. *PJC Jan- June 2013*; 24(1,2): 5-10.
- [24] Varma PK, Theodore S, Neema PK, Ramachandran P, Sivadasanpillai H, Nair KK, et al. Emergency surgery after percutaneous transmitral commissurotomy: operative versus echocardiographic findings, mechanisms of complications, and outcomes. *J Thorac Cardiovasc Surg*. Sep 2005; 130(3): 772-776. [Medline].
- [25] M. R. Essop, T. Wisenbaugh, J. Skoularigis, S. Middlemost, and P. Sareli, "Mitral regurgitation following mitral balloon valvotomy. Differing mechanisms for severe versus mild-to-moderate lesions. *Circulation*. 1991; 84(4): 1669-1679.
- [26] Wang A, Krasuski RA, Warner JJ, Pieper K, Kisslo KB, Bashore TM, et al. Serial echocardiographic evaluation of restenosis after successful percutaneous mitral commissurotomy. *J Am Coll Cardiol*. Jan 2002; 39(2): 328-334. [Medline].
- [27] Fawzy ME, Shoukri M, Al Buraiki J, Hassan W, El Widaal H, Kharabsheh S, et al. Seventeen years' clinical and echocardiographic follow up of mitral balloon valvuloplasty in 520 patients, and predictors of longterm outcome. *J Heart Valve Dis*. Sep 2007; 16(5): 454-460. [Medline].

