

PRIMARY SQUAMOUS CELL CARCINOMA BREAST: A RARE CASE REPORT**Neha Kakkar¹, Garima Singh¹, Deepti Sharma¹, Ajay Gupta¹, Fousia Siraj²****Abstract**

Primary Squamous Cell Carcinoma breast is a rare malignancy. SCC of the breast was first reported by Troell in 1908. The etiology and pathogenesis of squamous cell carcinoma of the breast is still unclear. It is thought to arise directly from the epithelium of the mammary ducts, although an alternate theory is that the tumor arises from foci of squamous metaplasia within a preexisting adenocarcinoma of the breast. These tumors are usually hormone receptor and human epidermal growth factor receptor negative. It is an aggressive tumour with poor prognosis frequently refractory to the conventional chemotherapy for breast cancer. Here we are presenting a case report of a primary squamous cell carcinoma of the breast with brief review of the literature.

Author Affiliations:

¹ Department of Radiation Oncology, VMMC & Safdarjung Hospital, New Delhi -110029

² Department of Pathology, VMMC & Safdarjung Hospital, New Delhi -110029

Keywords: Squamous cell carcinoma, Receptor negative, Anthracyclin, Taxane chemotherapy***Corresponding Author:**

Dr. Garima Singh MD, Assistant Professor, Department of Radiation Oncology, VMMC and Safdarjung Hospital, New Delhi -110029.

Email ID: singh.garima3025@gmail.com, **Mob:** +91-9953480093

INTRODUCTION

Primary Squamous Cell Carcinoma breast is uncommon constituting 0.1% of all breast cancers [1]. It is diagnosed if more than 90% of the malignant cells are squamous cells [2] with tumor having no connection with the breast skin and nipple [3] and excluding other sites of primary squamous cell carcinoma e.g. oral cavity, oesophagus, bladder, ovary, cervix [4]. Metaplastic change of ductal carcinoma cells of breast is said to be the likely pathogenesis [6]. These tumors are usually hormone receptor and HER 2 neu negative while EGFR is over-expressed human epidermal growth factor receptor negative [2]. It is an aggressive tumour with poor prognosis frequently refractory to the conventional chemotherapy for breast cancer. More studies are needed to look for treatment options to improve the outcome of squamous cell pathological subtype of breast cancer. There is lack of data on this rare neoplasm with only some small series reported in the literature. Here we are presenting a case report of a primary squamous cell carcinoma of the breast with brief review of the literature.

Case Presentation

54 years old unmarried lady presented with complaints of painful fungating mass

involving the left breast [Figure 1] for 5 months duration.

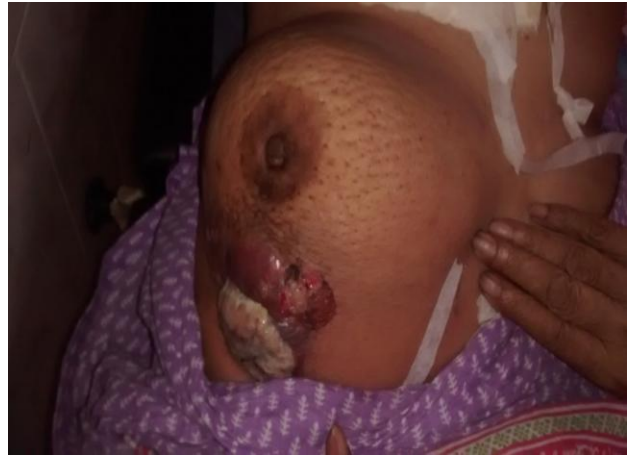

Figure 1: A fungating mass involving the left breast

Her past medical history as well as family history was not significant. Physical examination revealed an ulcero-proliferative growth of 8cm × 7cm, involving upper inner quadrant of left breast with invasion of overlying skin associated with bleeding and foul smelling pus discharge. The nipple was retracted without any associated discharge. There was associated peau d'orange noted on the surrounding skin. The growth was fixed to the chest wall. A 4cm × 5cm lymph node, non-tender, fixed to underlying structures was present in the left axilla. The metastatic work up was done which came out to be negative. Thus, it was clinically T4cN2aM0, Stage IIIC. Core biopsy was done from the growth which revealed squamous cell carcinoma breast.

[Figure-2] ER/PR/Her2neu status was triple negative. Patient received neo-adjuvant chemotherapy-Cyclophosphamide, Adriamycin and 5-FU. On assessment after three cycles of neo-adjuvant chemotherapy there was no reduction in the size of growth, thus the patient was labelled a non-responder to the anthracycline based chemotherapy. It was decided to shift to taxane based chemotherapy but patient refused for further treatment due to complaint of generalised weakness and was taken on best supportive care. The patient expired 2 months later.

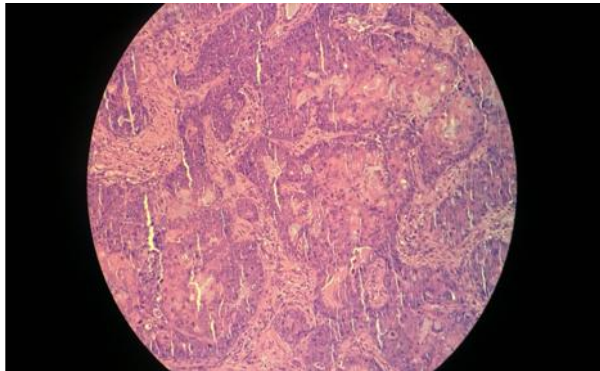


Figure 2- Histopathology(H & E section) showing stratified squamous epithelium lined tissue with underlying squamous cells arranged in clusters and infiltrating into the stroma. (A 4X) (B 10X)

Discussion

Primary squamous cell carcinoma of the breast is very rare. SCC of the breast was first reported by Troell in 1908. The etiology and pathogenesis of squamous cell carcinoma of the breast is still unclear. It is

thought to arise directly from the epithelium of the mammary ducts, although an alternate theory states the origin of tumor from foci of squamous metaplasia within a preexisting adenocarcinoma of the breast^[5]. Many cases have reported initial breast benign disorder (abscess or after implantation of a breast prosthesis or after radiation therapy)^[6] progressing into primary squamous cell carcinoma. This can be explained by squamous cell metaplasia seen in cysts, chronic inflammations, abscesses and adenofibromas ^[4]. The patient in our study was diagnosed at the age of 54 years which is in correlation with the mean age at presentation of 54 years reviewed in the literature.^[7] There is lower frequency of axillary lymph node metastasis seen in squamous cell carcinoma as compared to adenocarcinoma breast. Around 10-30% of the patients present with axillary lymphadenopathy while 30% subsequently develop distant metastasis ^[8]. In a case series of 33 squamous cell carcinoma breast patients reported by Hennessy et al ^[2] 50% of the patients had regional lymph node metastasis at the time of presentation. In this case, the patient had 4cm × 5cm right axillary lymph node which was fixed to the underlying structures. The patient in our report had negative ER/PR receptor and

HER2/neu tumor status, which coincides with the literature showing that squamous cell carcinomas are generally hormone receptor and Her 2 neu negative^[2].

Breast SCC is an aggressive disease with its clinical behavior very much similar to basal type of breast cancer, suggesting that breast SCC originates from a progenitor cell in the breast^[9]. Usually patients do not respond to anthracycline/taxane based chemotherapy though some response has been seen with platinum based chemotherapy^[10]. Our patient had received three cycles of anthracycline based neoadjuvant chemotherapy but no response was seen. The poor outcome of patients with conventional breast cancer chemotherapy suggests looking for other treatment modalities like targeted therapy with EGFR inhibitors. Combination of EGFR inhibitors with platinum agents and taxanes in the treatment of this disease thus needs to be explored in an attempt to improve outcomes. Moreover concurrent chemo radiation with platinum based chemotherapy for this entity may also be looked on to based on the good results of this combination in SCC of other anatomic sites.

Conclusion

Primary squamous cell carcinoma of the breast is a rare entity with poor outcome..It

is an aggressive disease and is generally refractory to conventional chemotherapy used for adenocarcinoma breast. It is generally negative for hormone receptors and HER2/neu status, thus hormonal therapy also has a limited role in the treatment. Thus different chemotherapy regimens and other novel agents should be looked for the treatment options. Role of platins, taxanes and anti-EGFR in various combinations along with their use with concurrent radiation needs to be explored to improvise the results. Study of basal or myoepithelial markers can be helpful to clarify the origin, behaviour of SCC and to develop other treatment modalities for better outcomes.

Acknowledgement- I acknowledge the support of Dr.Ajay Gupata for providing guidance, my patient and Department of Radiotherapy.

Conflict Of Interest Statement-There is no conflict of interest.

Funding-No

Consent- Consent taken from patient.

References

1. Rosen PR: Rosen's Breast Pathology. Chapter 19. Philadelphia, PA, Lippincott Williams & Wilkins, 2001, p. 455-461, 1997.

2. Hennessy BT, Krishnamurthy S, Giordano S. et al. Squamous cell carcinoma of the breast. *J ClinOncol* 2005;23 (31):7827-35.
3. Weigel RJ, Ikeda DM, Nowels KW. Primary squamous cell carcinoma of the breast. *South Med J* 1996;89 (5):511-5.
4. Behranwala KA, Nasiri N, Abdullah N, et al. Squamous cell carcinoma of the breast: clinico-pathologic implications and outcome. *Eur J SurgOncol* 2003;29(4):386-9.
5. Stevenson JT, Graham DJ, Khiyami A, Mansour EG: Squamous cell carcinoma of the breast: A clinical approach. *AnnSurgOncol* 1996, 3:367-374.
6. Tan YM, Yeo A, Chia KH, Wong CY. Breast abscess as the initial presentation of squamous cell carcinoma of the breast. *Eur J SurgOncol*. 2002;1:91-93.
doi: 10.1053/ejso.2001.1156.
7. Toikkanen S: Primary squamous cell carcinoma of the breast. *Cancer* 48:1629-1632, 1981
8. Gupta G, Malani AK, Weigand RT, Rangenini G: Pure primary squamous cell carcinoma of the breast: A rare presentation and clinicopathologic comparison with usual ductal carcinoma of the breast. *Pathol Res Pract* 2006, 6:465-469.
9. Korbliing M, Estrov Z: Adult stem cells for tissue repair: A new therapeutic concept? *N Engl J Med* 349:570-582, 2003
10. Aparicio I, Martinez A, Hernandez G, Hardisson D, De Santiago J: Squamous cell carcinoma of the breast. *Eur J Obstet Gynecol* 2008, 137:222-226.