

CANCER IN YOUNG AGE WITH BRAIN METASTASIS: A CASE SERIES**Deepti Sharma¹, Garima Singh¹, Neha Kakkar¹, Vidya Jha²****Abstract**

Lung cancer is the most common cause of mortality worldwide, accounting for 28% of all cancer. Predominately it occurs in the age group of 50-80 years. Different studies had shown that young patients are very likely to present with advanced disease. Here, we are presenting case series of four patients with brain metastases secondary to bronchogenic carcinoma. All four cases received palliative radiotherapy to the brain 30 Gy in 10 fractions and were benefitted after palliative radiotherapy. 2 out of 4 patients were palliated well on chemotherapy and rest were lost to follow up. In this case series we have demonstrated that change in the trend of the disease in terms of age of onset, presentation and prognosis.

Author Affiliations:

¹ Department of Radiation Oncology, VMMC & Safdarjung Hospital, New Delhi -110029

² Department of Pathology, VMMC & Safdarjung Hospital, New Delhi -110029

Keywords: Carcinoma lung, Young age, Brain Metastasis, Poor prognosis***Corresponding Author:****Dr. Garima Singh MD**

Assistant Professor, Department of Radiation Oncology, VMMC and Safdarjung Hospital

New Delhi 110029. **Email id-** singh.garima3025@gmail.com **Mob:** +91-9953480093

INTRODUCTION

Lung cancer is the most common cause of mortality worldwide; the peak age for Non Small Cell Lung Cancer (NSCLC) is 50 years to 60 years.^[1] Incidence of adenocarcinoma in young patients has increased.^[2] Data from different studies had shown that young patients are very likely to present with

advanced disease.^[3-5] The incidence of brain metastasis from lung cancer at initial diagnosis ranges from 10–18%^[6-8], but Lung cancer with brain metastasis is rare in individuals less than 30 years age.^[9] Hereby we are presenting a case series of NSCLC with brain metastasis in a group of less than 30 years old. (Table 1)

Case no	Metastatic site	Presenting symptoms	Age	Sex	Histopathology	Status
1	Brain	Vomiting, dizziness, diminision of vision	26	F	Adenocarcinoma	On palliative chemotherapy
2	Brain	Headache and vomiting	24	M	Poorly diff adenocarcinoma	Expired
3	Brain	Seizure	28	M	Adenocarcinoma	Expired
4	Brain, Bone and adrenals	Right left sided limb pain and weakness	29	M	Moderately differentiated adenocarcinoma	On chemotherapy

Table 1-Clinopathological Feature of Lung cases with Brain Metastasis

CASE PRESENTATION

Case I

A 26 year old female presented with history of vomiting, headache and dizziness for 8

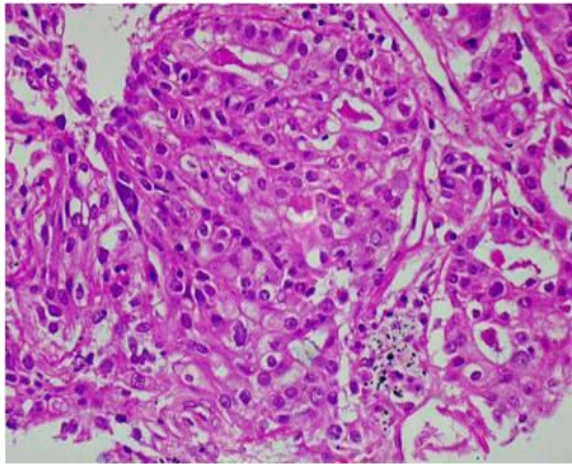


Figure1: Histopathology of Adenocarcinoma lung

CECT suggested of multiple heterogeneously enhancing hypodense lesions of various sizes showing peripheral rim enhancement seen involving left high parietal, right occipital left caudate lobe and left cerebellar hemisphere with perilesional edema. CECT thorax showed irregular speculated heterogenous enhancing mass lesion with complete left main bronchus cut off associated with obstructive collapse of left lower lobe with multiple nodules with feeding vessel in entire right lung field. Patient had received palliative radiotherapy to brain and is now on palliative chemotherapy.

months, dry cough and haemoptysis for 6 months and blurring of vision for 1 month. Bronchoscopic biopsy suggestive of adenocarcinoma with lepidic pattern and positive for TTF-1 and negative for P63.

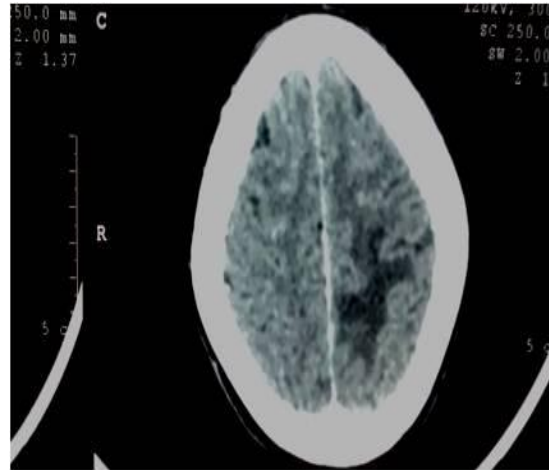


Figure 2a: CECT head showing hypodense lesions in parietal region suggestive of metastasis

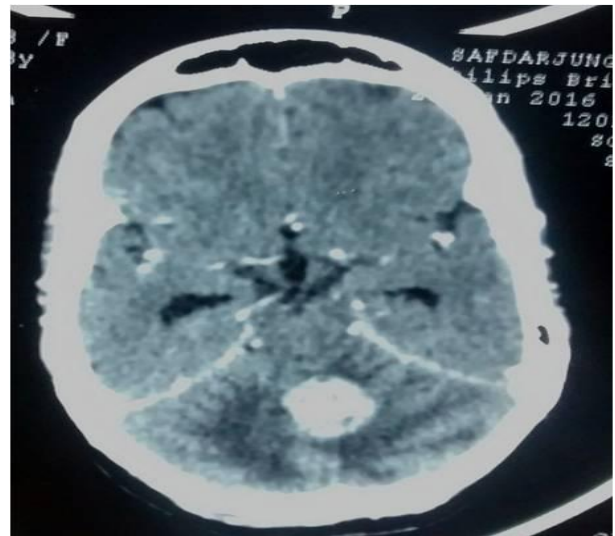


Figure 2b: CECT head showing hypodense lesions in cerebellar and occipital region suggestive of metastasis

Case II

A 24 year old male presented with history of head ache and vomiting for 3 months and chest pain right side radiating to right arm for 2 months, was diagnosed with bronchogenic carcinoma with brain metastasis in Jan 2010. Endobronchial biopsy was suggestive of poorly differentiated adenocarcinoma. MRI brain showed two moderate sized intra-axial lesions in right temporo-frontal and left frontal lobe with surrounding edema and mass effect. CXR showed single nodular opacity noted in left upper lobe of lung. On this basis, a complete metastatic workup was done, which showed no evidence of disease elsewhere.

Patient received palliative radiation therapy to brain and was planned for palliative chemotherapy with paclitaxel and carboplatin but he defaulted and reported after 4 months with breathing difficulty. In spite of the best supportive care, patient expired in April 2010 because of the disease progression.

Case III

A 28 year old male presented with history of seizure in Jan 2011. CECT brain showed ill defined hypodensity lesion in bilateral cerebral hemisphere. CECT chest showed large hypodense mass in apical segment right

lower lobe and posterior segment of right upper lobe. Extra pleural extension of mass seen along with involvement of right paraspinal muscle with destruction of overlying ribs with multiple nodular opacities in bilateral upper lobe.

Patient received palliative radiation therapy to brain and 4 cycles of palliative chemotherapy and then lost to follow up.

Case IV

A 29 year old male presented with right sided limb pain and weakness. MRI brain suggestive of ill defined lesion in the right cerebellar hemisphere with perilesional edema and compression of the fourth ventricle, middle cerebellar peduncle and pons and intense in homogenous post contrast enhancement with broad base towards the dura with increased signal intensity on T1W possibility of neoplastic lesion. Histopathology was suggestive of moderately differentiated adenocarcinoma. PET-CECT scan revealed hypermetabolic left pulmonary lower lobe parenchymal mass lesion, left perihilar lymph nodes, right cerebellar space occupying lesion, right adrenal nodule and skeletal lesion. Patient has received palliative radiotherapy to brain and to the right hemipelvis and is now on palliative chemotherapy.

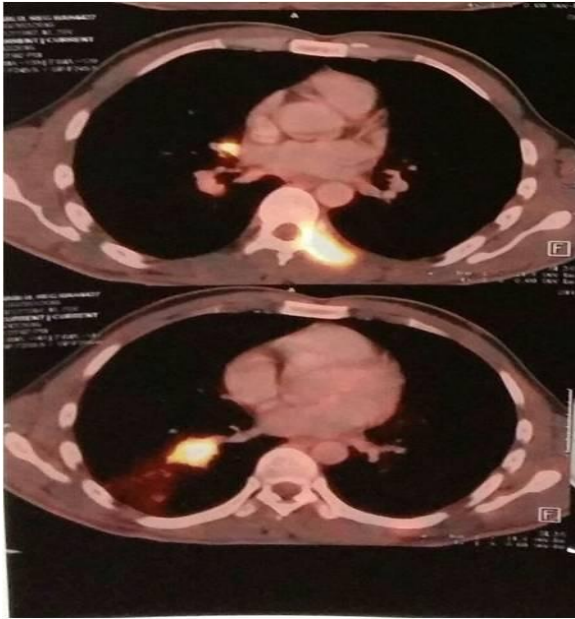


Figure 3: PET-CECT scan showing hypermetabolic left pulmonary lower lobe, skeletal lesion

DISCUSSION:

Case I and II patient presented with vomiting due to raised Intracranial tension (ICT), which was relieved with after corticosteroid therapy. Patient in case III had presented with seizure and that in case IV with hemiparesis.

Lung cancer is the most common cause of mortality worldwide, accounting for 28% of all cancer in the age group of 50-80 years.^[10-11] NSCLC represents 80% of all lung cancer.^[12] Emori *et al.* demonstrated that 0.1 to 0.4 % of all lung cancer occurs at age below 30 years.^[13] Gadgeel *et al* depicted

that only 0.8% of lung cancer was less than 30 years of age.^[14] Few studies have also suggested that incidence of adenocarcinoma of lung below 30 years of age is also very low.^{[4],[15]} Neide C *et al*, demonstrated that out of 9 patients (less than 40 years of age), Five patients had small-cell histology (extensive stage), and 6 patient presented with brain metastasis. Conclusion was made after treatment with palliative radiotherapy and palliative chemotherapy that very young patients with brain metastases did not achieve a better outcome than intermediate age groups.^[16]

In another retrospective analysis, 17 patients were identified with age range between 19 and 35 years, median age was 30 years, 14 (82%) patients had stage IV disease and 47% of patients presented with metastasis to brain.^[17]

To our knowledge only 2 retrospective studies have been done in the past which focused on bronchogenic carcinoma with brain metastasis in young patients. The interpretation of the prior 2 studies along with the present case series showed that the incidence of patients of NSCLC with brain metastasis is very less and these patients tend to harbour multiple cerebral lesions, which already are found at initial cancer diagnosis.

These features might be due to the presence of an aggressive malignancy but might also result from a delay in diagnosis in a patient group where lung cancer is rather uncommon and initial symptoms might be misinterpreted. In a study by Gaspar *et al.* younger patients (≤ 50 years) have a higher risk for development of brain metastases from stage III non-small-cell lung cancer (NSCLC).^[18] Herbert SH *et al* also demonstrated that patients less than 50 years of age are at higher risk of brain metastasis.^[19] All four cases received palliative radiotherapy to the brain 30 Gy in 10 fractions. Good palliation was achieved. They were planned for palliative chemo, 2 patients deferred palliative chemotherapy and expired but 2 other patients are still on palliative chemotherapy.

CONCLUSION

Different studies had shown that young patients are very likely to present with advanced disease. In this case series we have demonstrated that change in the trend of the disease has lead to deviation from the predefined presentation of disease. Therefore, any patient presenting with neurological symptoms along with abnormal finding on chest X-ray, carcinoma

lung should be considered in the differential diagnosis.

Acknowledgement: I acknowledge the support of Department of Radiotherapy and Pathology for providing valuable information.

Conflict Of Interest Statement: There is no conflict of interest.

Funding: No

Consent: Consent taken from patient.

References

1. Younes RN, Schutz FA, Gross JL. Preoperative and pathological staging of NSCLC: retrospective analysis of 291 cases. *Rev Assoc Med Bras* 2010; 56: 237-41.
2. Menon B, Kulshrestha R, Aggarwal B *et al.* A rare case of non-small cell lung carcinoma in an 8 year old female. *Indian J Chest Dis Allied Sci* 2007;49:103-105.
3. Nugent WC, Edney MT, Hammerness PG *et al.* Non small cell lung cancer t the extremes of age: impact on diagnosis and treatment. *Ann Thorac Surg* 1997;63:193-7.
4. Mapel DW, Fei RH, Crowell RE. Adenocarcinoma of the lung presenting as a diffuse interstitial

- process in a 25 year old man. Lung Cancer 1996;15:239-44.
5. Liu NS, Spitz MR, Kemp BL et al. Adenocarcinoma of the lung in young patients: the M.D. Anderson experience. Cancer 2000;88:1837-41.
 6. Granone P, Margaritora S, D'Andrilli A, Cesario A, Kawamukai K, Meacci E. Non-small cell lung cancer with single brain metastasis: the role of surgical treatment. Eur J Cardiothorac Surg 2001; 20: 361-6.
 7. Hu C, Chang EL, Hassenbusch SJ 3rd et al. Non small cell lung cancer presenting with synchronous solitary brain metastasis. Cancer 2006; 106: 1998-2004.
 8. Chang DB, Yang PC, Luh KT, Kuo SH, Hong RL, Lee LN. Late survival of non small cell lung cancer patients with brain metastases. Influence of treatment. Chest 1992; 101: 1293-7.
 9. Singh AP, Singh S et al. Non-small cell lung carcinoma in a young adult manifesting by non-retractile vomiting. JIACM 2015;16(1):80-2.
 10. Landis SH, Murray T, Bolden S, Wingo PA. Cancer statistics, 1999. CA Cancer J Clin 1999; 49: 8-31.
 11. Kocak Z, Uzala MC, Uygun K. Rising lung cancer deaths among younger individuals: Lung carcinoma in a patient at the age of 26. Onkologie 2004; 27: 212.
 12. Kuo CW, Chen YM, Chao JY et al. Non-small cell lung cancer in very young and very old patients. Chest 2000; 117: 354-7.
 13. Emori Y, Kiura K, Yoshino T et al. Very young patient with peculiar squamous cell carcinoma of the lung. Intern Med 1999; 38: 979-83.
 14. Gadgeel SM, Ramalingam S, Cummings G et al. Lung cancer in patients less than 50 years of age: the experience of an academic multidisciplinary program. Chest 1999; 115: 1232-6.
 15. Adachi Y, Araki K, Metsugi H, Tokushima T. Adenocarcinoma of the lung in a young adult. Kyobu Geka 2011; 64: 235-8.
 16. Niedera C, Thamm R, Astner ST, Molls M. Disease Presentation and Treatment Outcome in Very Young Patients with Brain Metastases from Lung Cancer. Onkologie 2008;31:305-308.
 17. Ozen M, Aksoy S et al. Lung Cancer in Young Patients Under the Age of

- Thirty-five: Single Center Experience. *Acta Oncol Tur* 2012;45(1):1-4.
18. Gaspar LE, Chansky K, Albain KS, Vallieres E, Rusch V, Crowley JJ, Livingston RB, Gandara DR: Time from treatment to subsequent diagnosis of brain metastases in stage III non-small-cell lung cancer: a retrospective review by the Southwest Oncology Group. *J Clin Oncol* 2005;23:2955–2961.
19. Herbert SH, Curran WJ, Rosenthal SA, Stafford PM, McKenna WG, Hughes EN, Sandler HM: Adverse influence of younger age on outcome in patients with non-small cell lung carcinoma (NSCLC) treated with radiation therapy (RT) alone. *Int J Radiat Oncol Biol Phys* 1992;24:37–42.