

**A CLINICO-RADIOGRAPHIC EVALUATION OF WOUND HEALING AND BONE  
FORMATION AFTER SURGICAL REMOVAL OF IMPACTED THIRD MOLARS  
USING PLATELET RICH FIBRIN (PRF) AND PRF IMPREGNATED WITH  
2% METRONIDAZOLE**

**R. Dilip Kumar, Shashant Kumar Gupta, HP. Raghuv eer, Shobha ES, Prashanth NT,  
VinodRangan, Archana G. Panicker**

**Abstract**

**Aim and objective:** The aim of the study was to compare the efficacy of Platelet Rich Fibrin with or without 2% Metronidazole in mandibular third molar surgery by assessing the postoperative pain, swelling, wound healing (by wound infection and dehiscence ) comparing the quantity of bone healing at various time intervals

**Materials and Methods:** Twenty patients aged 20-40 years who visited the Department of Oral and Maxillofacial Surgery, DayanandaSagar College of Dental Sciences were randomly selected and divided into a Control group and a Study group of ten patients each. Clinical assessment was done for both groups for wound dehiscence, wound infection, swelling (by using a modification of the Scultz-Mosgau method) and pain (by Visual Analog Scale) after 3<sup>rd</sup> post-operative day, 7<sup>th</sup> post-operative day and 14<sup>th</sup> post-operative day. The radiographic assessment of mean bone height was done by using Orthopantomograph and evaluated preoperatively, immediate post-operatively and 3rd month post-operatively.

**Results:** The VAS score of Study group ( $6.1 \pm 0.9$ ) was lesser than the Control group ( $6.8 \pm 1.03$ ) but the result was not statistically significant (p value was 0.14) on the 3<sup>rd</sup> post-operative day. Swelling on 3rd post-operative day ( $3.48 \pm 0.5$ ), 7th post-operative day ( $1.90 \pm 0.5$ ) and 14th post-operative day ( $0.50 \pm 0.5$ ) on the study group were consistently lesser than the control group on 3rd post-operative day ( $4.71 \pm 1.2$ ), 7<sup>th</sup> post-operative day ( $2.54 \pm 1.2$ ) and 14th post-operatively day ( $0.81 \pm 1.2$ ) but statistical significance value was found to be only on 3rd day (p value was 0.008).

The mean bone height post-operatively after 3rd month in study group was higher than the control group and the result was statistically significant (p value was < 0.001).

**Conclusion:** The Platelet Rich Fibrin with 2% Metronidazole group recorded reduced pain, swelling as well as enhanced and faster bone healing compared with those in the control group.

**Author Affiliations:**

Department of Oral and Maxillofacial Surgery, Dayananda Sagar College of Dental Sciences, Bangalore, Karnataka

**Keywords:** Wound healing, Third molar surgery, Platelet Rich Fibrin, 2% Metronidazole

**\*Corresponding Author:**

**Dr. R. Dilip Kumar**, Professor, Department of Oral and Maxillofacial Surgery, Dayananda Sagar College of Dental Sciences, Bangalore, Karnataka.

**INTRODUCTION**

Removal of the lower third molars is one of the most common procedures in oral and maxillofacial surgery and it is often attended by complications which are distressing to patients<sup>[1]</sup>. The incidence of infectious and inflammatory post-operative sequelae following an impacted mandibular third molar surgery varies between 0% and 45%, according to different published literature<sup>[2,3]</sup>. Healing of extraction socket is a coordinated sequence of biochemical, physiologic, cellular, and molecular responses involving various cell types, growth factors, hormones,

cytokines, and other proteins, which is intended to restore the tissue integrity and functional capacity after injury<sup>[4]</sup>.

Various methods have been suggested to enhance socket healing and reduce the postoperative wound healing complications after third molar surgery. Developments of bioactive surgical additives are one of the most promising clinical researches which have been used to regulate inflammation and increase the speed of the healing process. It is known that platelet plays a crucial role not only in the hemostasis, but also in the process

of wound healing. Autogenous Platelet Rich Growth Factors (PRGF) are successfully used in stimulating bone regeneration and promotes healing after the surgical removal of third molar tooth<sup>[5-11]</sup>.

The various in vivo and in vitro studies of the release of growth factors from Platelet Rich Fibrin has shown that PRF yields better results over PRP and thus helped in optimising its clinical application. It has been proved that there is a slower release of growth factors and better healing properties with PRF than compared to PRP. It has been observed and shown that the cells are able to migrate from fibrin scaffold; while some authors demonstrated the PRF as a supportive matrix for bone morphogenetic protein as well<sup>[12]</sup>.

Metronidazole has shown the greatest promise in randomized double-blind studies in third molar surgery. It has a narrower spectrum and targets primarily anaerobes, therefore reducing the chance of bacterial resistance as well as being associated with fewer side effects than other antibiotics<sup>[13, 14]</sup>. However, there is dearth of literature regarding the use of biological dressing impregnated with antibiotics in the mandibular third molar surgery. Hence, we definitely believe that there is a need for study to compare the role of PRF along with Metronidazole for enhanced

wound healing as well as post-extraction complications and bone regeneration after mandibular third molar surgery.

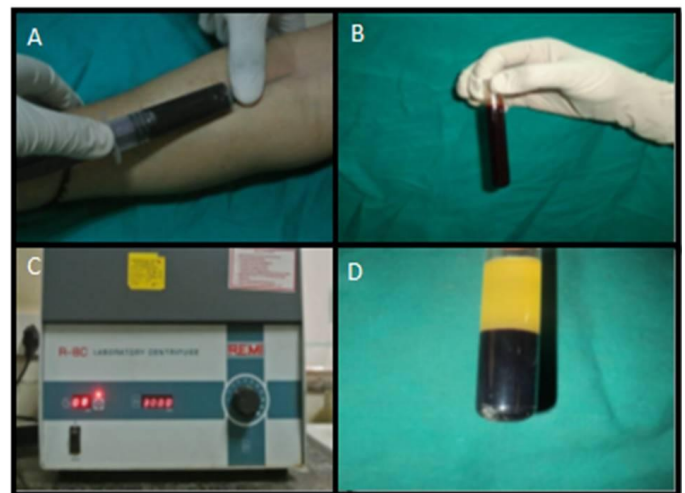
## MATERIALS AND METHODS

The study was done on twenty outpatients of the age group of 20-40 years who visited the Department of Oral & Maxillofacial Surgery, DayanandaSagar College of Dental Sciences, Bangalore, for surgical removal of impacted mandibular third molars.. They were divided into two equal groups at random, i.e. Control group, in which Platelet Rich Fibrin was placed into the extraction socket and a Study group, in which Platelet Rich Fibrin with 2% Metronidazole was placed in the extraction socket. A custom made case sheet was designed for the study to record the case history of the patients pre-operatively. All patients were operated by a single operator and all types of impacted teeth were selected for the study. Prior to surgery, patients were examined for fitness to undergo the surgery by a thorough case history, clinical examination and routine investigations. Medically compromised patients and cases where the surgical site was associated with active infection or local pathology of hard and soft tissue were excluded from the study.

Clinical Assessment was performed pre-operatively and at the 3<sup>rd</sup>, 7<sup>th</sup> and 14<sup>th</sup> day postoperatively for wound healing with respect to pain, swelling, wound infection, wound dehiscence and bone height. Pain was evaluated using a 10 point Visual Analog Scale. Swelling was calculated by using a modification of the method of Scultz-Mosgau et al and this required measuring the distances from the Tragus to the soft tissue Pogonion and corner of the mouth to the Tragus. The arithmetic sum of the two measurements was used to determine the facial swelling. The percentage of facial swelling was calculated from the difference of the measurements made in the preoperative and postoperative i.e.  $(\text{Swelling Postoperatively} - \text{Swelling Preoperatively}) / \text{Swelling Preoperatively} \times 100$ . The criteria used to assess wound infection were presence of suppuration, increase in pain, erythema, local warmth, swelling and purulent discharge at the operated site. Wound Dehiscence (if present) was clinically evaluated on 3<sup>rd</sup>, 7<sup>th</sup> and 14<sup>th</sup> day post-operatively. For radiological assessment, pre-operative, immediate post-operative and 12<sup>th</sup> week postoperative OPG was taken and measurements were done to evaluate the quantity of bone using listed standard landmarks on the radiograph. Bone height from the distal cement-enamel junction

of second molar to a point on the superior border of inferior alveolar canal, was measured by the digital Vernier Caliper in a straight line.

After taking all the aseptic precautions, 10ml of intravenous blood was drawn from the antecubital region through 10 ml sterile syringe which will be transferred to centrifugal test tubes. The blood was centrifuged using a tabletop centrifuge for 10 minutes at 3000 rpm and Platelet Rich Fibrin is obtained in the middle layer. (Fig.1)



**Fig 1: Preparation of Platelet Rich Fibrin,**

A: Withdrawal of 10 ml blood for preparation of PRF,

B: Blood taken in the test tube,

C: Preparation of PRF for 10 minutes at 3000rpm,

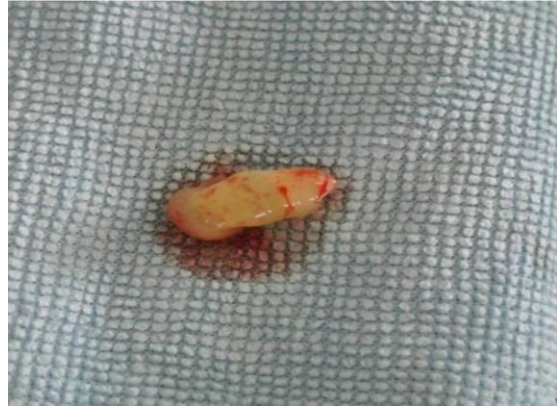D: Platelet Rich Fibrin matrix present in the middle layer

Under sterile aseptic conditions, 2 grams of Metronidazole powder was dissolved in 100ml of distilled water to get the prepared solution of 2% Metronidazole. Platelet Rich Fibrin was added to the prepared 2% metronidazole solution before the surgical procedure, kept in petridish till the surgical procedure was completed and then placed in extracted third molar socket. (Fig.2 and Fig.3) The surgical procedure was standardized in all cases. PRF (in case of Control group) or PRF with 2% Metronidazole (in case of Study group) was placed into the socket with the help of Adson's non toothed forceps. Sutures were placed with round body needle 3-0 black silk. All the patients were instructed to take anti-inflammatory analgesic medication.

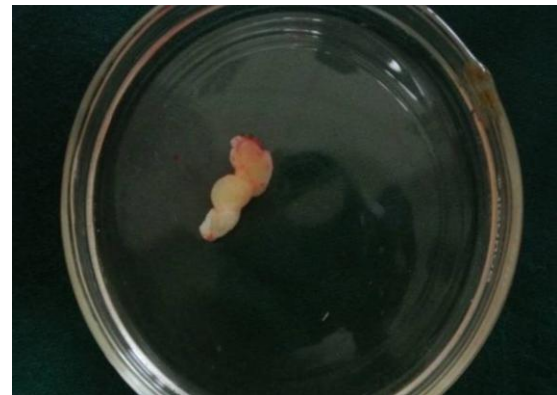### Statistical Analysis

Student t test (two tailed, independent) has been used to find the significance of study parameters on continuous scale between two groups, inter group analysis on metric parameters. P value:  $0.01 < P \leq 0.05$  showed

moderate significance and P value  $\leq 0.01$  was considered strongly significant.



**Fig.2: PRF matrix without 2% metronidazole solution**



**Fig.3: PRF matrix placed in 2% Metronidazole solution**

### RESULTS

The mean age of the patients in the Control group was  $28.50 \pm 3.8$  years and the study group was  $28.90 \pm 2.2$  years. The control group consisted of 8 male and 2 female

patients and study group consisted of 5 male and female patients each. (Table 1) The VAS score of Study group ( $6.1 \pm 0.9$ ) was lesser than the Control group ( $6.8 \pm 1.03$ ) but the result was not statistically significant (p value was 0.14) on the 3<sup>rd</sup> post-operative day. At the 7<sup>th</sup> day post-operatively the mean pain score was similar in both the groups study group was as compared to the control group was the results were not statistically significant. At the 14<sup>th</sup> day post-operatively the mean pain score was similar in both the groups and the p value was not comparable (Table 2). On the 3<sup>rd</sup>, 7<sup>th</sup> and the 14<sup>th</sup> post-operative days, the mean swelling score were lesser for the Study group as compared to the Control group (Table 3). Wound dehiscence and wound infection was absent on the 3<sup>rd</sup>, 7<sup>th</sup> and 14<sup>th</sup> post-operative day in both the groups which shows that the results was not comparable. The mean score of bone height in the study group post-

operatively 3<sup>rd</sup> month was ( $18.5 \pm 1.8$ ) and found to be higher than the control group post-operatively 3<sup>rd</sup> month ( $13.91 \pm 1.6$ ), which was highly statistically significant. (Table 4)

## DISCUSSION

In regular tooth extraction procedures, eventual contamination of the wound site by food residue and oral bacteria is a common finding as both the blood clot as well as the wound is directly exposed to the oral cavity. The primary blood clot plays a vital role in the growth of new tissue at the early stages of wound healing and the disruption/ loss of this primary clot often results in reduced rate of growth in the mucous epithelium into the extraction socket owing to the lack of support from the blood clot that markedly retards the process of healing, further causing an infection from contamination that results in discomfort and pain <sup>[15]</sup>.

**Table 1: Distribution of participants according to gender**

Gender	Participants		Total n (%)
	Control n (%)	Study n (%)	
Male	8 (61.5)	5 (38.5)	13 (100)
Female	2 (28.6)	5 (71.4)	7 (100)
Total	10 (50)	10 (50)	20 (100)

**Table 2: Mean (SD) pain scores on VAS (n = 10 in each group)**

Post-operative day	Study PRF with 2% Metronidazole)	Control (PRF)	P value
3	6.1 (0.9)	6.8 (1.03)	0.14
7	1.4 (0.5)	1.4 (0.5)	1.0
14	0 (0)	0 (0)	-

**Table 3: Mean (SD) swelling (n = 10 in each group)**

Post-operative day	Study PRF with 2% Metronidazole	Control (PRF)	P value
3	3.48 (0.5)	4.71 (1.2)	<b>0.008**</b>
7	1.90 (0.5)	2.54 (1.23)	0.15
14	0.50 (0.5)	0.81 (0.5)	0.17

\*\*Statistically Significant

**Table 4: Mean (SD) Bone height: - from the distal CEJ of 2nd molar to a point on superior border of inferior alveolar canal in a straight line.**

	<b>Study (PRF with 2% Metronidazole)</b>	<b>Control (PRF)</b>	<b>P value</b>
<b>Bone height pre-op</b>	15.62 (2.4)	11.89 (1.3)	<b>0.0004**</b>
<b>Bone height IMM PO</b>	15.32 (2.3)	11.89 (1.3)	<b>0.0004**</b>
<b>Bone height 3rd month PO</b>	18.5 (1.8)	13.91 (1.6)	<b>&lt;0.001**</b>

\*\*Statistically Significant

## DISCUSSION

In regular tooth extraction procedures, eventual contamination of the wound site by food residue and oral bacteria is a common finding as both the blood clot as well as the wound is directly exposed to the oral cavity. The primary blood clot plays a vital role in the growth of new tissue at the early stages of wound healing and the disruption/ loss of this primary clot often results in reduced rate of growth in the mucous epithelium into the extraction socket owing to the lack of support from the blood clot that markedly retards the

process of healing, further causing an infection from contamination that results in discomfort and pain<sup>[15]</sup>.

Several mechanisms have to be in sync with the formation of the clot and its sustenance. Within the framework of the Fibrinolytic theory of Alveolar Osteitis (Dry Socket), clot lysis and loss may be categorically viewed as multifactorial in origin. The various contributing mechanism include Plasminogen-mediated fibrinolysis caused by physiologic tissue-type plasminogen activators that get locally liberated by surgical trauma,

Non-physiologic activators elaborated by oral bacteria present in or introduced into the extraction wound, Non-Plasminogen-mediated fibrinolysis mediated by other mechanisms such as bacterial liberated substances as well as by a leukocyte-mediated fibrinolysis (either Plasminogen-mediated or independent) occurring as a result of an acute local inflammatory response to surgical trauma, manipulation or by local bacterial challenges<sup>[16]</sup>.

Having understood the probable causes of Clot failure as stated, relevant literature has addressed various topical applications of pharmacological agents that are used to stabilize the primary clot at the extraction site. The advantages of these pharmacological substances is that they allow a greater local concentration such that a stable fibrin clot develops and this is more than that normally expected from systemic administration and further minimizes the potential adverse effects and sensitization that accompanies this route of administration<sup>[17]</sup>.

The efficacy of localized (intra-alveolar) antibiotic therapy placed immediately post-operative has always been a debate. Antibiotics have been used both as a single regimen as well as multi-regimen in various formulations and dosages whilst some may be

administered via numerous carriers in an attempt to alleviate Alveolar Osteitis and its associated symptoms. Several authors suggest the use of the same in order to prevent post-operative complications. Prophylactic anti-bacterials administered pre-operative either systemically or locally include Penicillins, Tetracyclines, Clindamycin, Erythromycin, Tinidazole as well as Metronidazole. These pharmacological agents have shown better results when used pre-operatively rather than post-operatively. Of all the discussed agents, Metronidazole showed superior results in randomized double-blinded studies that showed its effectiveness in reducing the incidence of Alveolar Osteitis, especially owing to its narrow anti-bacterial spectrum that is more anaerobicidal and that it is associated with fewer and more infrequent adverse effects than those with high resistance developing secondary to administration of Penicillin and Erythromycin as well as Pseudomembranous colitis inducing Clindamycin<sup>[18,19,20]</sup>.

An important consideration about the use of Metronidazole is in the placement of the drug at the right concentration such that maximum efficacy of the drug may be obtained at the local wound site. The placement of Metronidazole dressing directly into the extraction-site/ socket is aimed primarily to

destroy anaerobic microorganisms [17, 18]. Further, the use of pre-operative antibiotics prophylactically showed marked reduction in the density of anaerobes in the oral cavity and aided in the reduction of post-operative infections. With recent advances and an in-depth understanding of wound healing, newer approaches are being developed which play a direct active role in the healing while eliminating the potential downside of non-vital materials [13,19].

A promising mode of investigation involves the use of Platelet Rich Plasma (PRP) to aid the wound healing process. Platelet rich plasma is an autologous preparation of a concentration of platelets and plasma that can be created by centrifuging the patient's own blood. Several publications have cited the advantages and the uses of platelet rich plasma as an adjunct in the peri and post-operative management following Periodontal as well as Oral Surgical applications [21].

Platelet rich Fibrin (PRF) is a second-generation platelet concentrate defined by Choukron as an autologous leukocyte and platelet-rich fibrin biomaterial [13]. Platelet rich fibrin has been used as a close alternate to the use of platelet rich plasma and represents a new modality that involves the use of a platelet gel therapeutic concept with

simplified processing without any artificial biochemical modifications.<sup>15</sup> Unlike other platelet concentrates, the technique does not necessarily require anticoagulants or bovine thrombin ; rendering it a pure preparation of centrifuged blood without the use of any additives making it a more advantageous choice [15, 16]. Platelet rich fibrin can be used in an array of clinical situations such as to improve soft tissue healing, protection of bone graft material over the surgical area, bone remodeling procedures or even as an osteo-conductive filling material that aids bone formation following a Maxillary sinus lift procedure [14].

Platelet rich fibrin has several advantages to its credit in terms of ease of preparation, less technique sensitive, lack of biochemical handling of blood and its autologous nature over otherwise traditionally prepared platelet rich plasma gels or bovine thrombin used in the preparation of platelet rich plasma gel that may lead to development of antibodies to clotting factors V, IX and Thrombin resulting in the risk of life-threatening coagulopathies [16,22].

In the present study, we have advocated the use of Platelet Rich Fibrin as a biological surgical additive that offers and aids optimum soft tissue wound healing as well as Hard

tissue regeneration, along with the incorporation of 2% Metronidazole in order to assess whether the use of this amalgamation is beneficial after third molar surgery with regard to the wound healing and bone formation. The chosen mode of radiographic investigation was with the use of an Orthopantomogram (OPG) and bone height measurements were compared and done 3 months post operatively.

Our study showed that in the Study group (Platelet rich fibrin with 2% Metronidazole), the patients showed better wound healing, decreased post-operative sequelae such as pain and fswelling while the bone height measured was higher than that of the control group (Platelet rich fibrin without 2% Metronidazole). The mean post-operative pain was considerably lower in the study group as compared with the control group at all times, however, the result was not statistically significant [ $p=0.14$ ] (Table: 2). The mean percentage of facial swelling in the study group was lower than that of the control group during the entire time period but the differences were statistically significant only on the third day [ $p$  value was 0.008](Table: 3). The mean bone-height in the study group was also found to be higher than the control group and the results were highly significant with the  $p$  value  $<0.001$ . (Table: 4).

Our findings support the use of Platelet Rich Fibrin impregnated with 2% Metronidazole and has a superior advantage clinically in the healing of extraction sockets following third molar surgery that was further confirmed radiographically. The study however, had a limitation of a small sample size and a short duration of follow-up. We acknowledge that a larger sample size with a longer period of follow-up would be essential to obtain a more statistically significant result.

## CONCLUSION

Platelet Rich Fibrin is an autologous preparation which is found to be clinically effective and economical than any other of the plethora of available regenerative materials and is more productive when used along with 2% Metronidazole solution. However, long term, multicentre randomized, controlled clinical trial will be required to know its clinical and radiographic effect over bone regeneration. Hence, it can be inferred that the use of PRF impregnated with 2% Metronidazole solution effectively proves to be beneficial in the healing during the post-operative period of tooth sockets following third molar surgery.

**REFERENCES**

1. Osunde OD, Adebola RA, Omeje UK. Management of inflammatory complications in third molar surgery: A review of the literature. *Afr Health Sci.* 2011; 11(3): 530–537.
2. Bui CH, Seldin EB, Dodson TB. Types, frequencies, and risk factors for complications after third molar extraction. *J Oral Maxillofac Surg.* 2003; 61(12):1379–89.
3. Benediktsdóttir IS, Wenzel A, Petersen JK, Hintze H. Mandibular third molar removal: Risk indicators for extended operation time, postoperative pain, and complications. *Oral Surg Oral Med Oral Pathol Oral Radiol Endod.* 2004; 97:438-46.
4. Saravanakumar B, Julius A, Sarumathi T, Aarthinisha V, Manisundar N. Therapeutic Effects and Concepts in the Use of Platelet-Rich Fibrin (PRF) on Alveolar Bone Repair-A Literature Review. *Middle-East J. Sci. Res.* 2014; 19 (5): 669-673
5. Figueiredo R, Castello'n EV, B-Ayte's L, Gay-Escoda C. Incidence and clinical features of delayed-onset infections after extraction of lower third molars. *Oral Surg Oral Med Oral Pathol Oral Radiol Endod.* 2005; 99: 265-9.
6. Del Fabbro M, Bortolin M, Taschieri S. Is autologous platelet concentrate beneficial for post-extraction socket healing? A systematic review. *Int J Oral Maxillofac. Surg.* 2011; 40: 891–900.
7. Simon BI, Gupta P, Tajbakhsh S. Quantitative evaluation of extraction socket healing following the use of autologous platelet-rich fibrin matrix in humans. *Int J Periodontics Restorative Dent.* 2011; 31(3):285-95.
8. Ogundipe O K, Ugboko V I, Owotade F J. Can Autologous Platelet-Rich Plasma Gel Enhance Healing After Surgical Extraction of Mandibular Third Molars? *J Oral Maxillofac Surg* 69:2305-2310, 2011.
9. Simon BI, Zatcoff AL, Kong JJ, O'Connell SM. Clinical and histological comparison of extraction socket healing following the use of autologous platelet-rich fibrin matrix (PRFM) to ridge preservation procedures employing demineralized freeze dried bone allograft material and membrane. *Open Dent J.* 2009; 3: 92–99.
10. Noroozi AR, Philbert RF. Modern concepts in understanding and management of the —dry socket syndrome: comprehensive review of the literature. *Oral Surg Oral Med*

- Oral Pathol Oral Radiol Endod. 2009; 107: 30-35.
- 11.** Dohan Ehrenfest DM, de Peppo GM, Doglioli P, Sammartino G. Slow release of growth factors and thrombospondin-1 in Choukroun's platelet-rich fibrin (PRF): a gold standard to achieve for all surgical platelet concentrates technologies. *Growth Factors*. 2009; 27(1):63-9.
  - 12.** Choukroun J, Diss A, Simonpieri A, Girard MO, Schoeffler C, Dohan SL, Dohan AJ, Mouhyi J, Dohan DM. Platelet-rich fibrin (PRF): a second-generation platelet concentrate. Part IV: clinical effects on tissue healing. *Oral Surg Oral Med Oral Pathol Oral Radiol Endod*. 2006; 101: E56-60.
  - 13.** Choukroun J, Adda F, Schoeffler C, Vervelle A. An opportunity in peri-implantology: The PRF (in French). *Implantodontie* 2001; 42: 55-62. .
  - 14.** Lauritano D, Avantaggiato A, Candotto V, Zollino I, Carinci F. Is platelet rich fibrin really useful in oral and maxillofacial surgery? Lights and shadows of this new technique. *Ann Oral Maxillofac Surg*. 2013; 1: 25-29.
  - 15.** Li YQ, Shann ZC. Initial study on facilitating wound healing after tooth extraction by using microbial fiber membrane-flagyl. *American association of oral and maxillofacial surgery, J Oral Maxillofac Surg* 69:994-1002, 2011
  - 16.** Lauritano D, Avantaggiato A, Candotto V, Zollino I, Carinci F. Platelet rich fibrin (PRF) is really useful in oral and maxillofacial surgery: Lights and shadows. *Ann Oral Maxillofac Surg*. 2013; 1(3): 25.
  - 17.** Lucarelli E, Beretta R, Dozza B, Tazzari PL, O'Connell SM, Ricci F, Pierini M, Squarzoni S, Pagliaro PP, Oprita EI, Donati D. A recently developed bifacial platelet-rich fibrin matrix. *Eur Cell Mater*. 2010; 20: 13-23.
  - 18.** Rood J.P, Murgatroyd J. Metronidazole in the prevention of Dry Socket. *Br J Oral Surg*. 1979; 17(1): 62-70.
  - 19.** Bergdahl M, Hedström L. Metronidazole for the prevention of dry socket after removal of partially impacted mandibular third molar: a randomised controlled trial. *Br J Oral Maxillofac Surg*. 2004; 42(6):555-558.
  - 20.** Poor M R. Reduction in the Incidence of Alveolar Osteitis in Patients Treated With the SaliCept Patch, Containing Acemannan Hydrogel. *American Association of Oral and Maxillofacial Surgeons, J Oral axillofac Surg* 60:374-379, 2002.
  - 21.** Singh J, Bharti V, Laterally positioned flap-revised technique along with platelet rich

fibrin in the management of miller class II gingival recession, *Dent Res J (Isfahan)*, 2013; 10(2): 268-273.

**22.** Srivastava A, Gupta KK, Agarwal K, Kumar N, The role of growth factors in autologous platelet concentrate for treatment of periodontal bone defect with platelet rich fibrin: a case report, *Innovative journal of medical and health science*, 2013; 3(3): 113-116.