

## SYNCHRONOUS OVARIAN AND ENDOMETRIAL CARCINOMA: A REPORT OF TWO CASES

Nisha Chauhan<sup>1\*</sup>, Murlidhar V Pai<sup>2</sup>, Jayaram Nambiar<sup>3</sup>

### **Abstract**

We report 2 cases of synchronous ovarian and endometrial tumour presented to us with irregular bleeding per vagina.

Case 1: 51 year old, nulliparous lady came with irregular vaginal bleeding with mass per abdomen. Ultrasonogram of pelvis showed bulky heterogeneous uterus with solid and cystic lesions in both adnexa. CA125 was 293 IU/ml. Patient underwent staging laparotomy with radical hysterectomy. Histopathology confirmed simultaneous independent endometrial adenocarcinoma with bilateral ovarian clear cell carcinoma with omental metastasis.

Case 2: 46 year old lady with complaints of irregular bleeding per vagina. CA125 was 2859 IU/ml. Computed tomogram of abdomen showed large pelvic lesion with solid and cystic components suggestive of ovarian neoplasm. Patient underwent staging laparotomy with radical hysterectomy. Histopathology revealed endometrioid adenocarcinoma with focal squamous differentiation in uterus and moderately differentiated endometrioid adenocarcinoma of ovary. She received external beam radiotherapy along with carboplatin and paclitaxel based chemotherapy.

Co-existence of primary ovarian and endometrial malignancy though uncommon may present with abnormal uterine bleeding in perimenopausal age group. Hence these women should be evaluated for synchronous tumours for optimal adjuvant treatment and better prognosis.

**Author Affiliations:** <sup>1-3</sup> Dept of Obstetrics & Gynaecology, Kasturba Medical College, Manipal, Karnataka, India – 576104.

**Keywords:** synchronous tumour, ovarian cancer, endometrial cancer, staging laparotomy, chemotherapy

**\*Corresponding Author:** Dr Nisha Chauhan MBBS MS (OBG), Assistant Professor, Dept of OBG, KMC Manipal, Karnataka, India 576104, Mobile:9972032366, Email: drnishaminocha@gmail.com.

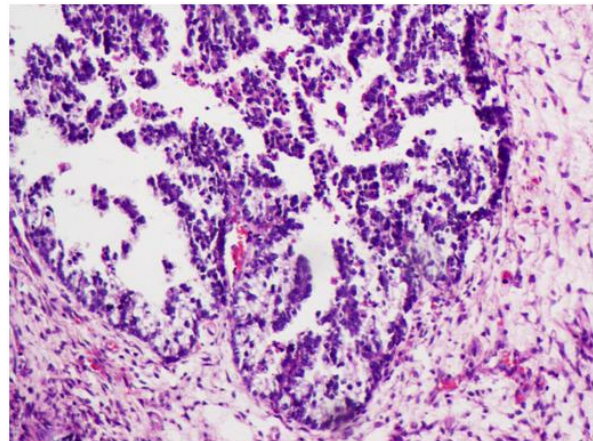
## INTRODUCTION

Synchronous ovarian and endometrial carcinomas are uncommon. Though the term synchronous means simultaneous occurrence of primary malignancies in both ovary and uterus with different histology, lesions with similar histology if occurring *denovo* can also be considered as synchronous tumour<sup>[1]</sup>. The incidence of synchronous primary endometrial and ovarian cancers is 3.3% in patients with endometrial cancer and 2.7% in patients with ovarian cancer<sup>[2]</sup>. We report two cases of synchronous ovarian and endometrial tumour in perimenopausal women who presented to us with irregular bleeding per vagina.

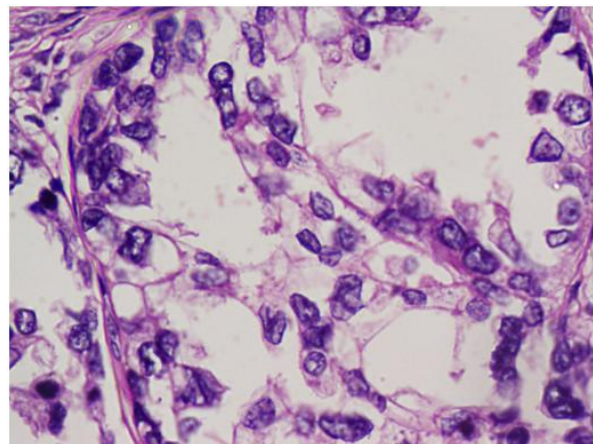
### CASE PRESENTATION:

**Case 1:** 51 year old nulliparous lady presented with irregular bleeding per vagina following one year of amenorrhea. Abdominal examination revealed 20x15cms mass, firm too hard in consistency with restricted mobility. Ultrasonogram of pelvis showed bulky heterogeneous uterus with lesions in both adnexa with solid and cystic components. Ovaries were not separately visualized from the lesion.

CA 125 was 293 IU/ml. FNAC from the mass was suggestive of serous cystadenocarcinoma of ovary and endometrial sampling revealed endometrioid adenocarcinoma. Patient underwent exploratory laparotomy with total abdominal hysterectomy with bilateral salpingoophorectomy with omentectomy. Histopathology confirmed simultaneous independent endometrial endometrioid adenocarcinoma (FIGO 1B) with bilateral ovarian clear cell carcinoma (figure 1 & 2) with omental metastasis (FIGO Stage 3c).



**Figure 1:** Clear cell carcinoma of the ovary showing papillary pattern.



**Figure 2:** High power view of papillary areas from clear cell carcinoma of the ovary. This clear cell carcinoma shows prominent hobnail cells.

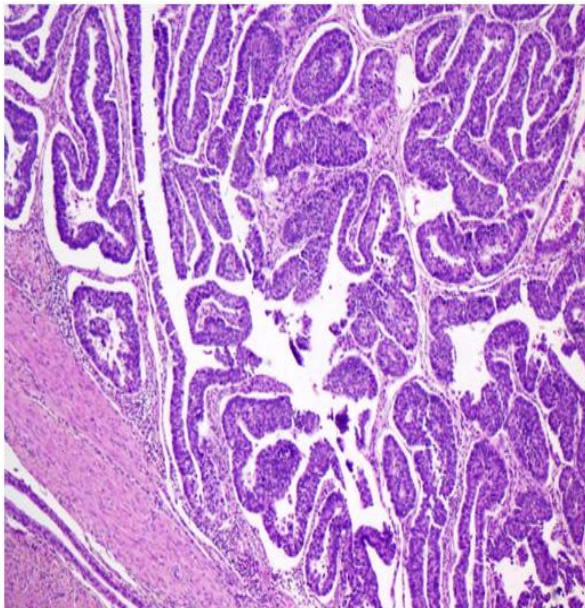
Post operatively the patient was advised six cycles of adjuvant chemotherapy but the patient refused for the same.

She reported back to us after one year with spotting per vagina. Examination revealed a growth in the vault and biopsy confirmed the recurrent endometrioid adenocarcinoma.

**Case 2:** 46 year old perimenopausal lady with complaints of irregular bleeding per vagina since one year. She also gave history of post meal distension and early satiety. On examination there was a mass per

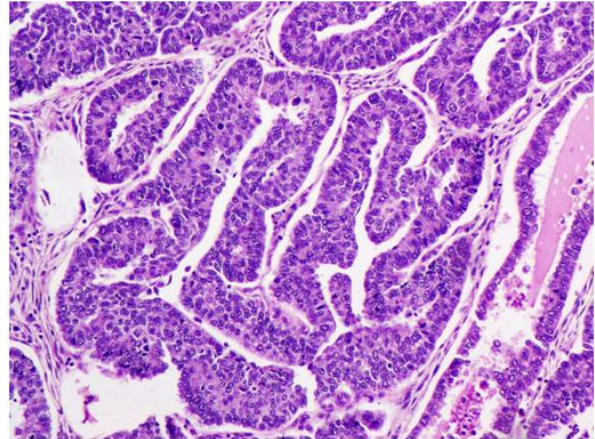
abdomen of 20 x10 cms size, firm to hard in consistency.

CA125 was 2859 IU/ml. Computed tomogram of abdomen showed large pelvic lesion with solid and cystic components suggestive of ovarian neoplasm. Patient underwent exploratory laparotomy with total abdominal hysterectomy with bilateral salphingo-oophorectomy with omentectomy. Histopathology revealed endometrioid adenocarcinoma with focal squamous differentiation (G2) with involvement of cervix and infiltration of less than half of myometrium, adnexae and omentum free of tumor (FIG 1). Bilateral ovaries showed endometrioid adenocarcinoma (Figure 3 & 4) moderately differentiated type (FIG 2).



**Figure 3:** Endometrioid carcinoma of ovary.

She received radiotherapy and six cycles of carboplatin and paclitaxel chemotherapy.



**Figure 4:** Endometrioid carcinoma (high power view). Nuclei are stratified. Cytologic atypia and mitotic figures are readily evident.

#### DISCUSSION:

Co-existence of primary ovarian and endometrial malignancy, though uncommon may present in perimenopausal women. Although rare these synchronous tumours may present with abnormal uterine bleeding in perimenopausal age group. Patient with synchronous tumour are younger than those suffering from endometrial and ovarian cancer alone <sup>[3]</sup>. Both of our patients were also in perimenopausal age group presented with abnormal uterine bleeding. Abnormal uterine bleeding is the commonest symptom in synchronous tumour <sup>[4]</sup>. Both patients presented with bleeding per vagina, a symptom of endometrial carcinoma leading to early intervention and diagnosis of coexisting ovarian malignancy. In contrast, ovarian malignancies usually present at advanced stage with vague symptoms of pain abdomen or bloating sensation. Case 1 was a nulliparous lady and hence had an increased risk of endometrial and ovarian carcinoma. Similarly synchronous endometrioid tumours were found more in nulliparous (92.9% versus 34.7%) in a study by Oranratanaphan

etal<sup>[4]</sup>. Though young patients with primary tumour at multiple sites may have genetic predisposition, genetic evaluation should be limited to women with prior or family history of

(Hereditary Nonpolyposis colorectal carcinoma) HNPCC related cancer<sup>[5]</sup>. However, none of our patient had such history. Diagnosis of synchronous tumour and distinguishing it from disseminating tumour poses great challenge for both clinician and pathologist. Pathological criteria by Ulbright and Roth has been proposed for diagnosis of synchronous tumour<sup>[6]</sup>. Still there are no consensus about most accurate diagnosis. The actual pathogenesis of synchronous endometrial and ovarian cancer is largely unclear<sup>[7]</sup>. Various theories including the theory of “secondary Mullerian system” proposed that the epithelia of cervix, uterus, fallopian tubes, ovaries, and peritoneal surface had shared molecular receptors which respond to carcinogenic stimulus, thus leading to the development of multiple primary malignancies synchronously<sup>[7]</sup>. This theory could provide an explanation to synchronous malignancies of similar histology. Synchronous endometrial and ovarian endometrioid adenocarcinomas are most common histological subtypes with better survival potential and favourable prognosis<sup>[8]</sup>. Endometrioid histology and low grade of tumour was seen in Case 2, in contrast to non endometrioid histology and advanced stage in Case 1. The stage of ovarian cancer and grade of endometrial cancer are important prognostic factors. Mainstay in the management for synchronous tumours is surgical staging<sup>[9]</sup>.

#### CONCLUSION:

Patients with synchronous tumour are young and perimenopausal with nulliparity as one of the risk factor. Abnormal uterine bleeding is the most common symptom. Clinicopathological evaluation helps in early diagnosis and favorable outcome. Grades and stages of the tumor are important prognostic variables. Non-endometrioid adenocarcinoma in ovary or uterus had worse prognosis than concordant endometrioid adenocarcinoma. Advance stage tumour requires postoperative adjuvant chemotherapy and/ or radiotherapy.

#### REFERENCES

1. Barakat RR, Grigsby PW, Sabbatini P, Zaino RJ. Corpus: epithelial tumors. In: Hoskins W, Perez C, Young R, eds. Principles and practice of gynecologic oncology. 3rd ed Philadelphia: Lippincott Williams & Wilkins; 2000.p.919–60.
2. Chiang Y-C, Chen C-A, Huang C-Y, Hsieh C-Y, Cheng W-F. Synchronous primary cancers of the endometrium and ovary. *Int J Gynecol Cancer* 2008;18(1):159–164.
3. Soliman PT, Slomovitz BM, Broaddus RR et al. Synchronous primary cancers of the endometrium and ovary: a single institution review of 84 cases. *Gynecol Oncol* 2004; 94(2):456–62.
4. Shina Oranratanaphan, Tarinee Manchana, Nakarin Sirisabya. Clinicopathologic Variables and Survival Comparison of Patients with Synchronous Endometrial and Ovarian Cancers versus Primary Endometrial Cancer with Ovarian Metastasis. *Asian Pacific J Cancer Prev* 2008;9: 403-408.
5. Pamela T. Soliman, Russell R. Broaddus, Kathleen M. Schmeler, Molly S.

- Daniels, Delia Gonzalez, Brian M. Slomovitz, David M. Gershenson, and Karen H. Lu. Women with Synchronous Primary Cancers of the Endometrium and Ovary: Do They Have Lynch Syndrome *Journal of Clinical Oncology*.2005;23(36):9344-9350.
6. Ulbright TM, Roth LM. Metastatic and independent cancers of the endometrium and ovary: a clinicopathologic study of 34 cases. *HumPathol* 1985;16(1):28–34.
  7. Woodruff JD ,SolomonD , Sullivant H. Multifocal disease in upper genital canal. *Obstet Gynecology*.1985; 65:695-698.
  8. Liu Y, Li J, Jin H, Lu Y, Lu X Clinicopathological characteristics of patients with synchronous primary endometrial and ovarian cancers: A review of 43 cases. *Oncol Lett* 2013; 5(1): 267-270.
  9. Georgios Androustopoulos, Georgios Decavalas. Synchronous Primary Endometrial and Ovarian Cancers: Pathogenesis, Treatment and Prognosis. *International Journal of Clinical Therapeutics and Diagnosis* 2014; 2:601.