

**RETRIEVAL OF DISPLACED DENTURE: NEED FOR INTRA-OPERATIVE SELF
TAILORING TECHNIQUES**

Roohie Singh¹, Jeevan R Galagali², Satish Kumar Bamil³

Abstract

Displaced dentures can be difficult to diagnose and hence delays treatment. Their sharp edges and hooked wires make their removal challenging. They have to be removed soon so as to avoid complications. Here, we report two cases of displaced denture which were successfully retrieved. Also, a good communication between anaesthesiologist and surgeon ensures better control over airway.

Author Affiliations: ¹Military hospital, Jodhpur, India, ²Command Hospital, Pune, India, ³Armed Forces Medical College, Pune, India.

Keywords: airway, denture, esophagus, supraglottis, tracheostomy.

***Corresponding Author:** Dr. Roohie Singh, Military hospital, Jodhpur, India, PIN-342010, roohiesingh@yahoo.in

INTRODUCTION

Apart from contributing to facial aesthetics, teeth help in relishing food and improving speech clarity. Increasing cosmetic awareness among the people has led to an increase in the number of people wearing dentures and thus, a proportionate increase in incidence of displaced dentures. Dentures account for 11.5% of impacted foreign bodies. [1]

The clinical scenario of the swallowed or inhaled denture has been well documented [2]. With any inhaled or ingested foreign body, there is potential for loss of control on airway. We describe two cases of successful removal of displaced dentures. Aim is to stress the need for implementing self tailored techniques intraoperatively; depending on the shape, configuration and lodged position of the denture. Also, the anaesthesiologist should be vigilant enough to ensure good airway control.

CASE SUMMARY:

Case 1:

A 37 yrs old male presented with history of ingestion of upper denture two hrs back while doing gargles in the morning. There was no respiratory distress and voice change. Plain X rays were inconclusive probably because of non radio-opaque acrylic dentures and unprepared abdomen. Computed Tomography(CT) scan neck with chest revealed a foreign body of size approximately 4 cm by 1 cm in mid esophagus (at level of fourth thoracic vertebra) (Fig 1). The patient was planned for foreign body (Denture) removal by rigid esophagoscopy under general anaesthesia

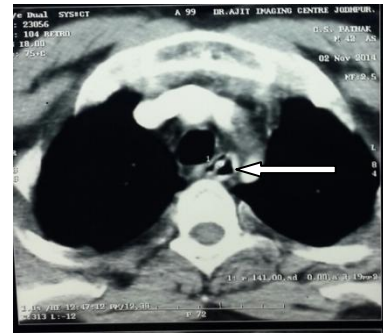


Figure 1: CT scan showing Denture (arrow) in mid esophagus (T4 vertebra level).

Intraoperatively, the denture was lying at mid esophagus coronally (24 cm from upper incisors) and the transmitted pulsations of aorta was noticed on posterior aspect of the denture further compromising the forceps space. The sharp serrated edges were facing the direction of required drag. We wisely stuffed adrenaline soaked cotton patties around the impacted denture to improve our forceps space and thus were able to release and successfully remove it. It was found to be of size 3.5 cm x 2.5 cm x 1.5 cm (Fig 2).

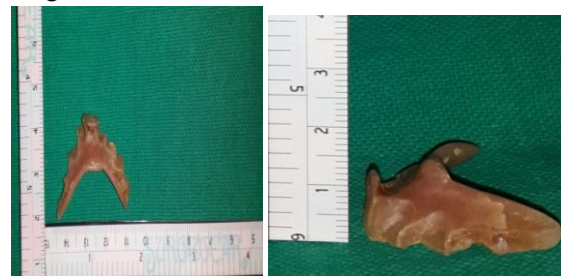


Figure 2: Retrieved denture from mid esophagus (size 3.5cm X 2.5 cm x 1.5 cm).

Any bleeding due to mucosal injury or perforation was ruled out on second look. The patient was started on antibiotics and anti-reflux treatment. After 24 hrs, patient was started on normal diet. He was discharged on the 3rd post-operative day after being advised to go for fixed denture.

Case 2:

A 55 yrs old male presented with history of displaced upper denture 12 hrs back while having his meal. He had a typical hot-potato speech. He spoke sentences with short pauses to take breath in between which suggested partial airway compromise. X ray neck revealed a displaced denture with wires, lodged in supraglottis (Fig 3).

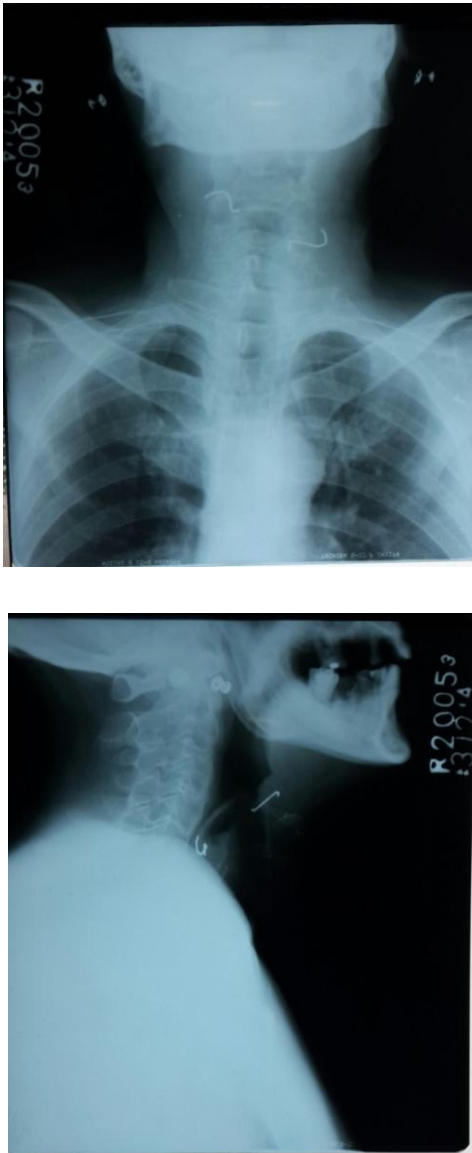


Figure 3: X ray neck showing impacted Denture wires in supraglottis.

Under controlled conditions, fiber-optic laryngoscopy was done which revealed denture lying in supraglottis in coronal plane compromising the airway partially. The surgeon – anaesthesiologist team decided to go for removal of the denture under topical anaesthesia while spontaneous respiratory effort was maintained. However, tracheostomy was reserved as a resort to accomplish ventilation in plan B, if the team would have landed in “inability to intubate or ventilate” like situation during surgical procedure.

The denture was then removed by direct laryngoscopy (using Chevalior Jackson laryngoscope). Standing on the cephalad end of the patient, though the wire on right side was more approachable, the deeper lodged wire on left side was caught hold and the denture rotated in situ by about 30 degrees. It was then dragged out with slow, sustained but controlled force. This was done in the way as explained above because the sharp end of wire on left side was in the direction of the drag which would have torn the whole lateral pharyngeal wall where the vital neurovascular structures lies.

The retrieved denture with wire was of size 7.3 cm x 4.4 cm x 2 cm (Fig 4). The only injury suffered by patient during the operative procedure was loss of two loose tooth and small laceration on right anterior pillar (Fig 5). The patient recovered well and was discharged on 3rd post-operative day after advice of Dental surgeon.

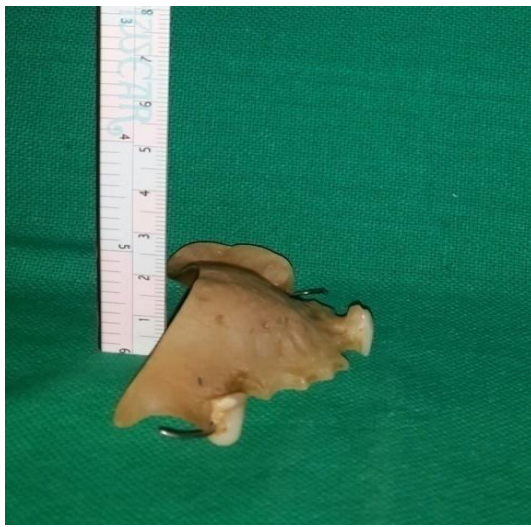
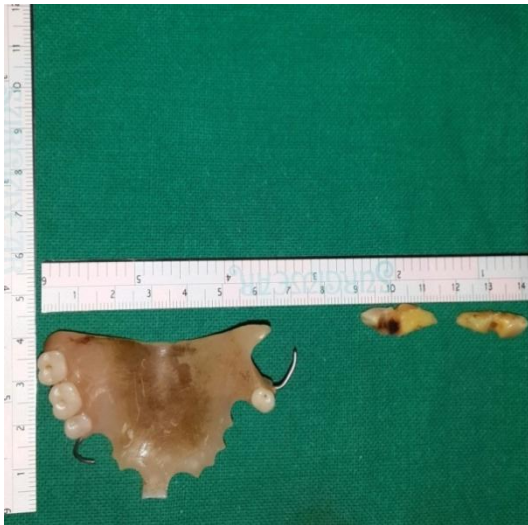
Figure 4: Retrieved denture with wires (size 7.3 cm x 4.4 cm x 2 cm) and removed two loose tooth.

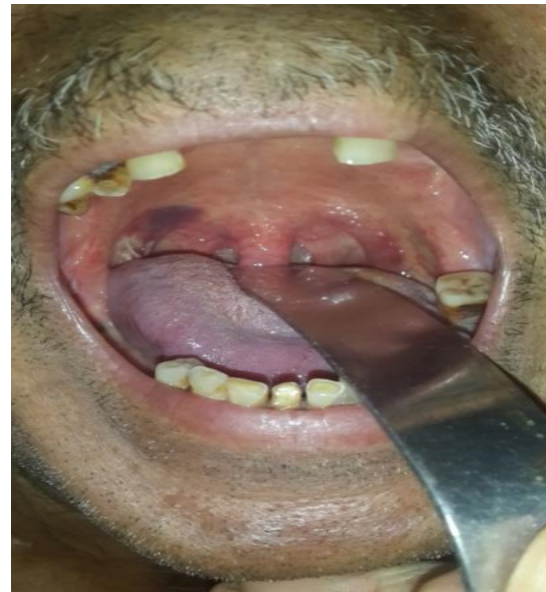

Figure 5: Healed laceration of right anterior pillar.

DISCUSSION:

Dentures are one of the most notorious foreign bodies as they have sharp serrated edges and sometimes wires too, which can damage the mucosa. Nwaogru reported majority of dentures (63.6%) to be impacted in upper esophagus, while 31.8% in upper thorax and 4.5% in lower esophagus.^[3]

Diagnosis of displaced dentures is usually apparent by clinical presentation and history. Other features include excessive salivation, pain or difficulty in swallowing, voice change or difficulty in breathing. Accurate radiological localization may be difficult as most of the dentures are radiolucent.

If the foreign bodies are not removed at the earliest, they can cause esophageal perforation, erosion, abscess, mediastinitis, esophagoaortic fistula, empyema thoracis and lung abscess.^[4]

In case of esophageal foreign bodies, rigid esophagoscopy is the technique commonly used to extract foreign body, with a success rate of 80%.^[5] The wide lumen of rigid esophagoscope gives a direct and better view of foreign body and minimizes esophageal injury. It

allows multiple-instrumentation and provides more controlled situation for manipulating sharp irregular foreign bodies which can be partially drawn inside lumen of the scope.

Rigid esophagoscopy itself has its own complications. When attempts were made to remove impacted dentures in less-than-ideal situations, endoscopic extraction showed a risk of esophageal perforation (23%).^[6, 7] However, perforated and penetrated foreign bodies require surgical removal and patients need to be counseled pre-operatively.

Studies have shown that endoscopic removal of sharp-edged foreign bodies is possible using a number of different techniques without need of major surgery.^[8, 9, 10]

In our first case, use of adrenaline soaked cotton patties to disimpact the denture proved to be a good method. This can be routinely practiced for improving the forceps space.

As experts in their separate areas, mutually respected collaboration between otorhinolaryngologist and anaesthesiologist helps in prompt decision making intra-operatively. Our second case is a good example of this.

Patients should be educated on the importance of adherence to instructions/precautions for safe use of denture, their life span, and maintenance; recall visits for assessing proper fitness of dentures.

CONCLUSION:

Early extraction of dentures by endoscopy should be done after carefully assessing the risk-benefit ratio and the care should be taken in every sense by making judicious use of surgical intervention and other safe techniques. Proper fabrication of the denture in regards to its fitting and adequate post delivery instructions are necessary to prevent complications.

REFERENCES

1. Abdullah BJ, Teong LK, Mahadevan J, Jalaluddin A. Dental prosthesis ingested and impacted in the esophagus and orolaryngopharynx. *J Otolaryngol* 1998;27:190-194.
2. Hashmi S, Walter J, Smith W, Latis S. Swallowed partial dentures. *J R Soc Med* 2004; 97:72-75.
3. Nwaogru OG, Onakoya PA, Sogebi OA, et al. Esophageal impacted dentures. *J Natl Med Assoc* 2004;96:1350-1353.
4. Adhikari P, Shrestha BL, Baskota DK. Accidental Foreign body Ingestion: Analysis of 163 cases. *Archive of Otorhinolaryngology* 2007;11:438-439.
5. Han S, Kayhan B, Dural K. A New and safe technique for removing cervical esophageal foreign body. *Turk J Gastroenterol* 2005; 16: 108-110.
6. Okoisor FE. Tooth mortality: a clinical study of loss. *Niger Med J* 1977;7:77-81
7. Okeowo PA. Foreign bodies in pharynx and esophagus- a 10 year review of patients seen in Lagos, Niger. *Q J Hosp Med* 1985;3:46-50.
8. Jeen YT, Chun HJ, Song CW, et al. Endoscopic removal of sharp foreign bodies impacted in the esophagus. *Endoscopy* 2001;33:518-522
9. Nijhawan S, Shimpi L, Mathur A, et al. Management of ingested foreign bodies in upper gastrointestinal tract: report on 170 patients. *Indian J Gastroenterol* 2003; 22:46-48.
10. Fang R, Sun J, Hu Y. Endoscopic removal of esophageal impacted dentures. *Annals of Otolaryngology, Rhinology & Laryngology* 2010; 119:249-251.